

CHOLANGIOSCOPY

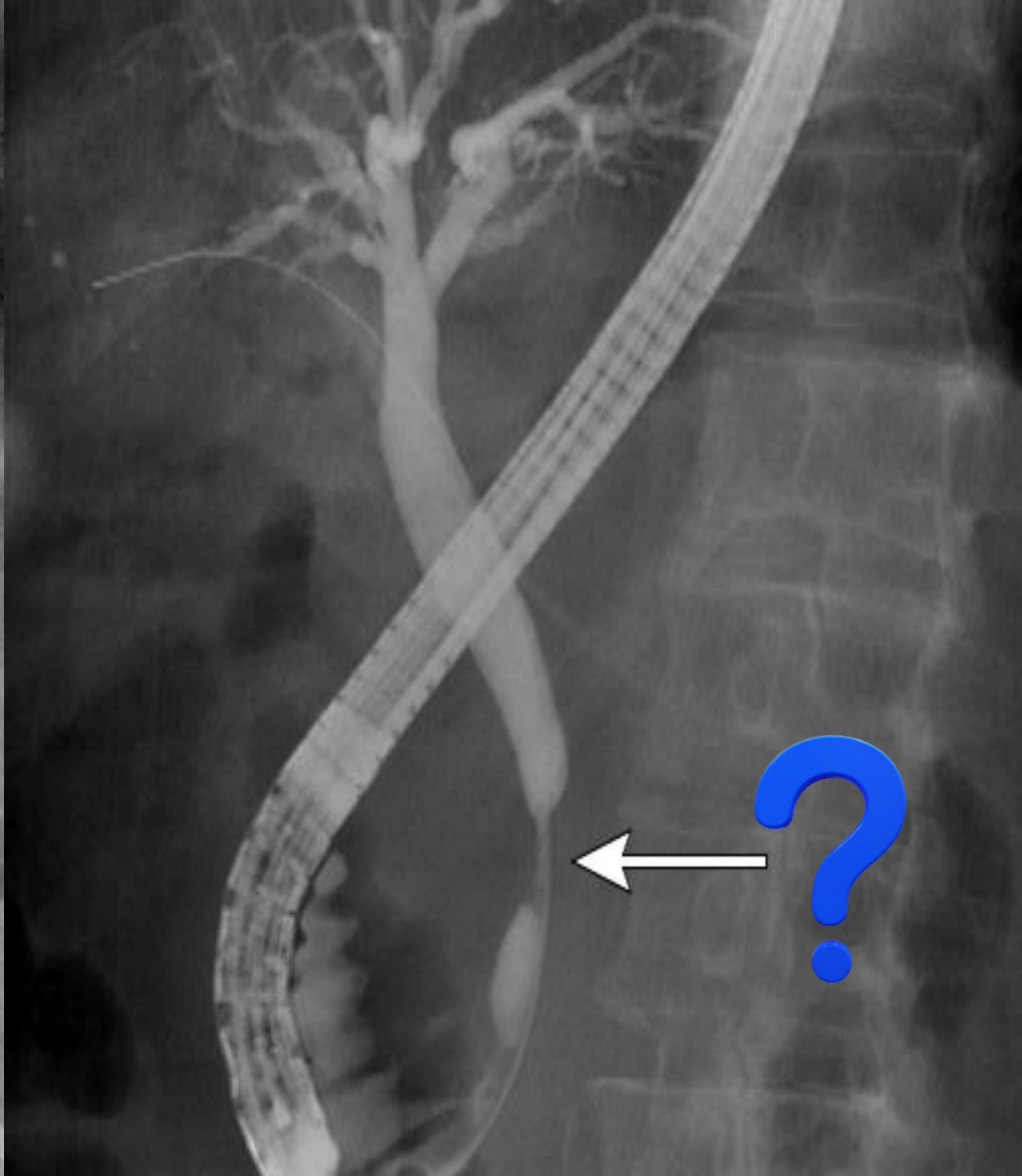
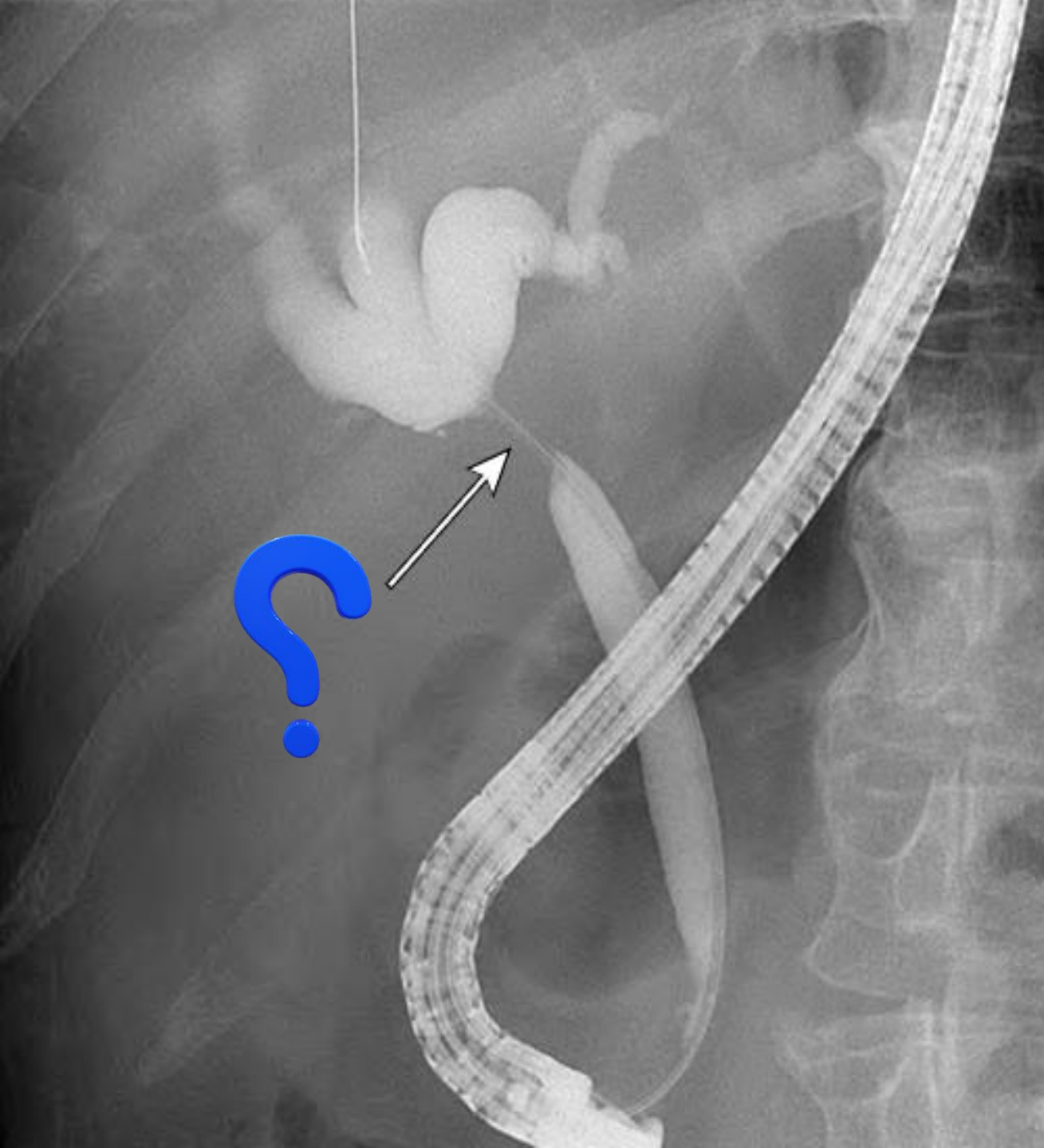NEVER BLIND AGAIN

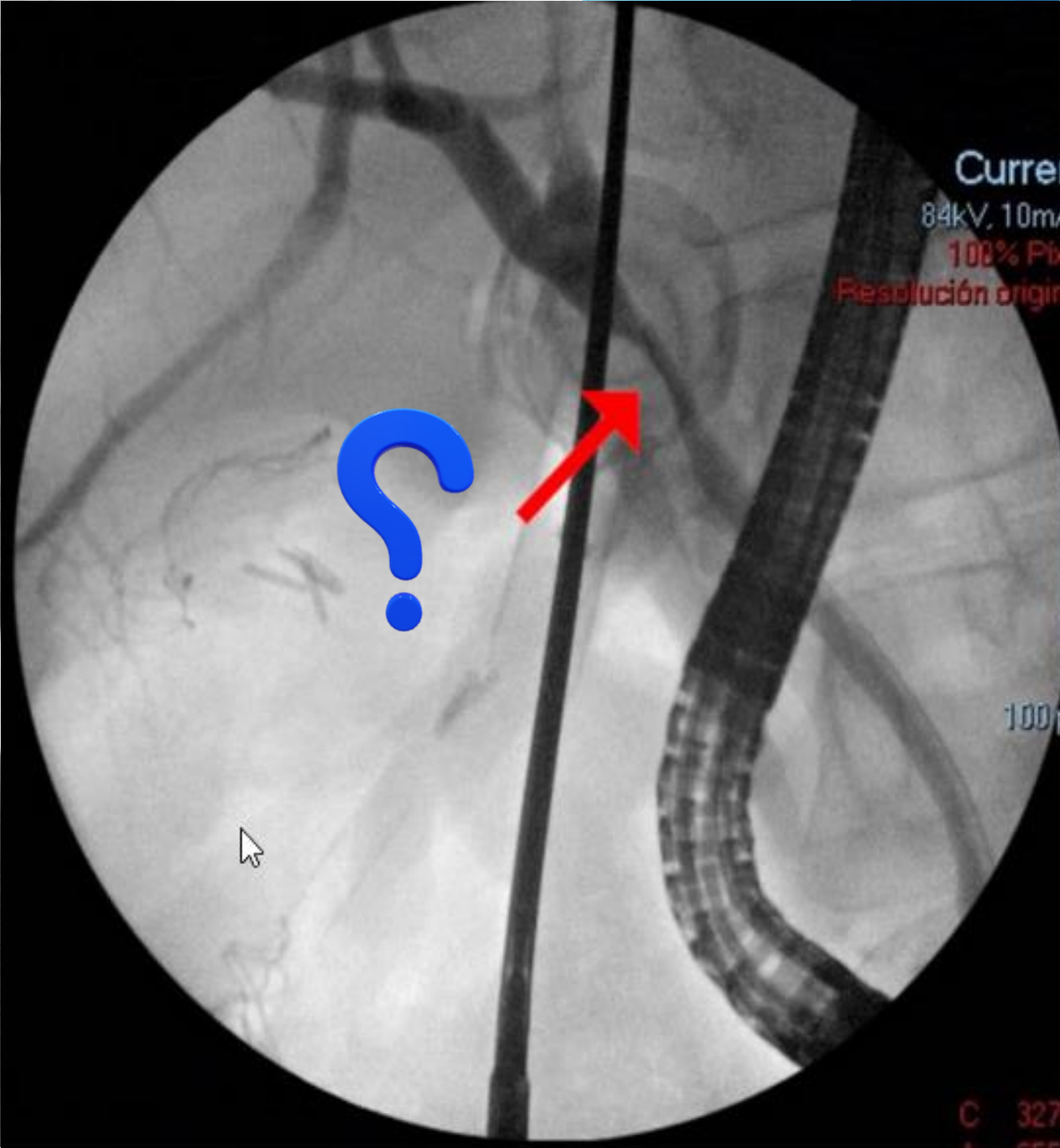
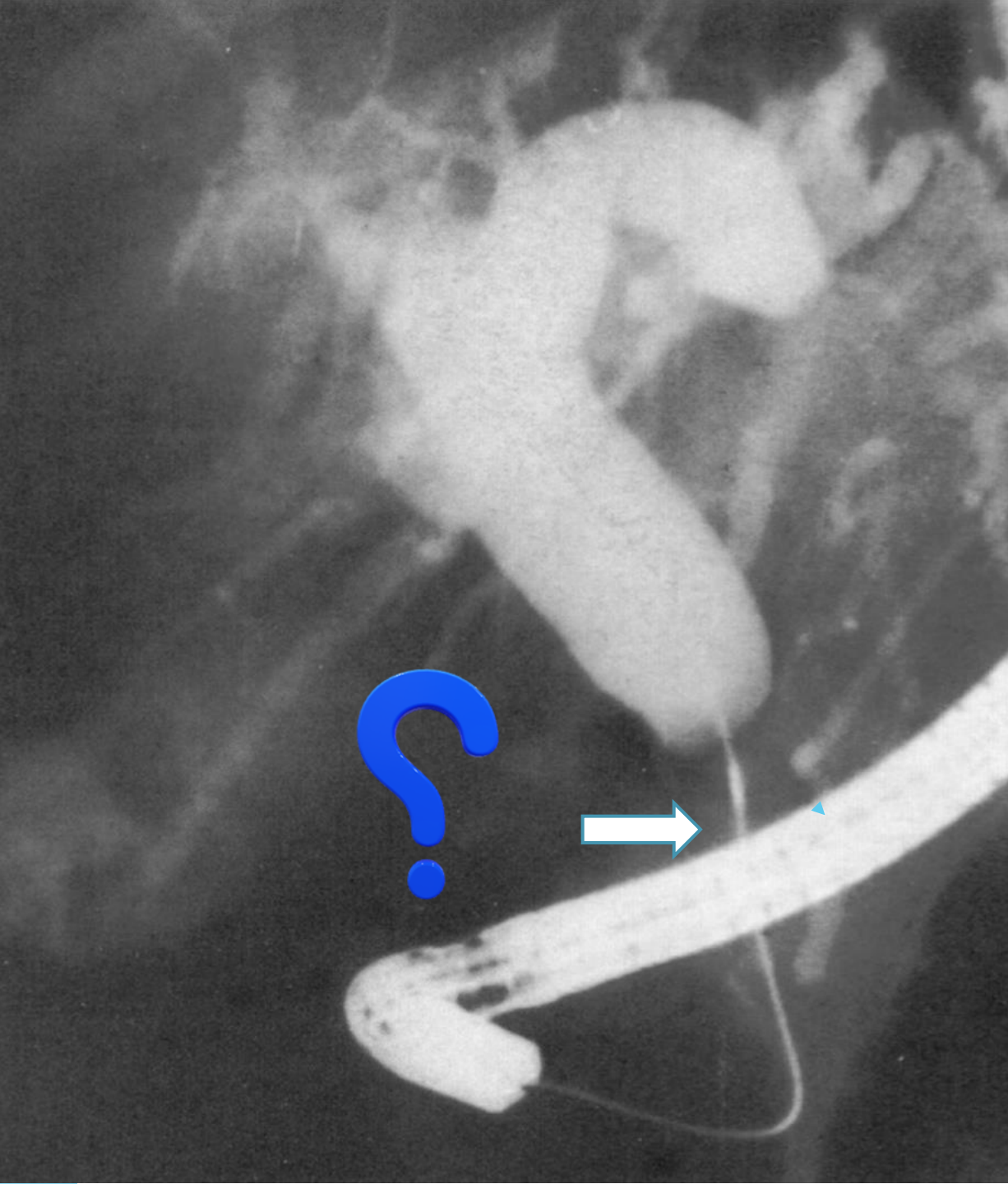
By Dr. Mazen Battah

***Chief of Damascus Hospital
Gastroenterology Dep.***

Stenosis In Biliary Tree ?

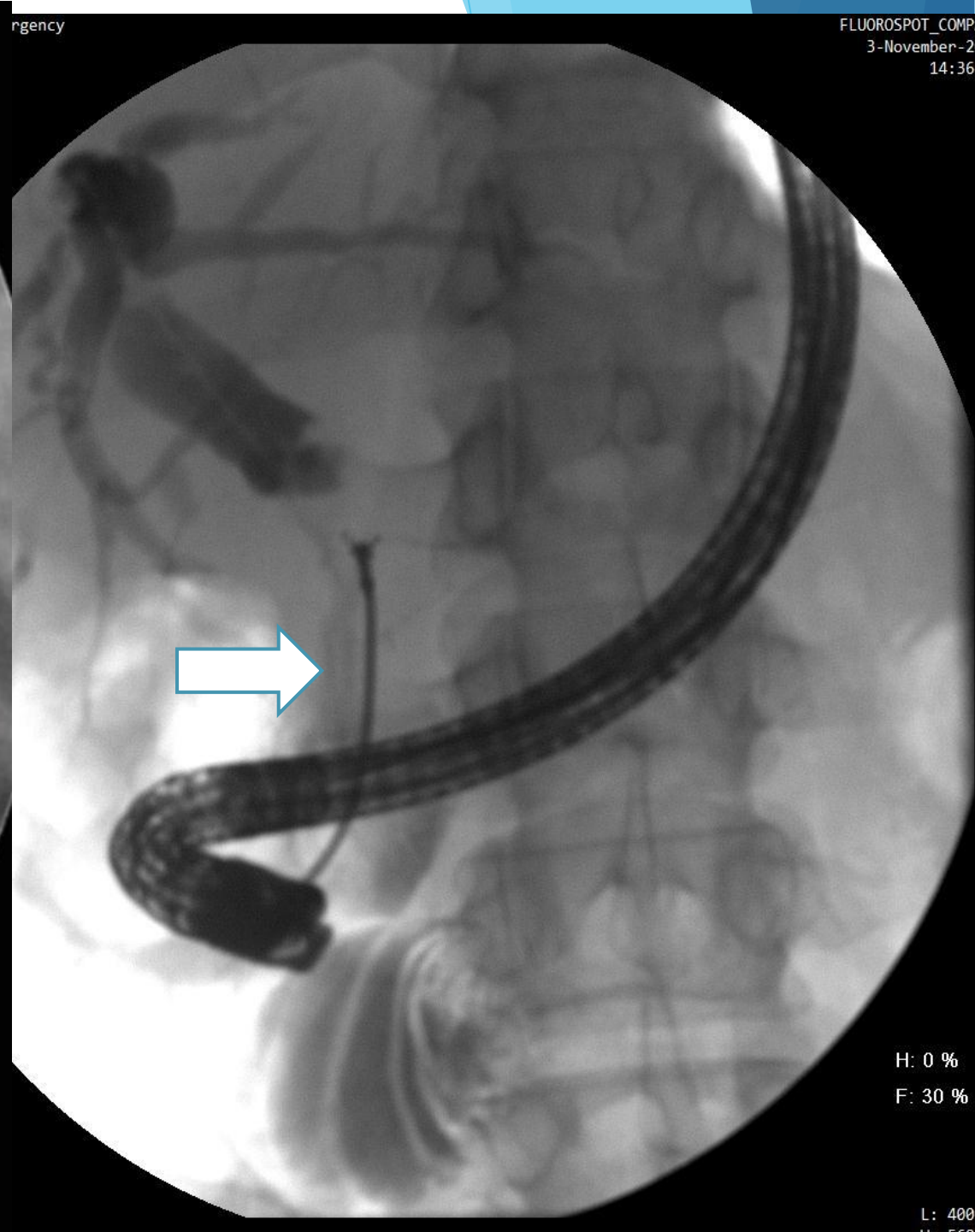
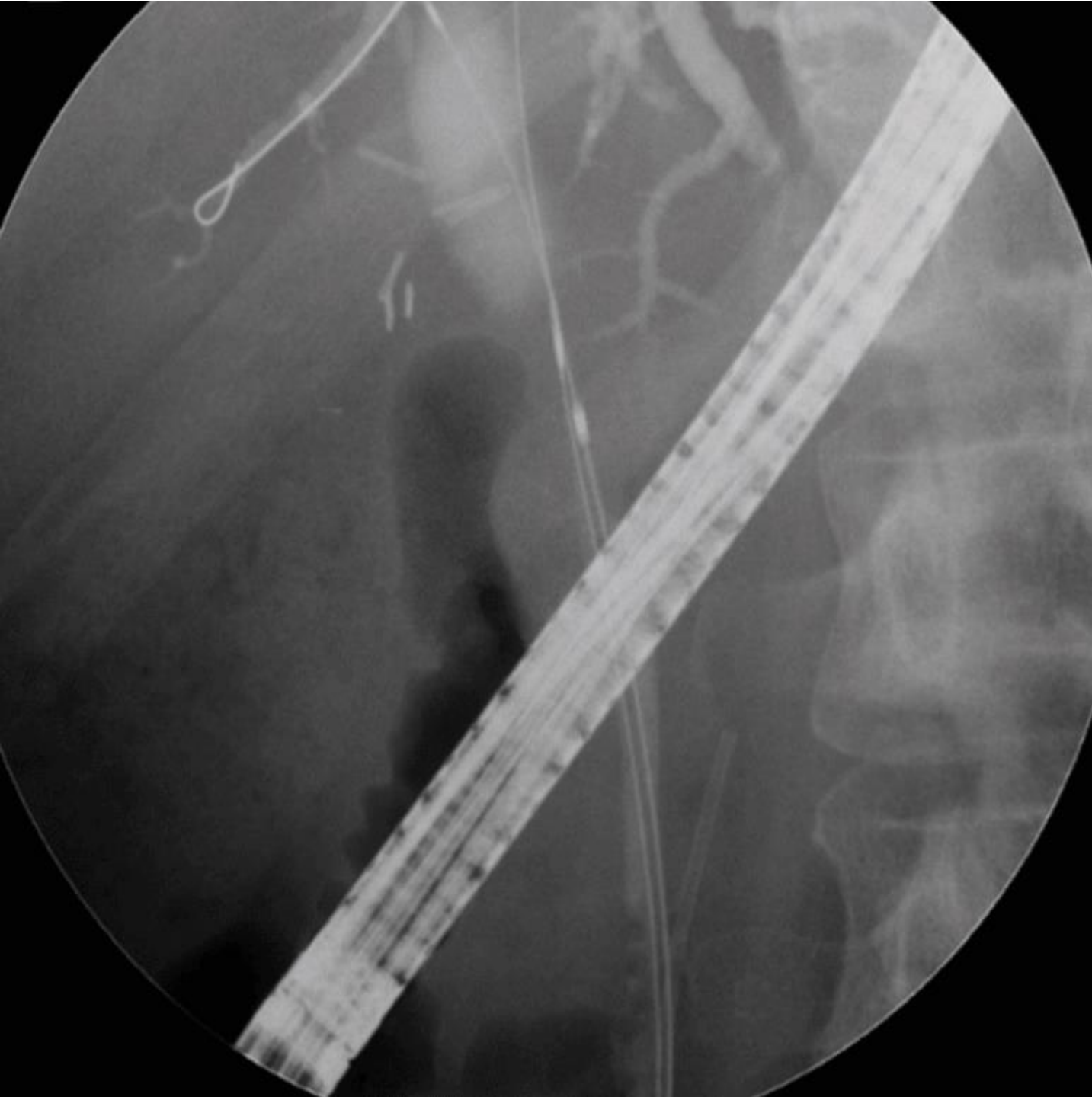▶ *By CHOLANGIOSCOPY Never Blind again.*





Traditional Technique

- ▶ *Biopsy.*
- ▶ *Cytology Brush.*



ngency

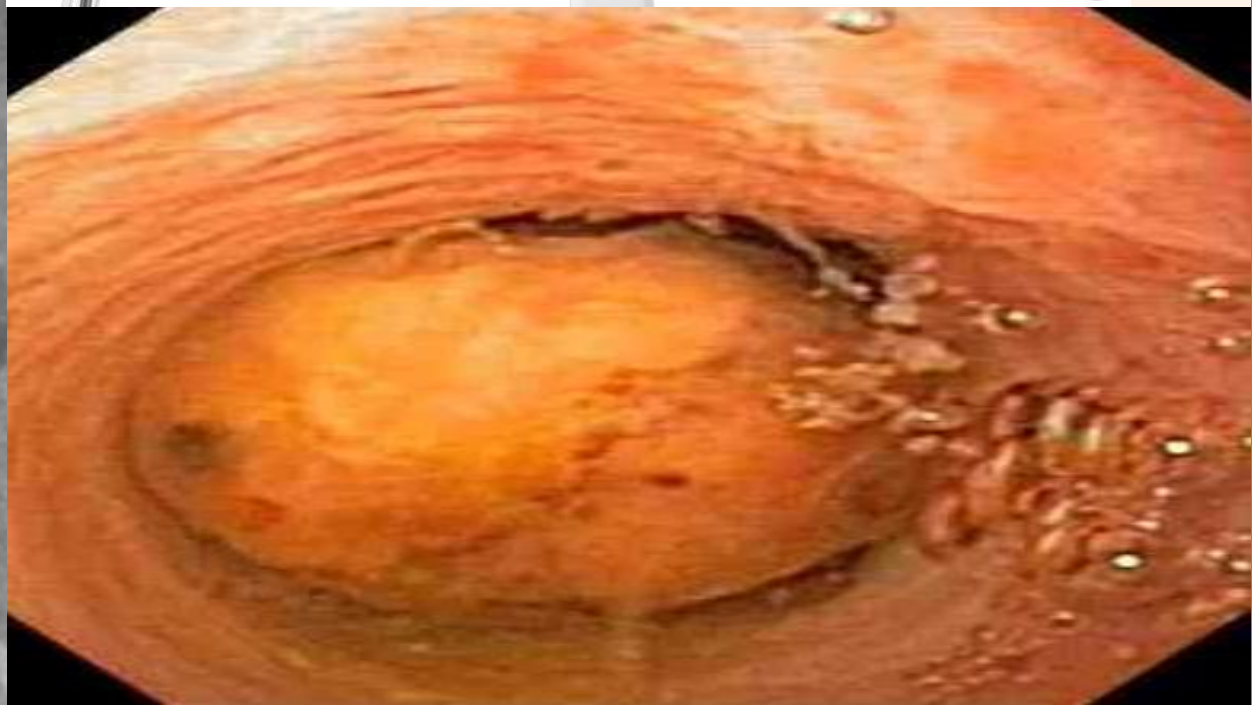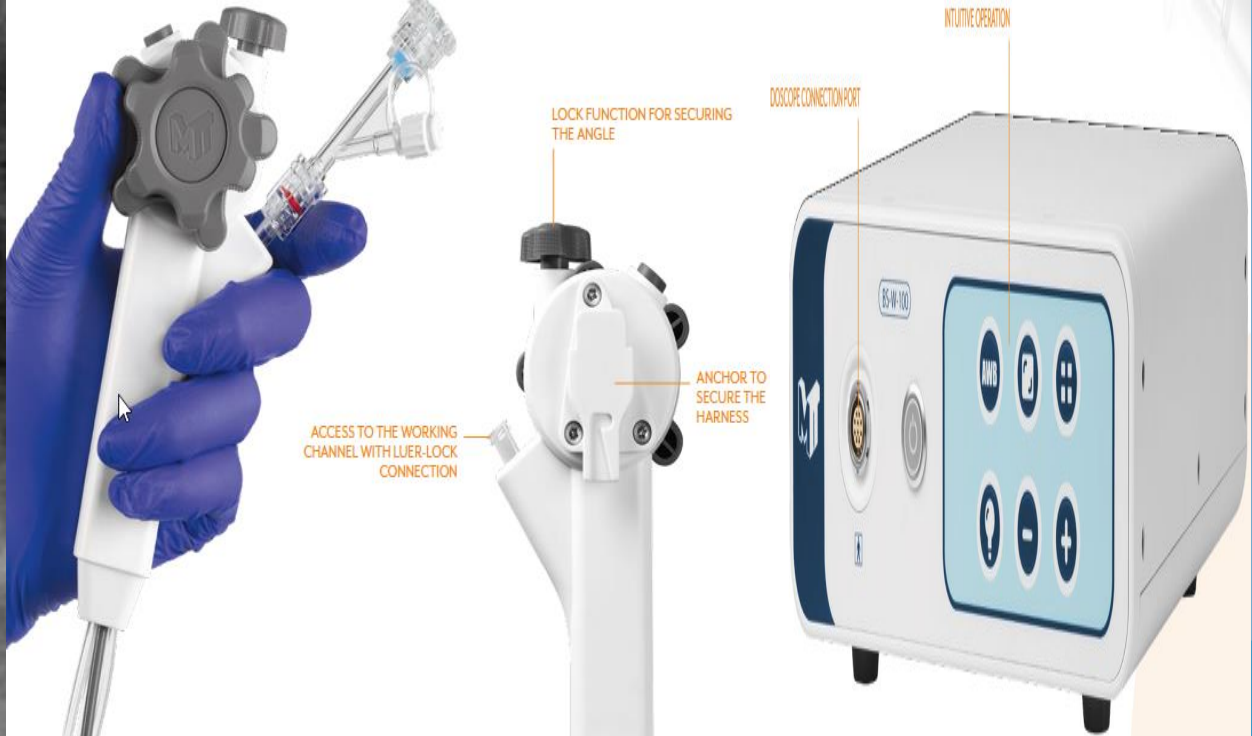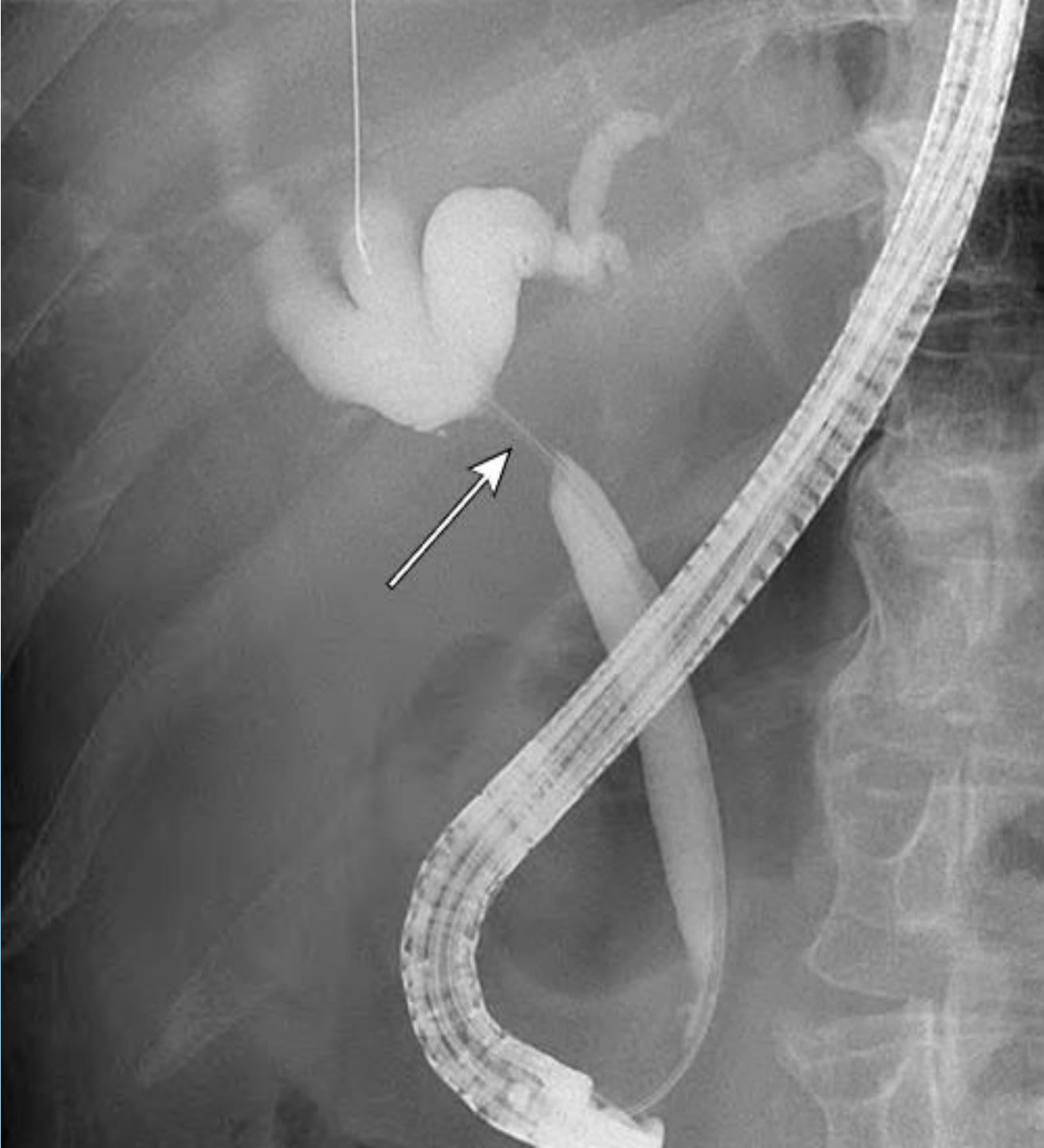FLUOROSPOT_COMP
3-November-2
14:36

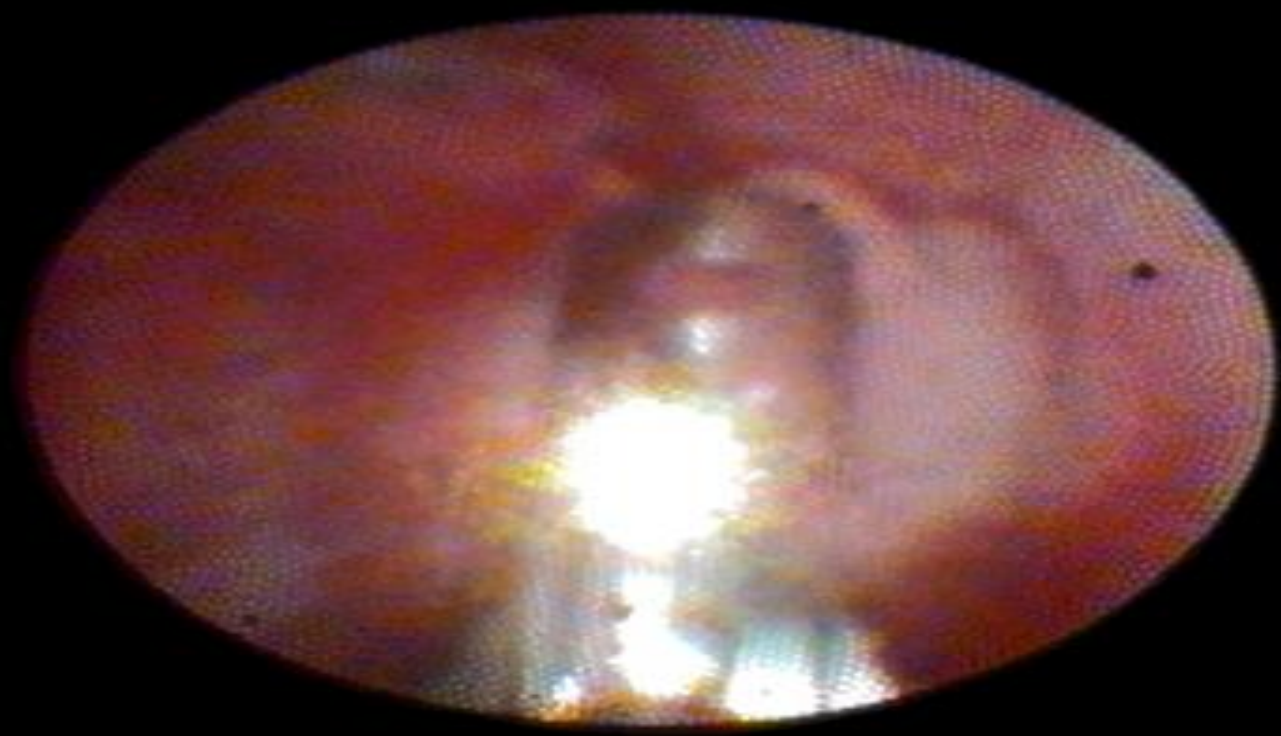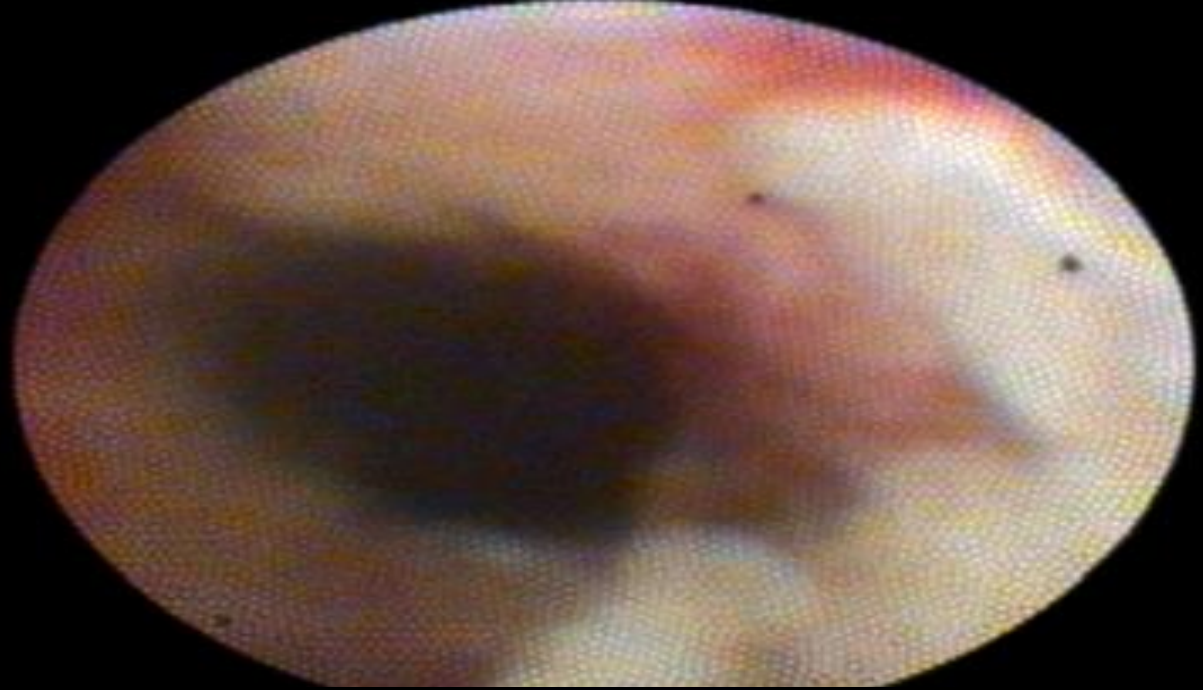
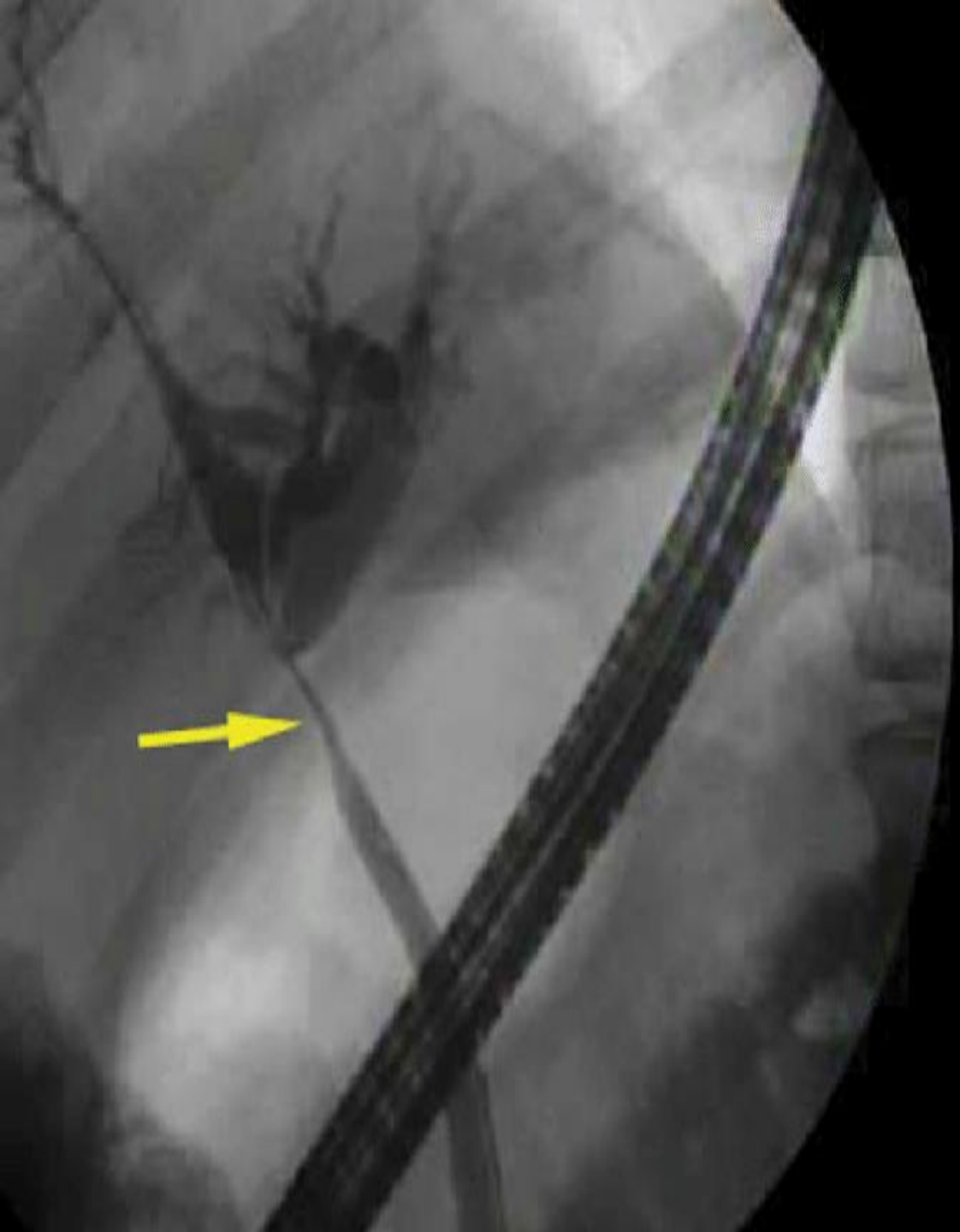
H: 0 %
F: 30 %

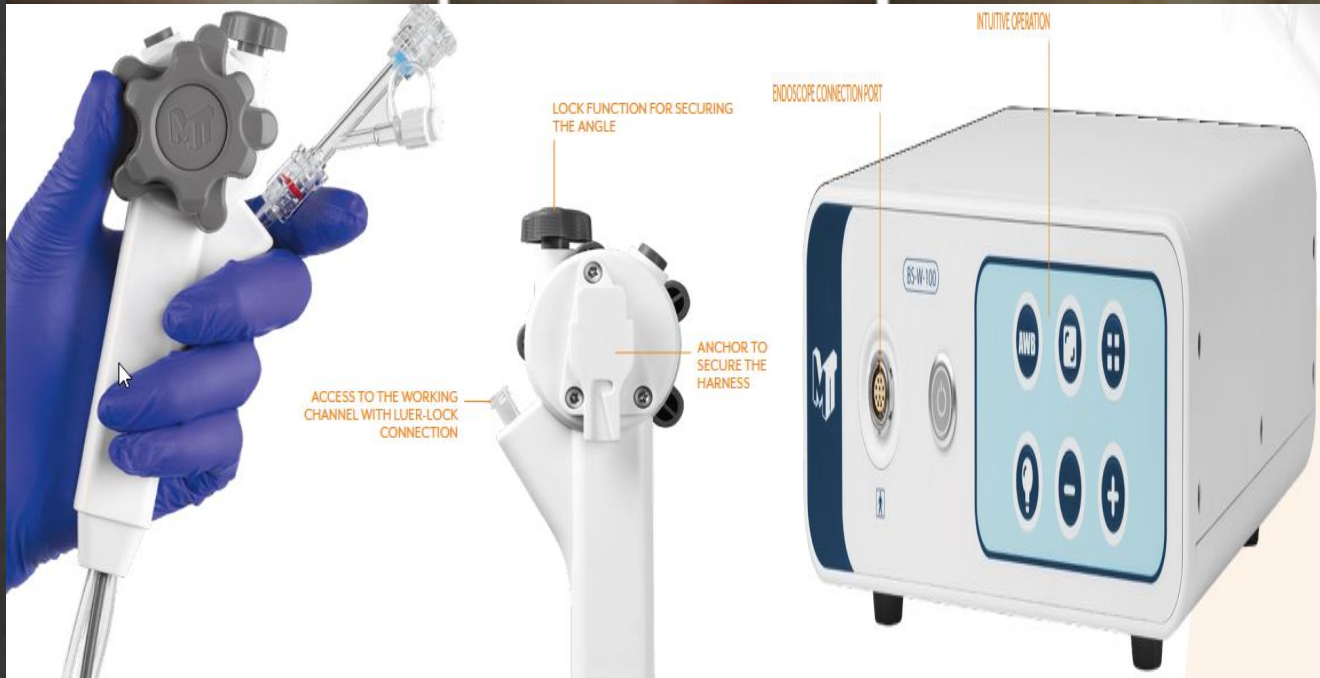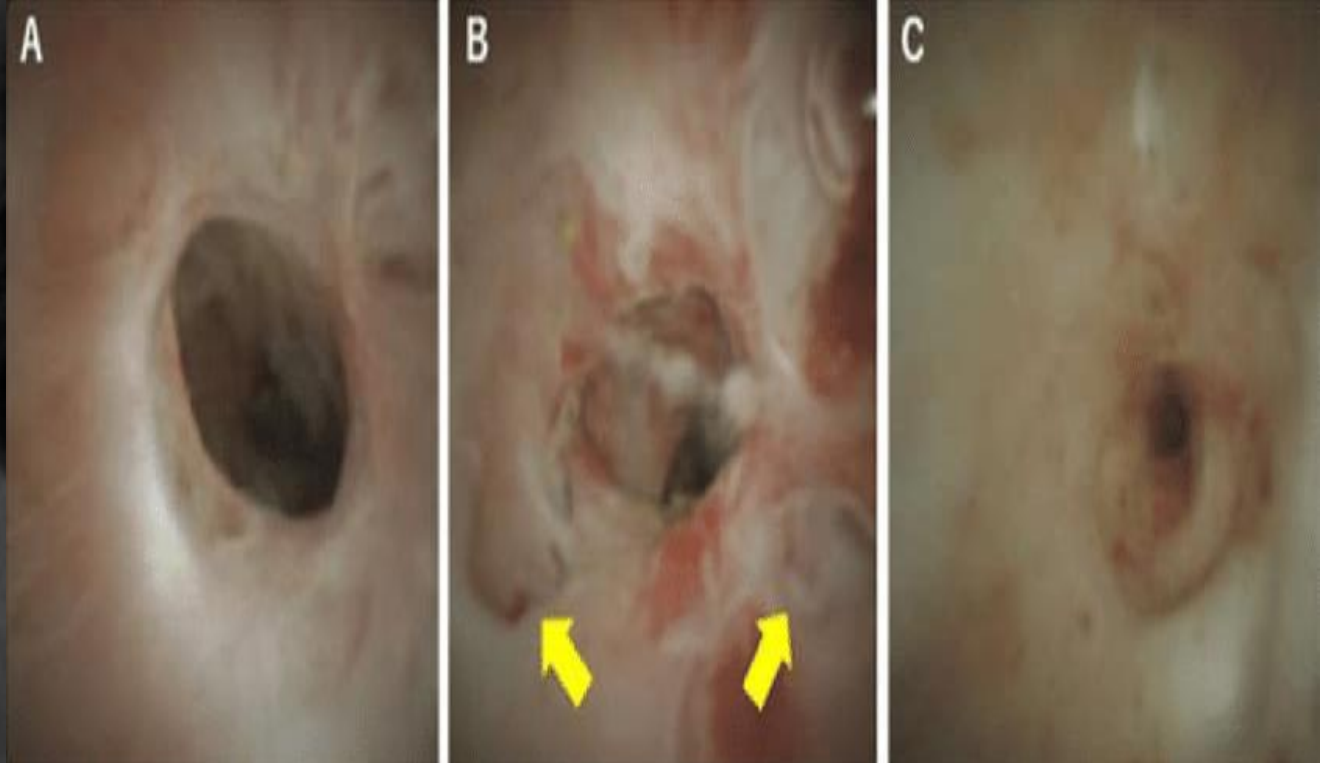
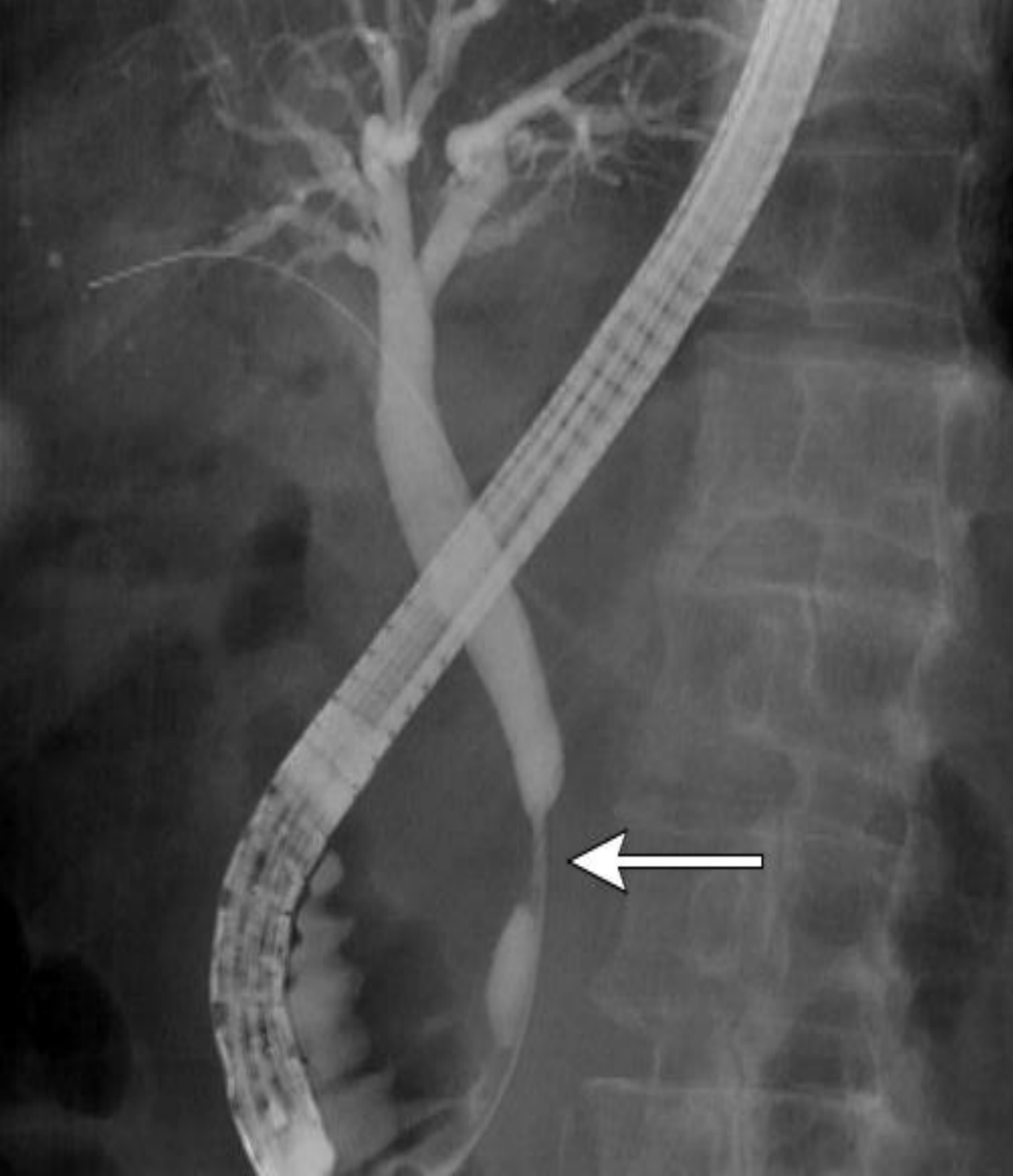
L: 400

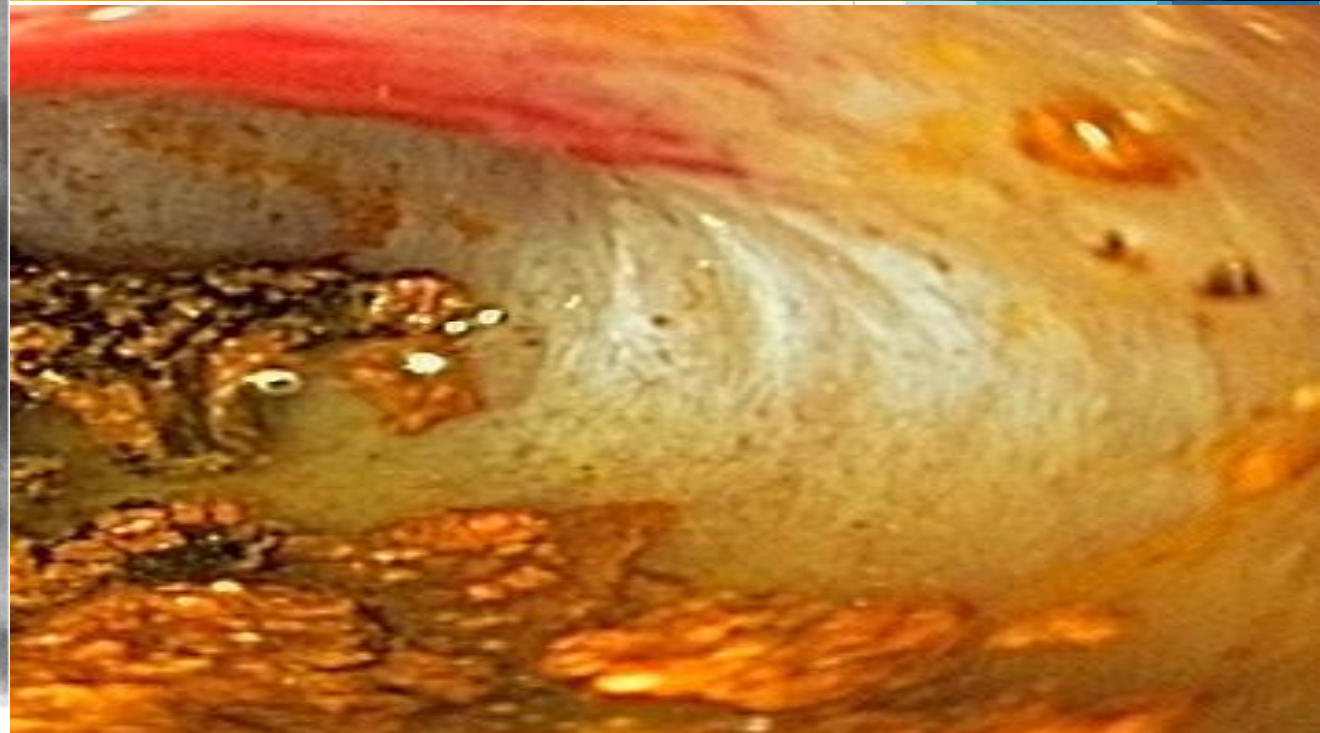
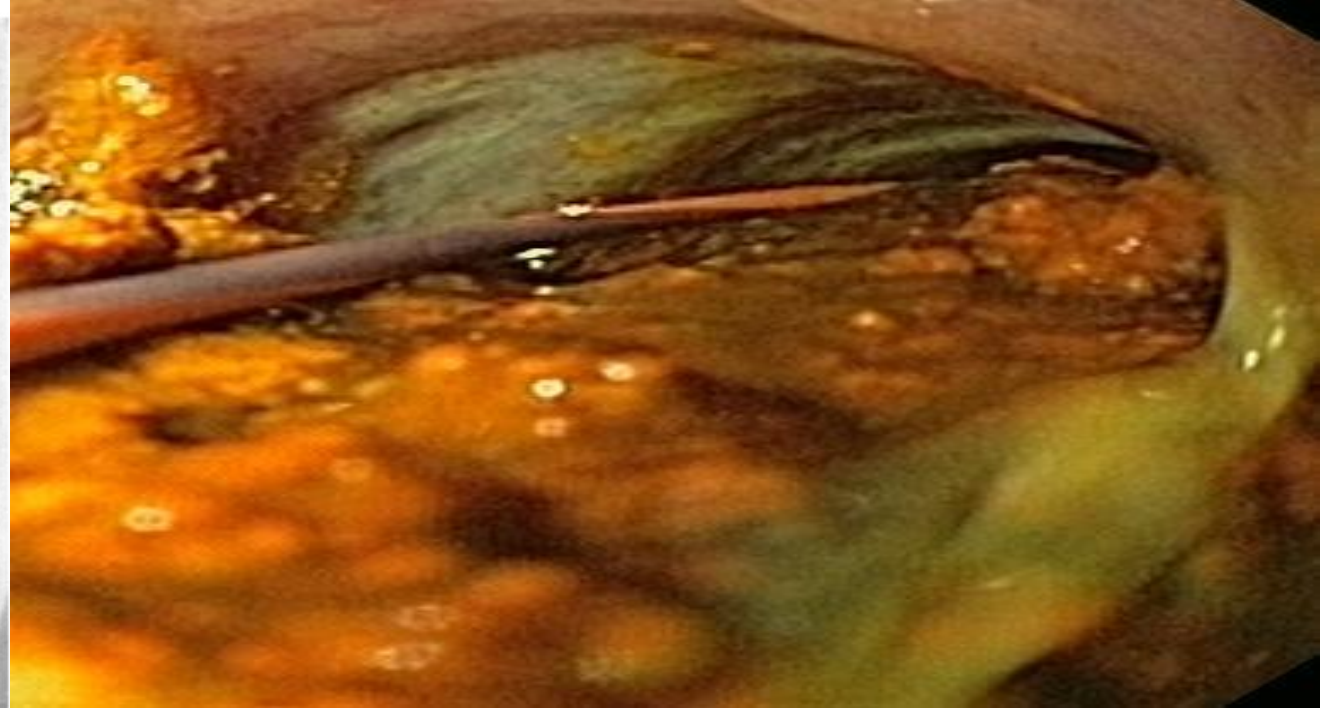
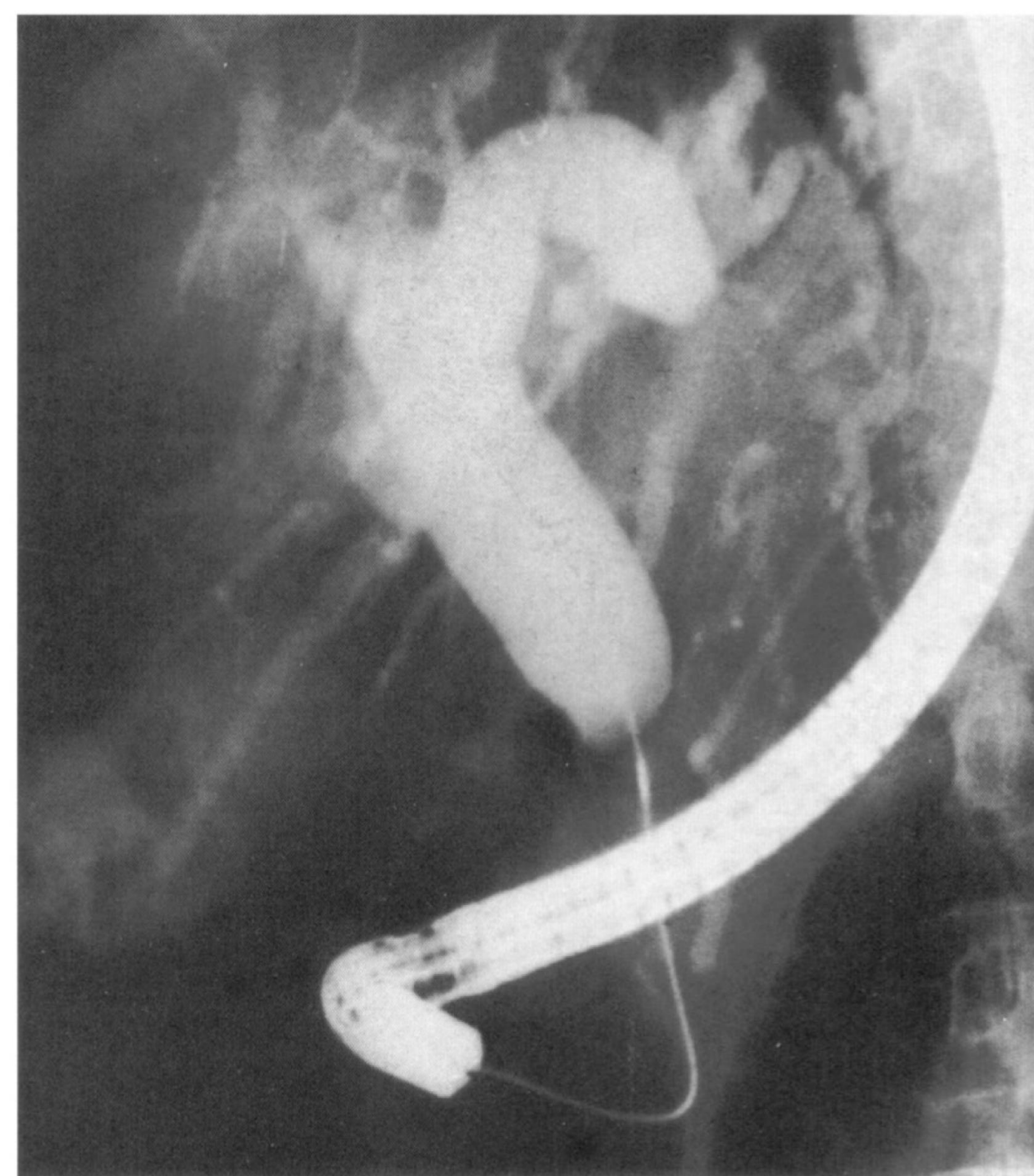
Modern Technique:

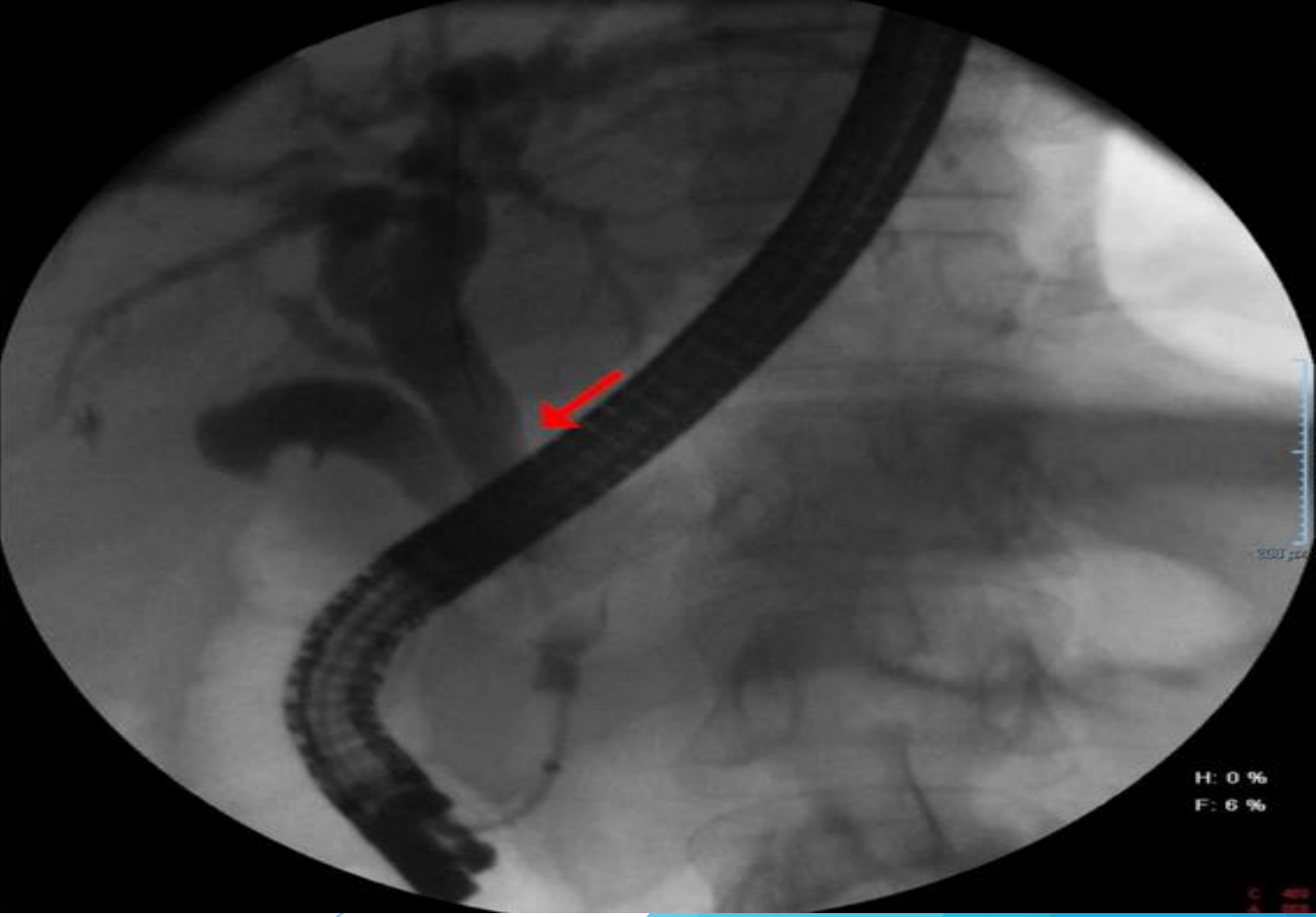
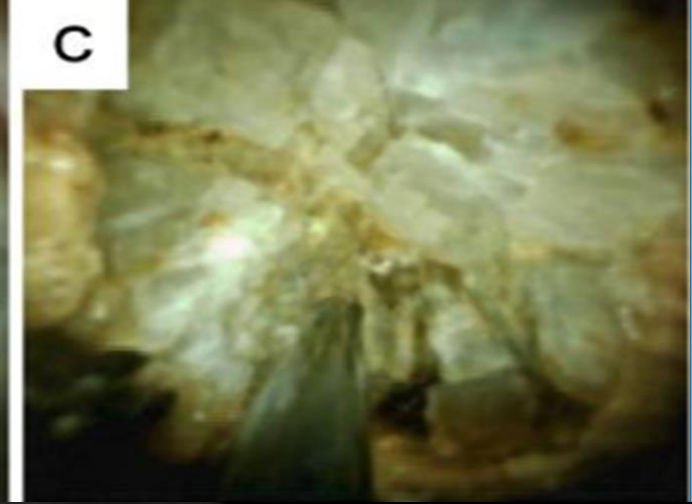
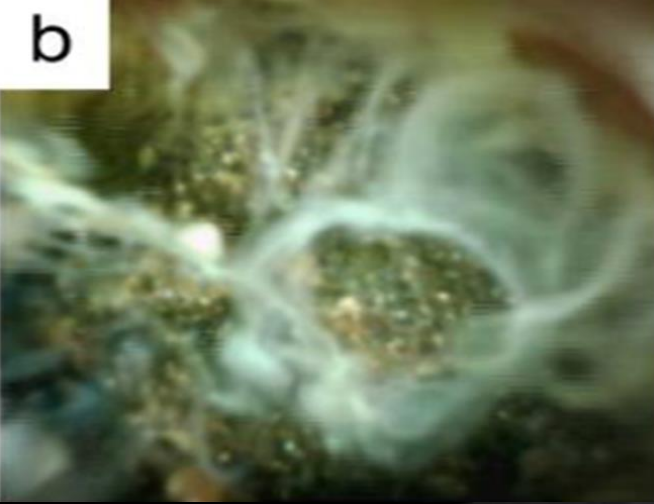
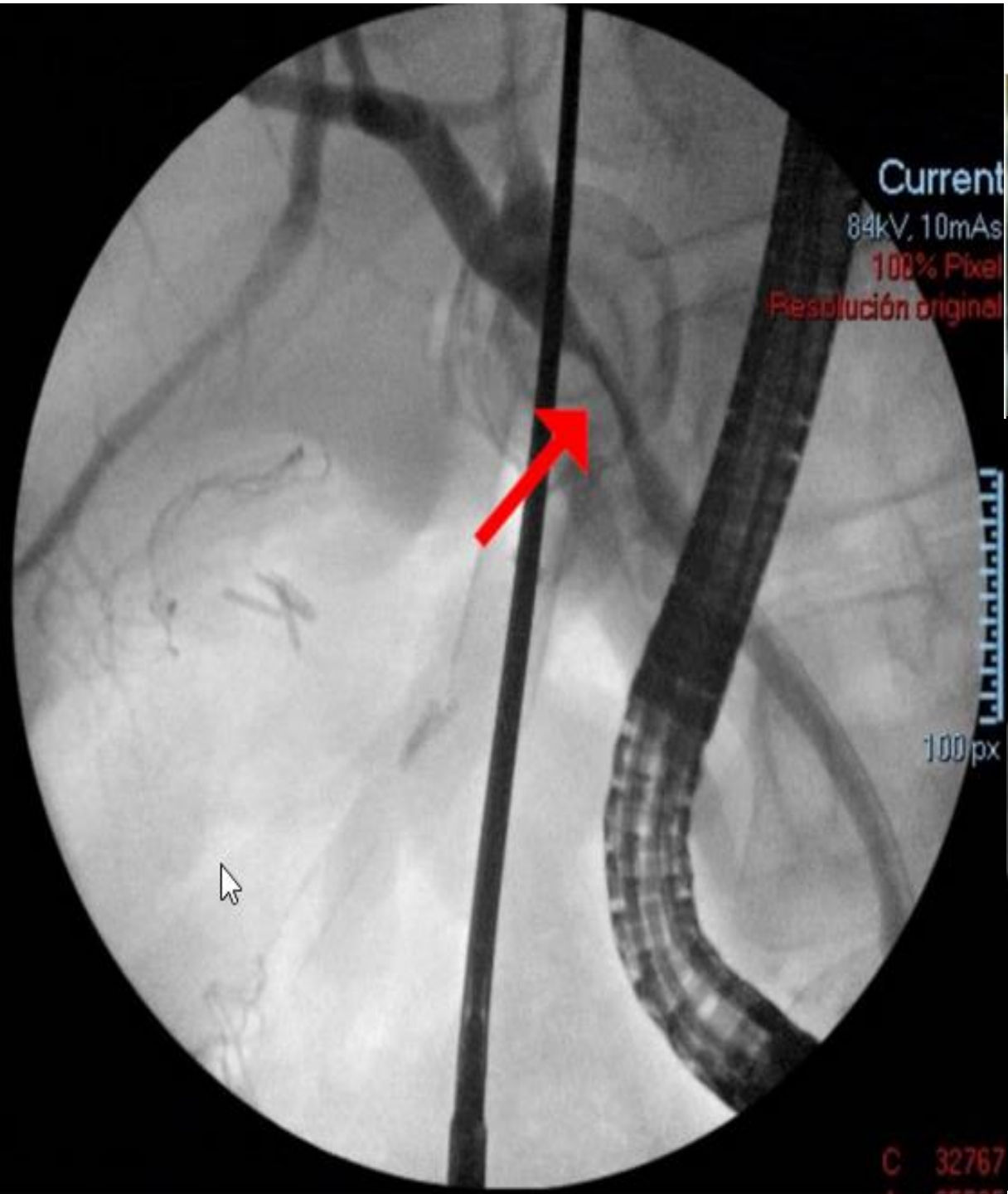▶ *Cholangioscopy.*

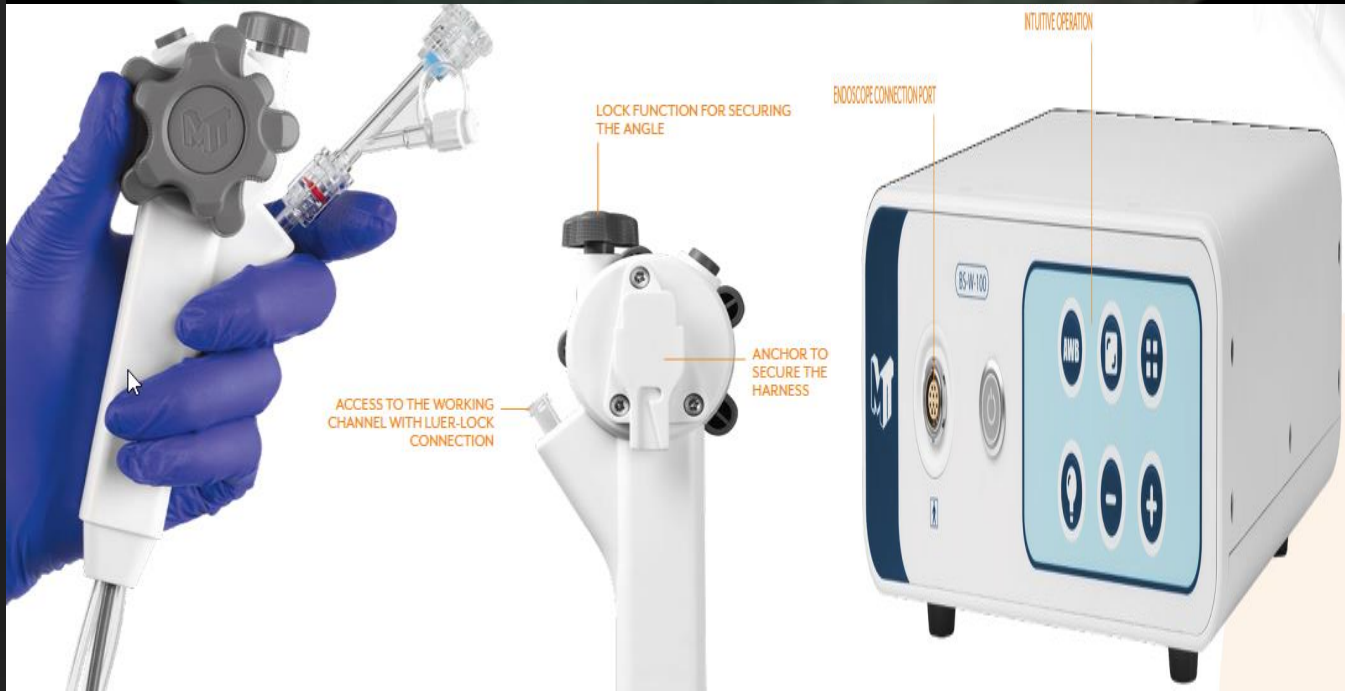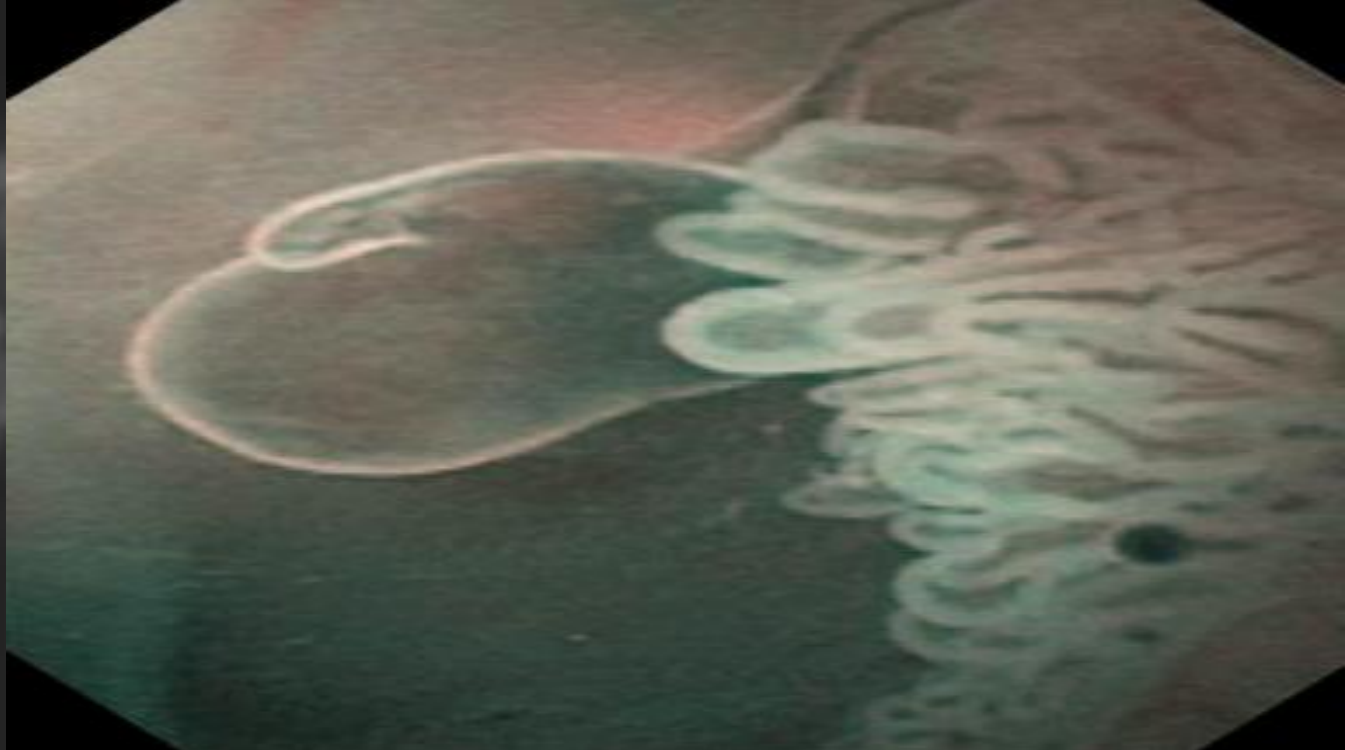

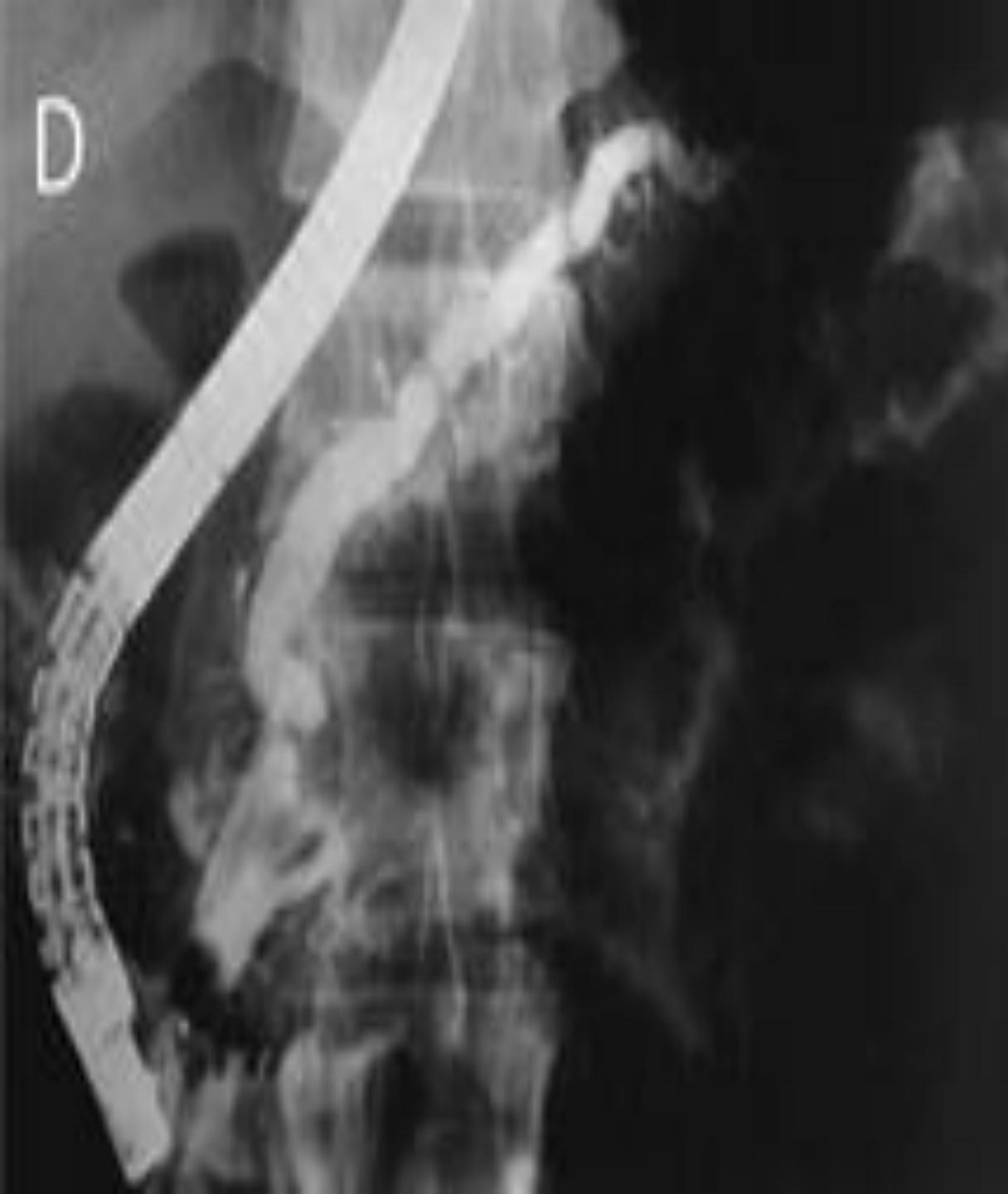
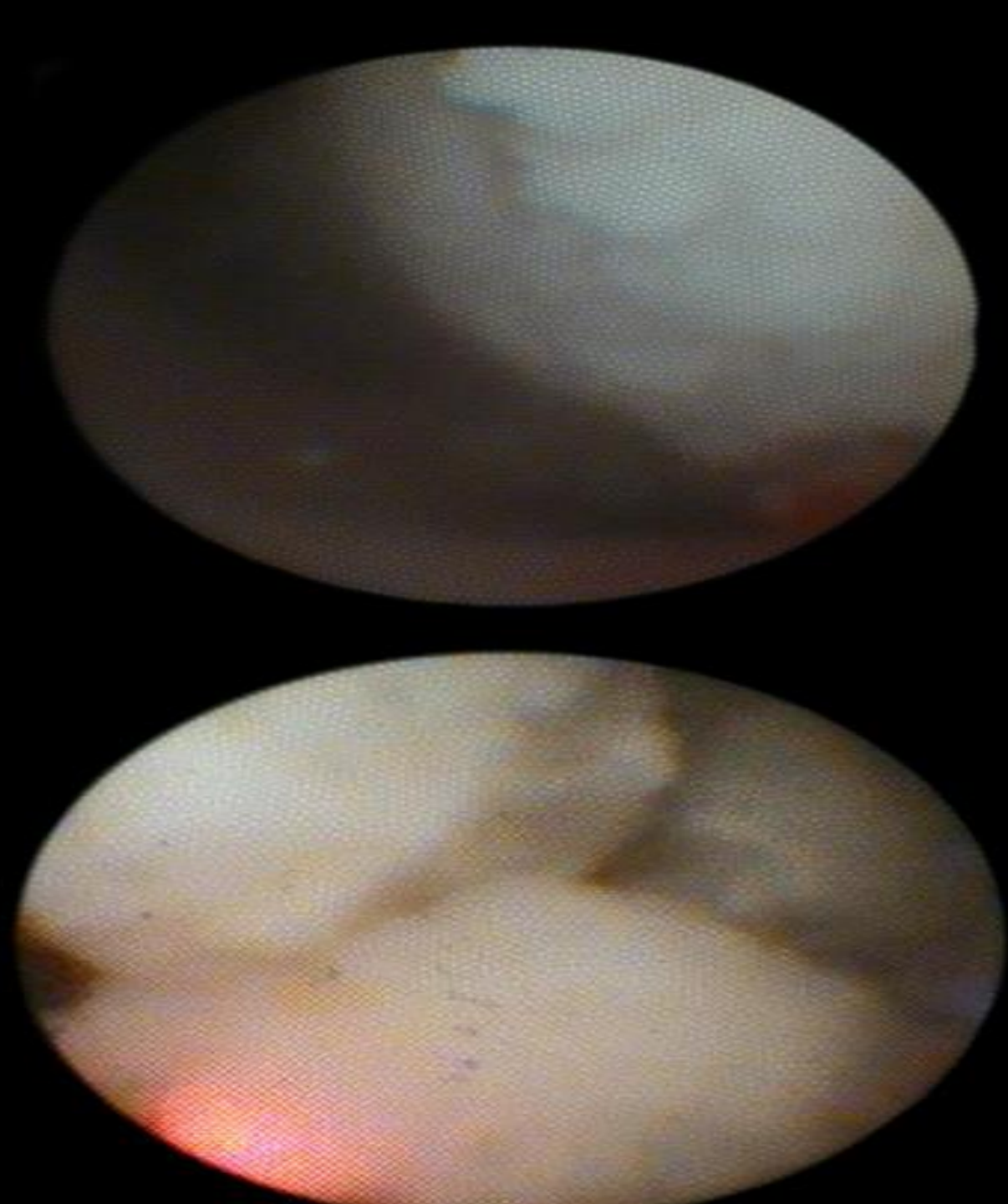
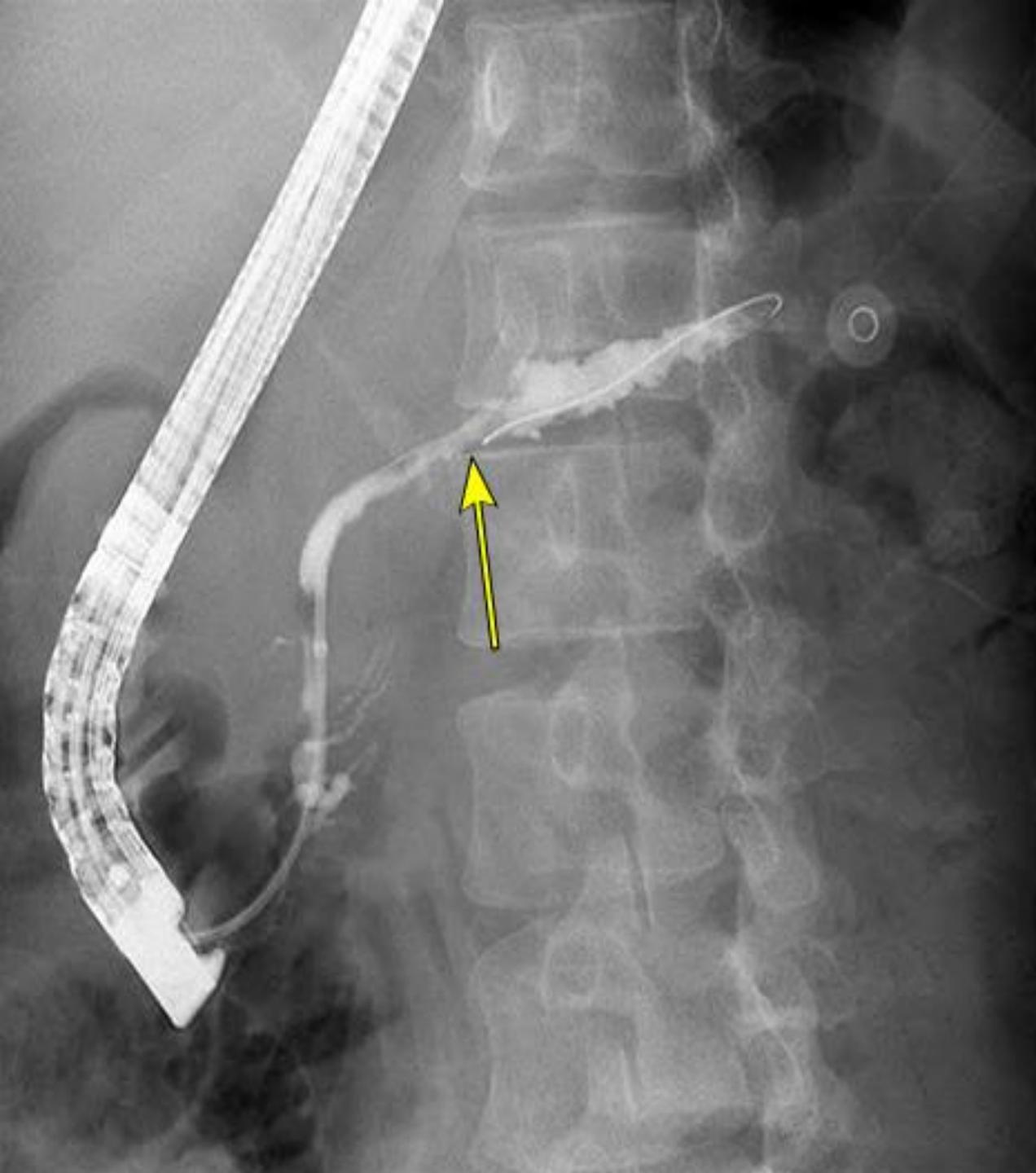


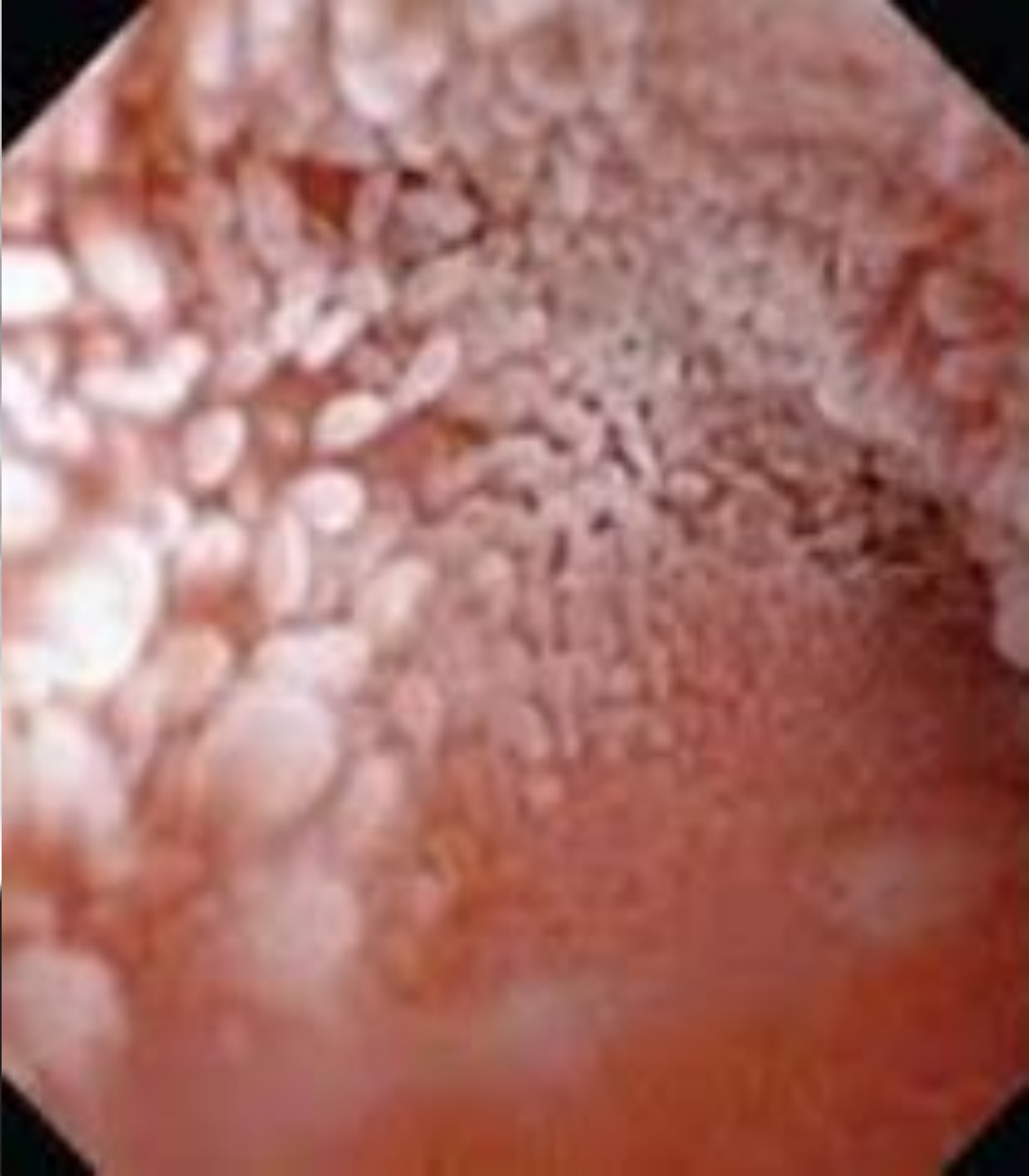


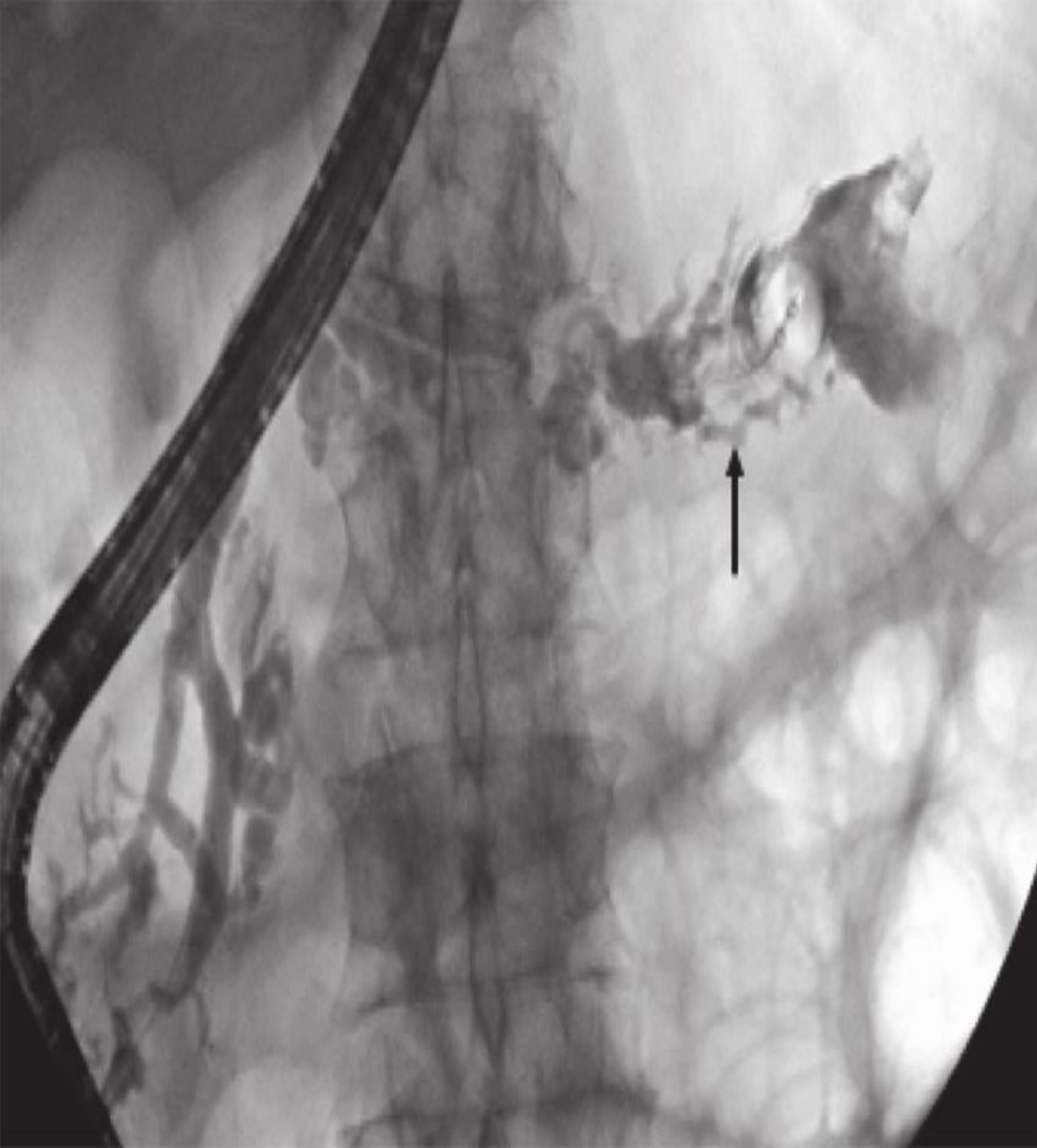









Indications

- ▶ *Determine Biliary and pancreatic Strictures(specially diagnosing malignancy).*
- ▶ *Diagnosis of filling-defects.*
- ▶ *Lithotripsy for Large or Difficult stones.*
- ▶ *Diagnosis & management of Mirizzi syndrome (Type2).*
- ▶ *Catheterization of difficult biliary ducts (ex; for Left Hepatic Duct stent placement in CCA).*
- ▶ *Endoscopic Cholecystostomy.*
- ▶ *Pancreatic stones.*
- ▶ *IPMN Diagnosis.*

HIGH-RESOLUTION
CAMERA

Available in 3.9mm and 3.2mm sizes

120° ANGLE OF VIEW

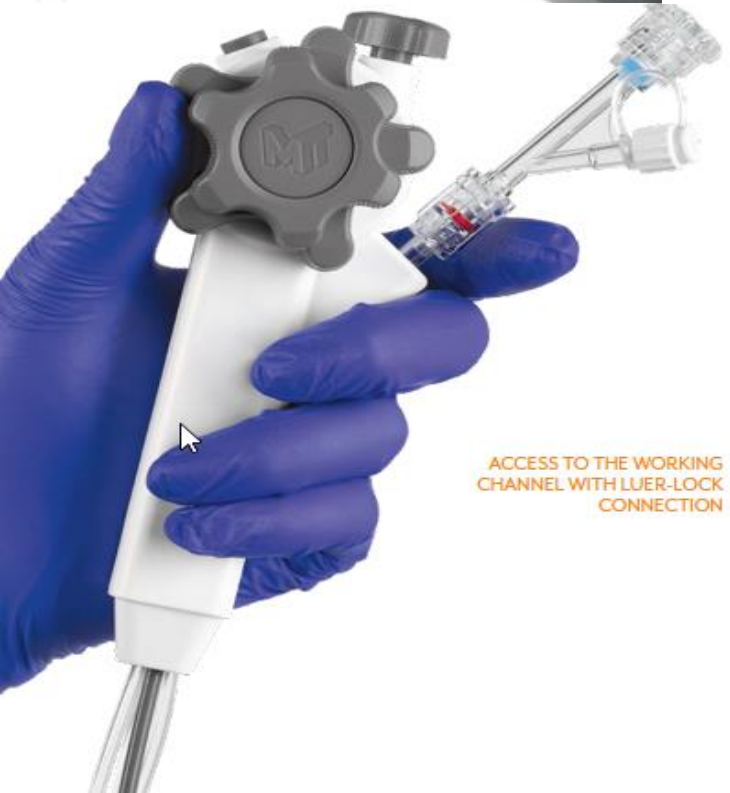LED LIGHTING

Working length
2200

4-WAY ANGULATION

IRRIGATION CHANNELS

WORKING CHANNEL
1.2 MM AND 2.0 MM



LOCK FUNCTION FOR SECURING
THE ANGLE

ENDOSCOPE CONNECTION PORT

INTUITIVE OPERATION

Image enlargement up to 3x

ACCESS TO THE WORKING
CHANNEL WITH LUER-LOCK
CONNECTION




ANCHOR TO
SECURE THE
HARNESS

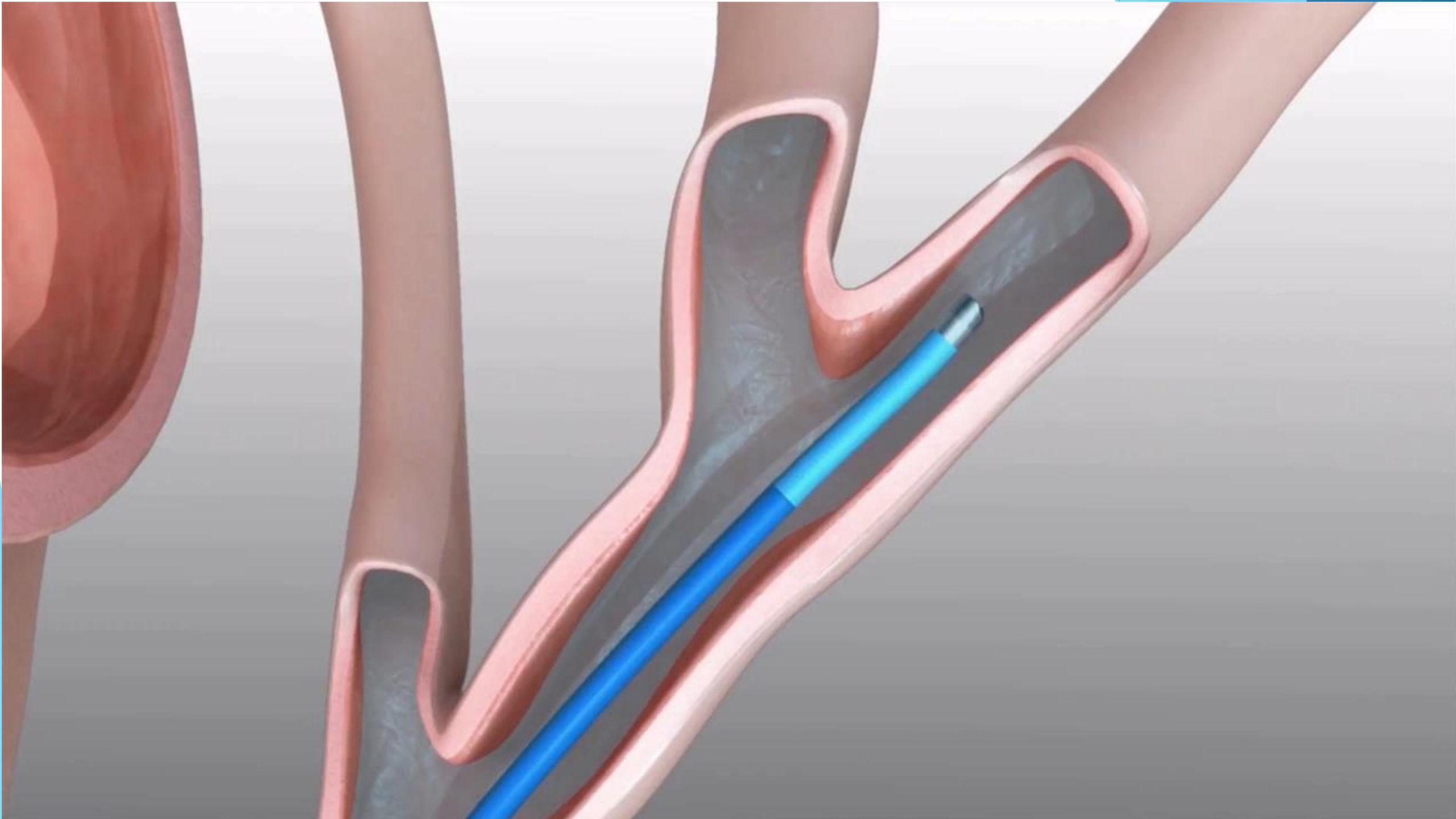


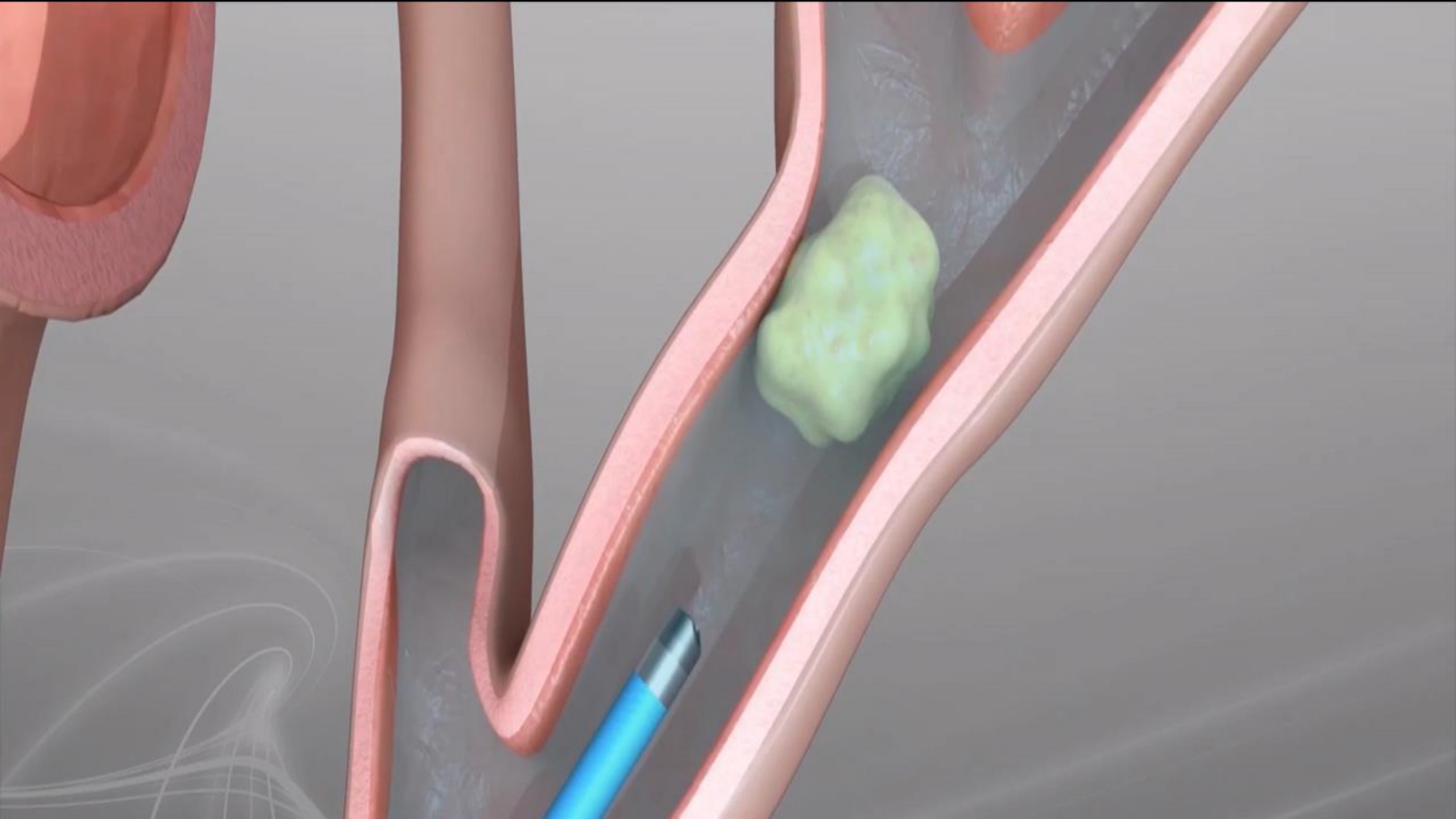


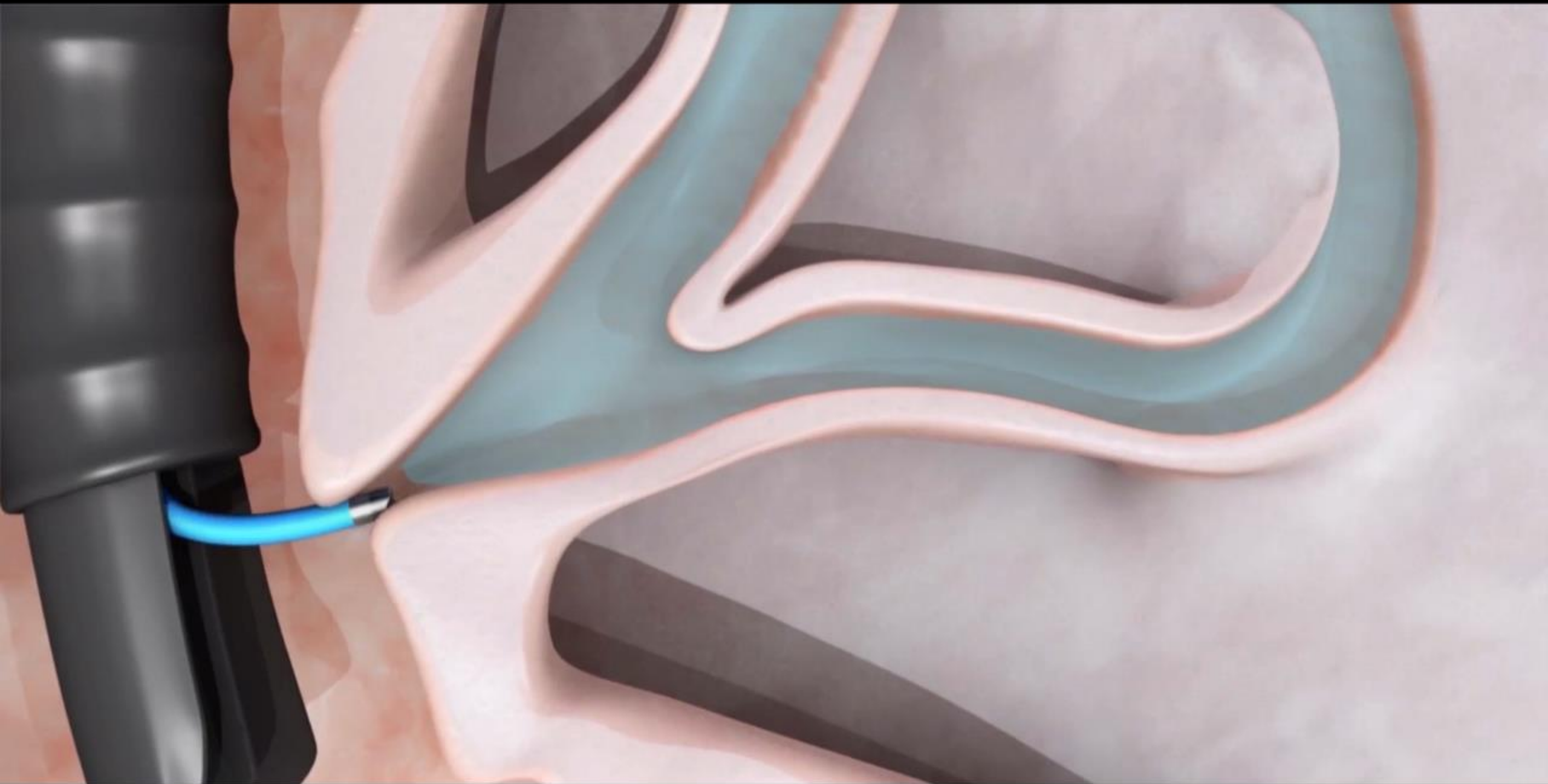
Lithotripsy

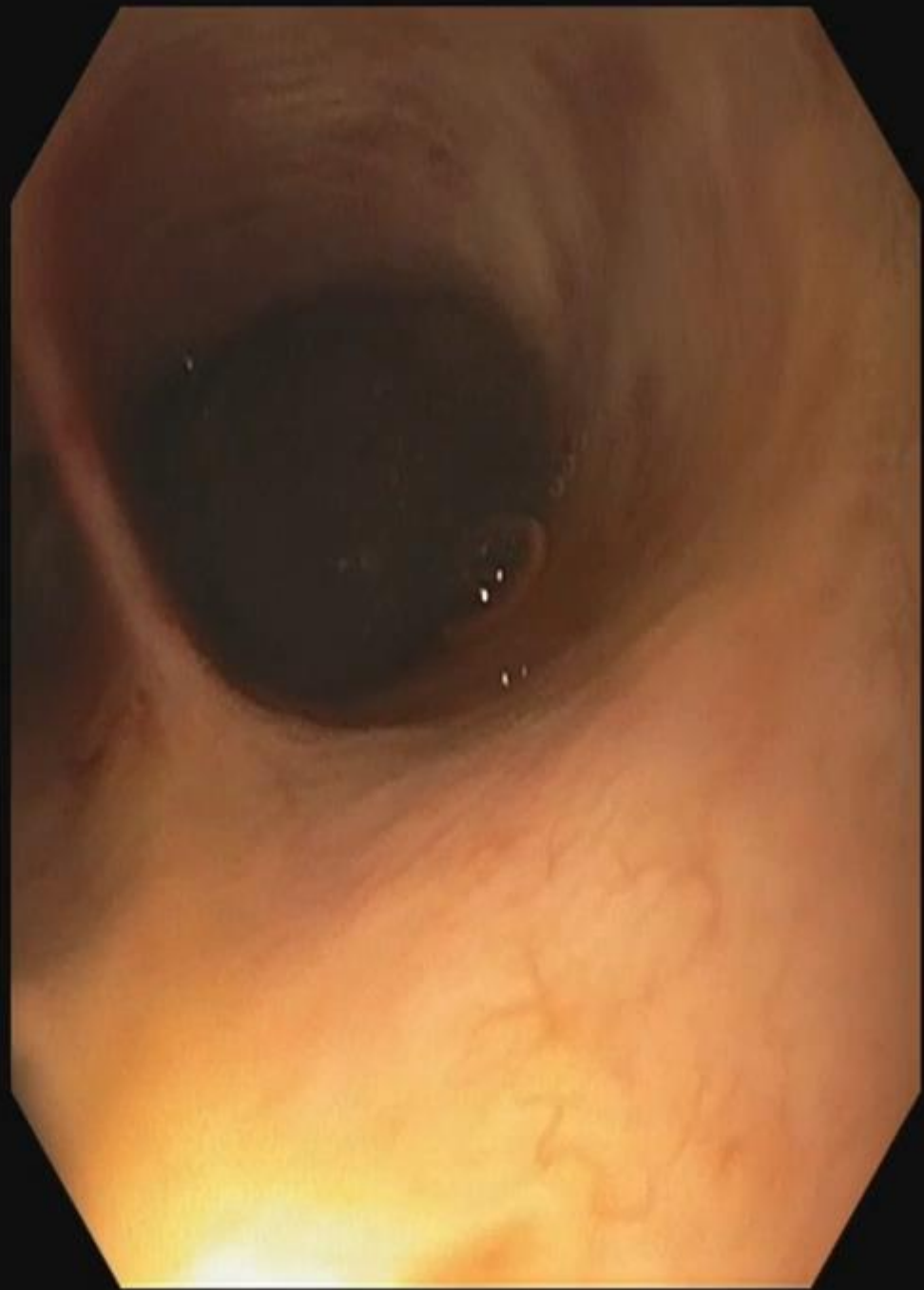- ▶ *Electrohydrophilic* → *success 97%.*
- ▶ *Laser* → *Success 99%.*
- ▶ *Normal Saline or Water.*
- ▶ *Distance between prob and stone 1 cm.*
- ▶ *From away the wall of bile duct perforation.* 





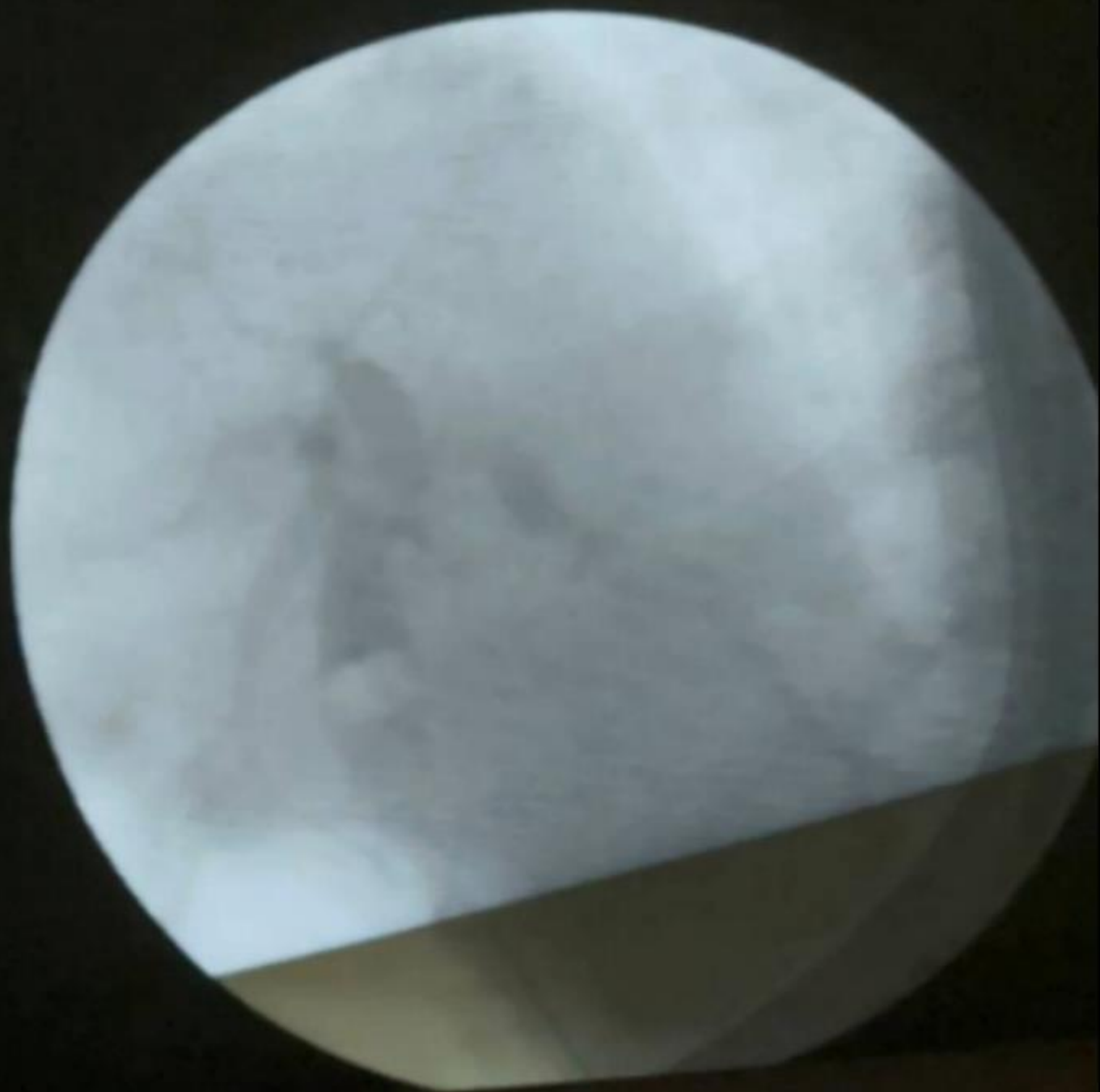


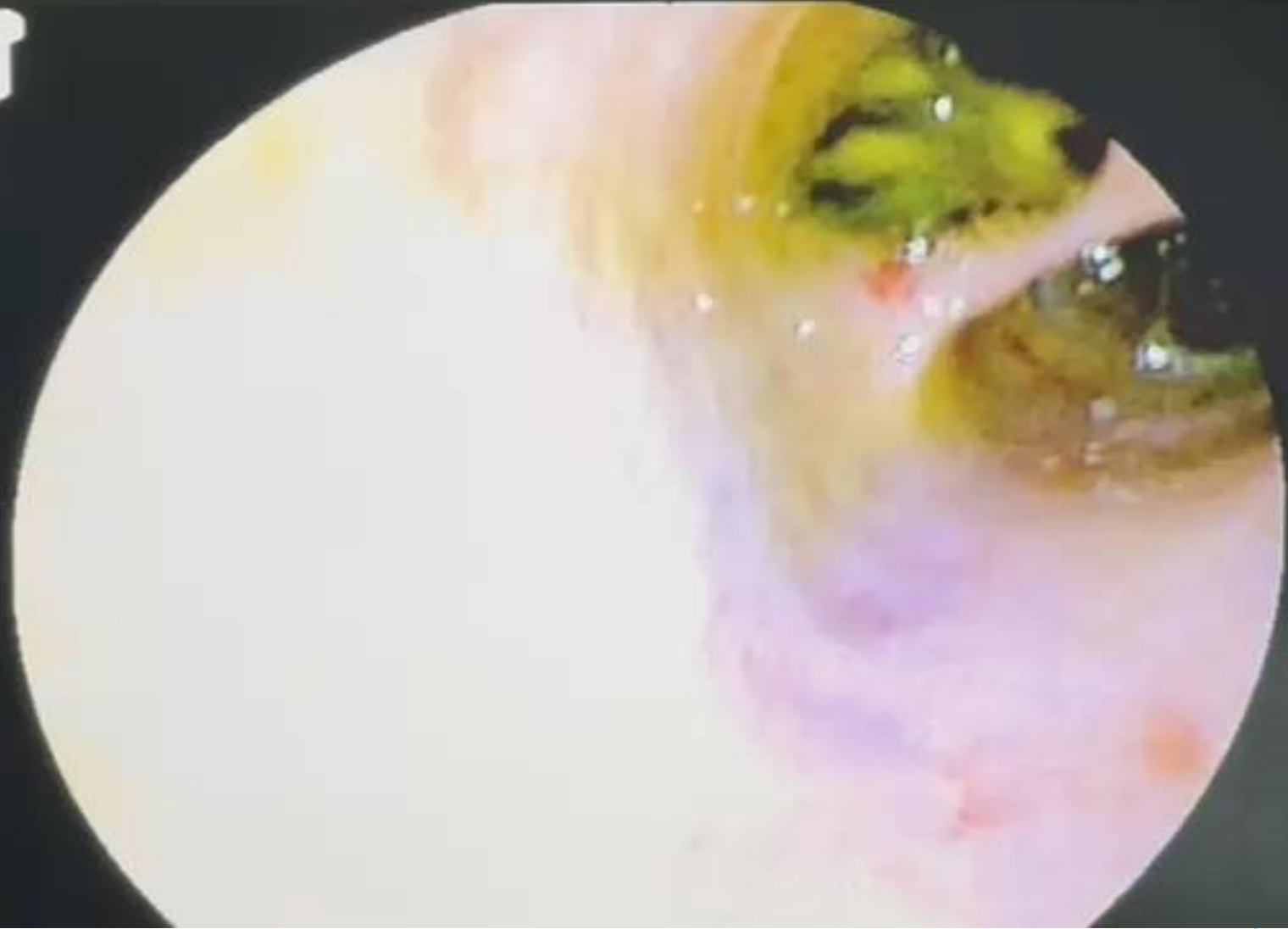


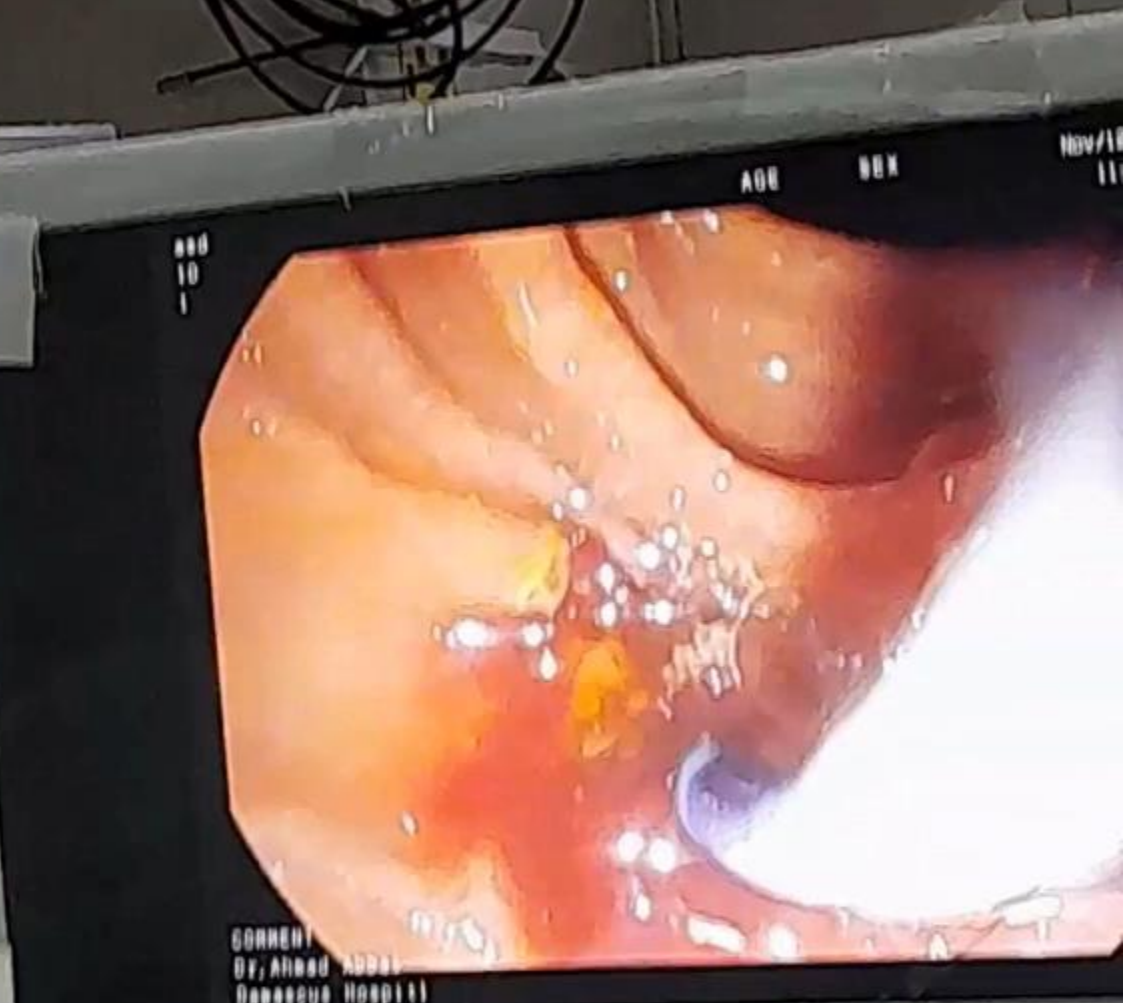


Our Experiences In Damascus Hospital With CHOLANGIOSCOPY:

- ▶ *Stenosis in Left intra hepatic Duct in chronic Hepatitis B
 ➡ Benign Stenosis.*
- ▶ *Defect in middle common Bile Duct ➡
 Cholangiocarcinoma.*
- ▶ *Stenosis in MRCP ➡ No Stenosis in CholangioScopy.*
- ▶ *Biopsy Of Cholangiocarcinoma in patient with Metal
 Stent(Follow UP).*







PENTAX



