

**Acid related disorders: GERD**

**Progress in Endoscopic  
management of GERD**

**Karbalaa 8.th**

**March 16-18, 2016**

**Prof. Fayez Sandouk**

**MD FRCP**

*Chairman Young Clinicians Program in Africo  
Middleast Association of Gastro-Enterology  
YCP in AMAGE*



# GERD

## 1. How Common ?

## 2. Diagnostic Approach for GERD

- Symptoms base,
- Endoscopy base,
- Therapeutic trial

## 3. Medical Approach:

- Initial Rx,
- Long Term Rx,
- Refractory cases

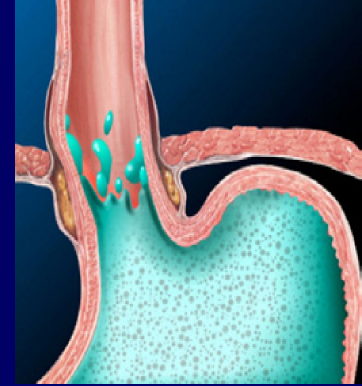
## 4. Progression in Endoscopic Approach

- Plicator
- Enteryx
- Stretta





# GERD Symposium 2014 “Endoscopic Therapy”

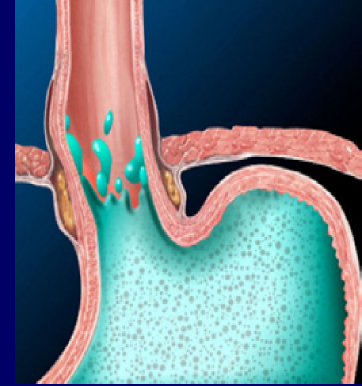


## Treatment Modalities

1. Medications as from 2004 **I TQD**
2. Surgery
3. Endoscopy 2005



# GERD Symposium “Endoscopic Therapy”

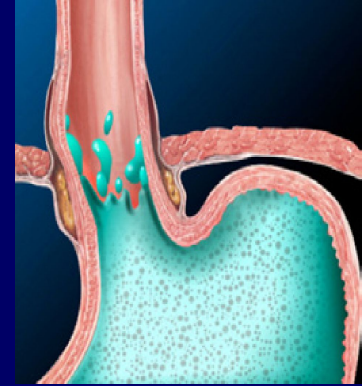


Randomized trials have compared

- **M**edical vs **S**urgical management,
- **L**aparoscopic vs **O**pen surgery,
- **P**artial vs **T**otal funduplications.



# GERD Symposium “Endoscopic Therapy”



## Surgery vs Medications

The SAME on the long term (5 years):

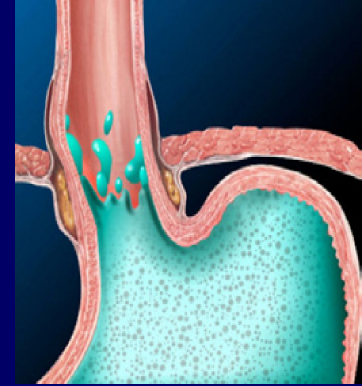
- High rates of Patient Satisfaction at late follow-up
- Surgery, left for Young, Moderate, & Severe GERD
- After 5 Y 32% recurrence (50% needed repair)

Expert Rev Gastroenterol Hepatol. 2010;4(2):235-243

Acta Otorhinolaryngol Ital. 2006 Oct; 26(5): 281–286.



# GERD Symposium “Endoscopic Therapy”



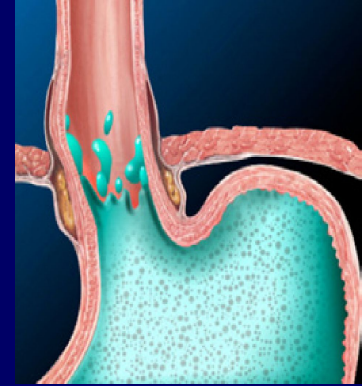
**L**aparoscopic vs **O**pen fundop.

## LAP

- Quicker convalescence
- Fewer complications
- Similar longer term outcome



# GERD Symposium “Endoscopic Therapy”



## Lap. Fundoplication Surgery

One-to-three days in hospital

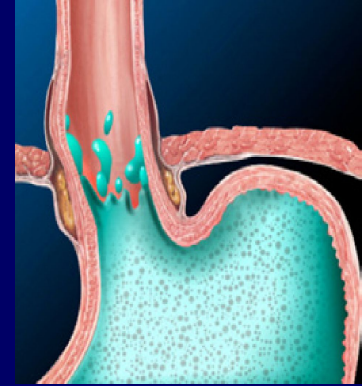
Return to work 2 - 3 **weeks**

Endoscopic Alternative

Return to work 1-2 **days**



# GERD Symposium “Endoscopic Therapy”



## Endoscopic Procedures “2005”

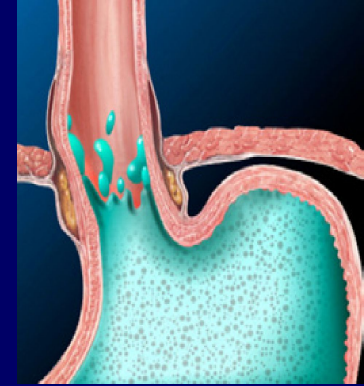
Evidence Base is limited to some Small Sham-Controlled studies & Cohort studies with **Short-term** follow-up, showed the same result of Lap. on

**Symptoms + Quality of life+ Pt. Satisfaction**

Lack of **Long-term** controlled study comparing Endoscopy with Laparoscopic Surgery.



# GERD Symposium “Endoscopic Therapy”



## Evidence Base Evaluation Metanalysis

### A. Quality of Evidence:

1. (+) Very Low
2. (++) Low
3. (+++) Moderate
4. (+++++) High

### B. Grade of Recommendation:

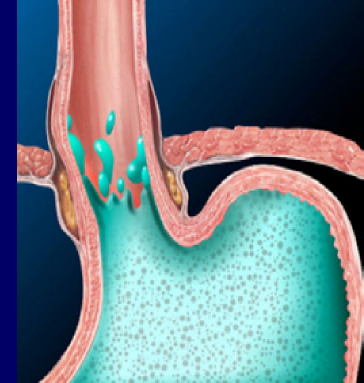
Weak / Strong

Expert Rev Gastroenterol Hepatol. 2010;4(2):235-243

Acta Otorhinolaryngol Ital. 2006 Oct; 26(5): 281–286.



# GERD Symposium “Endoscopic Therapy”



A). Endoluminal gastroplasty :  
“Esophyx” & “Endocinch” 2005

B). Polypolymer Injection :  
“Enteryx” 2009

c). Radio Frequency :  
“Stretta” 2005 2011

D). ESD & EMR for Barrett’s



# GERD Sy

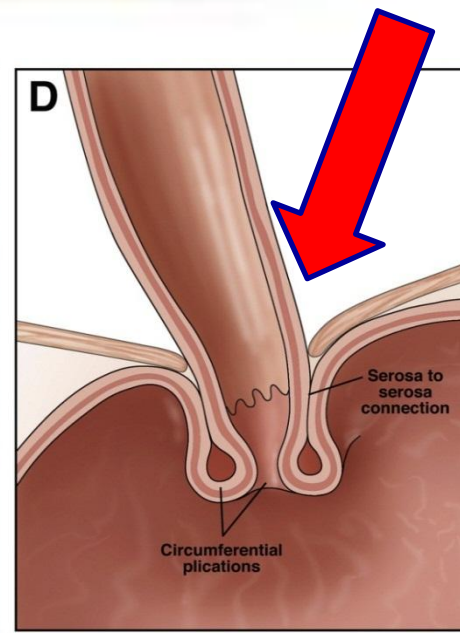
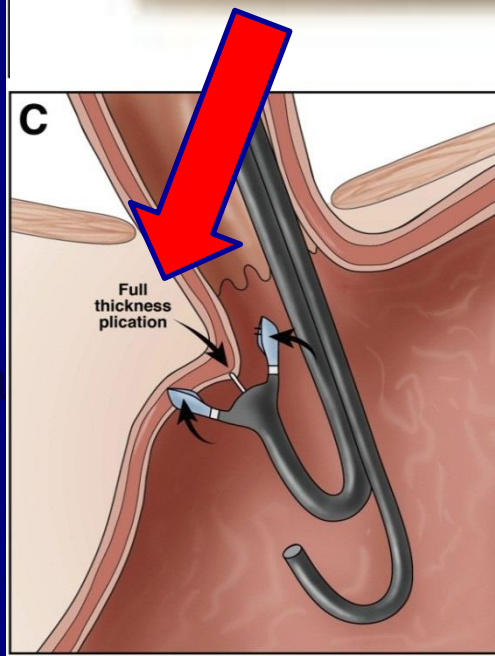
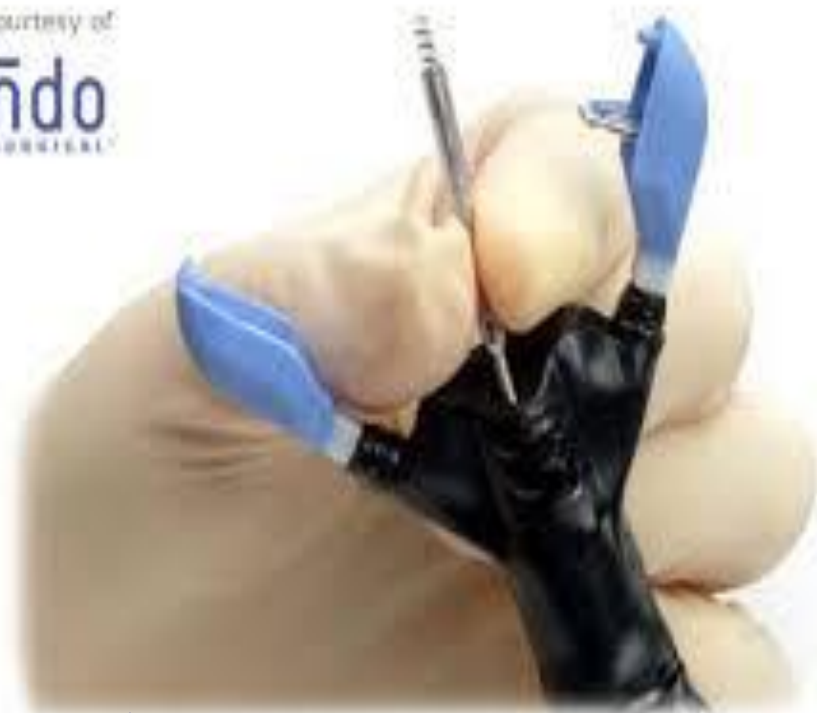## “Endoscop

### A). Endoluminal gastro Esophyx 2006

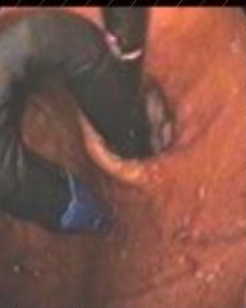Endoscopic gastroplasty  
plication of the gastric folds  
immediately distal to the  
oesophago-gastric junction  
by “H-shaped” fasteners from  
Preloaded poly-propylene  
**STICHES “Bringing  
Serosa to Serosa Fusion”**

Polyme Injection :

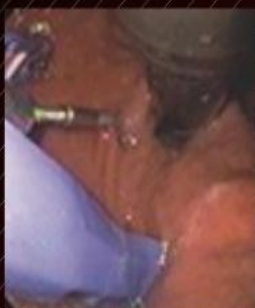courtesy of  
n̄do  
SURGICAL



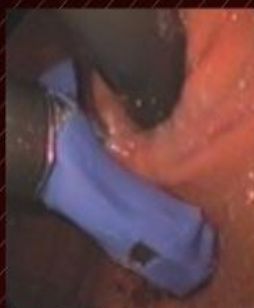# Técnica



1 Plicator ynd gastroscopio en retroflexion en UEG



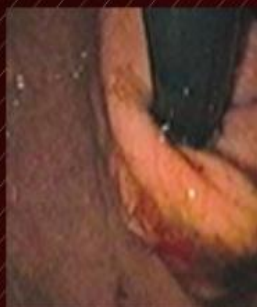2 Brazos abiertos y retractor de tejido hasta la serosa



3 Pared gástrica retraída



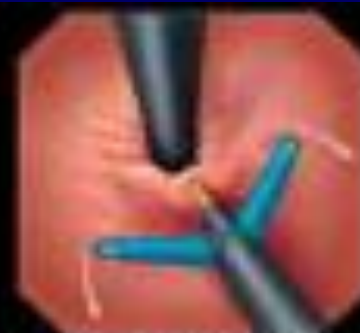4 Cierre de los brazos y colocacion del nudo (implante)



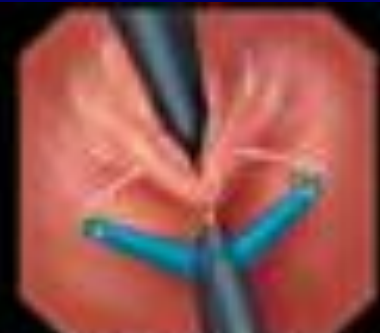5 Resultado



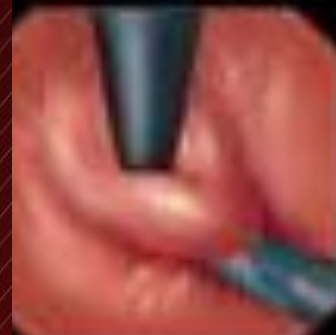1 Gastroscopio 1 in



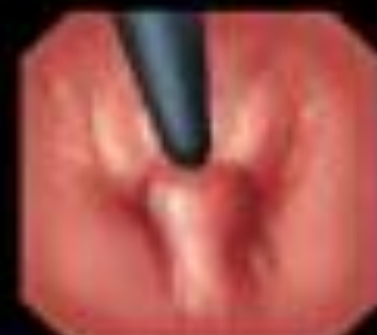2 Arms opened, tissue retractor advanced to serosa.



3 Gastric wall retracted, arms closed.

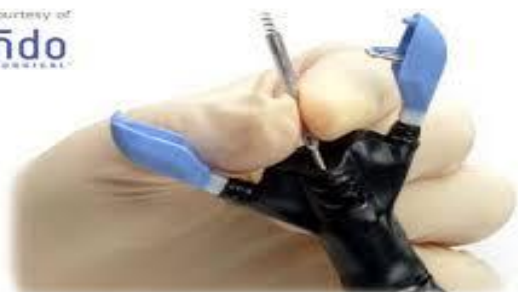

4 Single, pre-cut implant is employed, securing serosa-serosa plication.



5 Full-thickness plication restructures normal anti-reflux barrier.

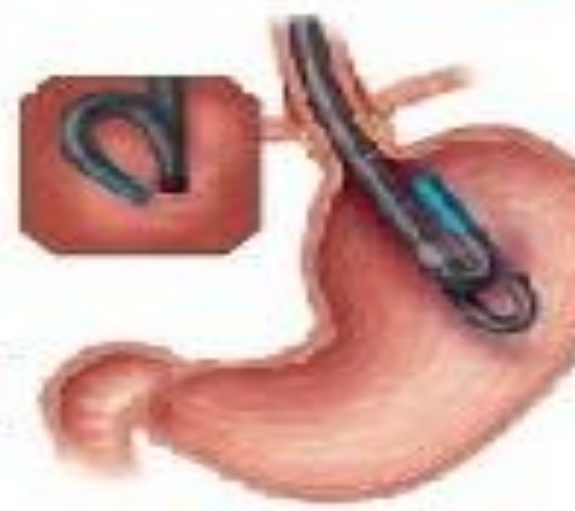courtesy of n̄do

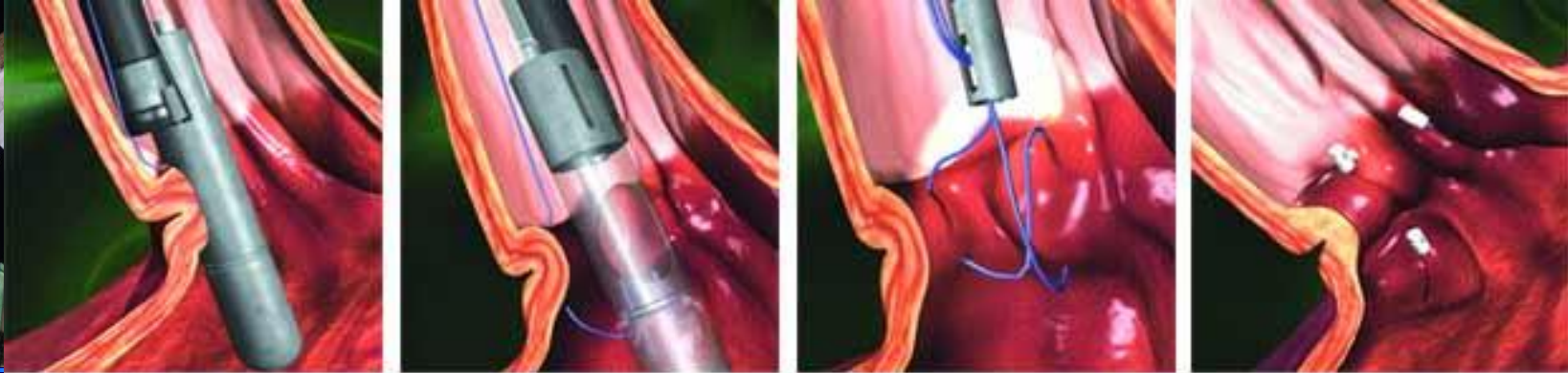


Esophyx



WLH



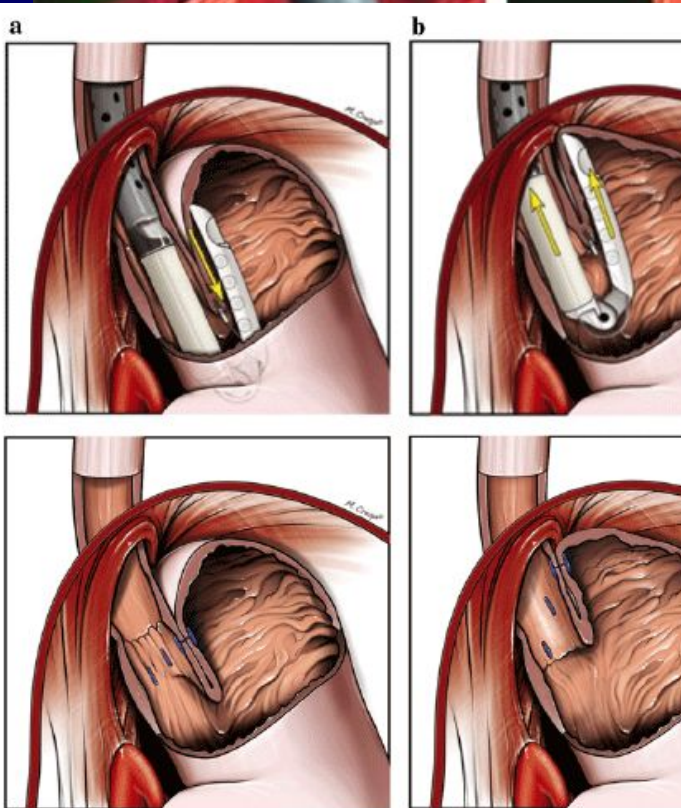
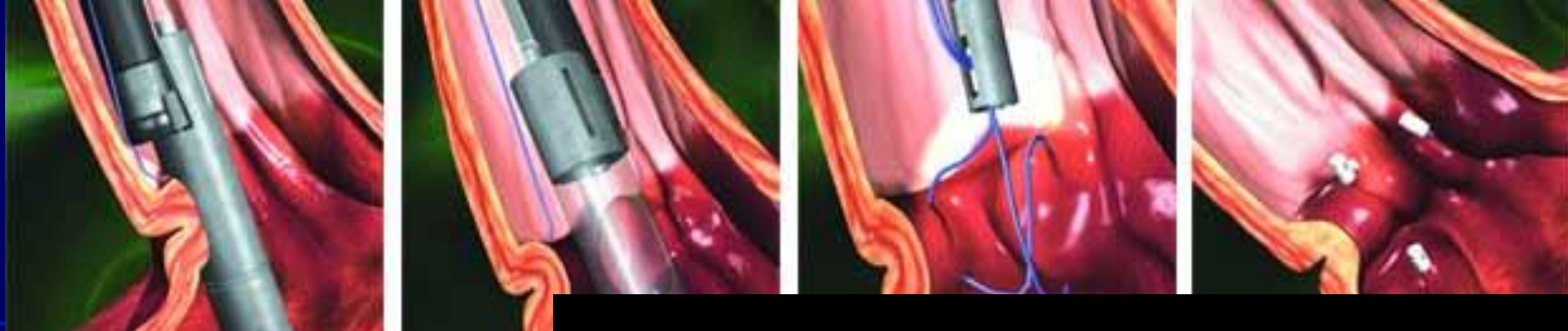


STEP BY STEP In EndoCinch, the surgeon lowers the suturing system under endoscopic visualization (Fig. 1), then places two adjacent stitches in apposition, forming a plication (Fig. 2). The plication alters the valve (Fig. 3) where acid can backflow into the esophagus. Depending on the case, multiple plications may be needed (Fig. 4).

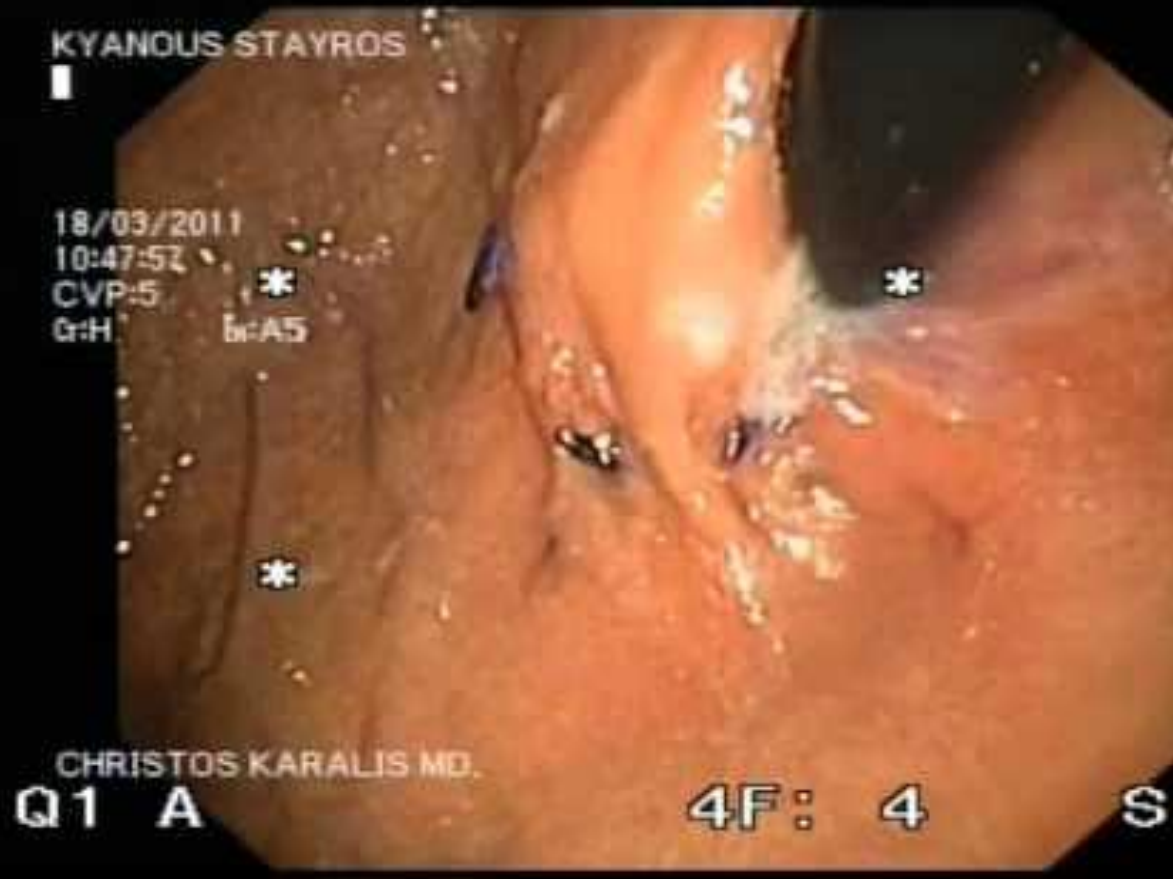
## A). Endoluminal gastroplasty :

### Endocinch

Plication of the gastric folds immediately distal to the oesophago-gastric junction with **TWO** sets of **SUTURES** via a device inserted over tube.

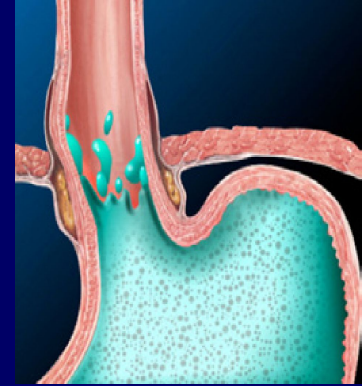


# Endocinch





# Quality of Evidence Grade of Recom.



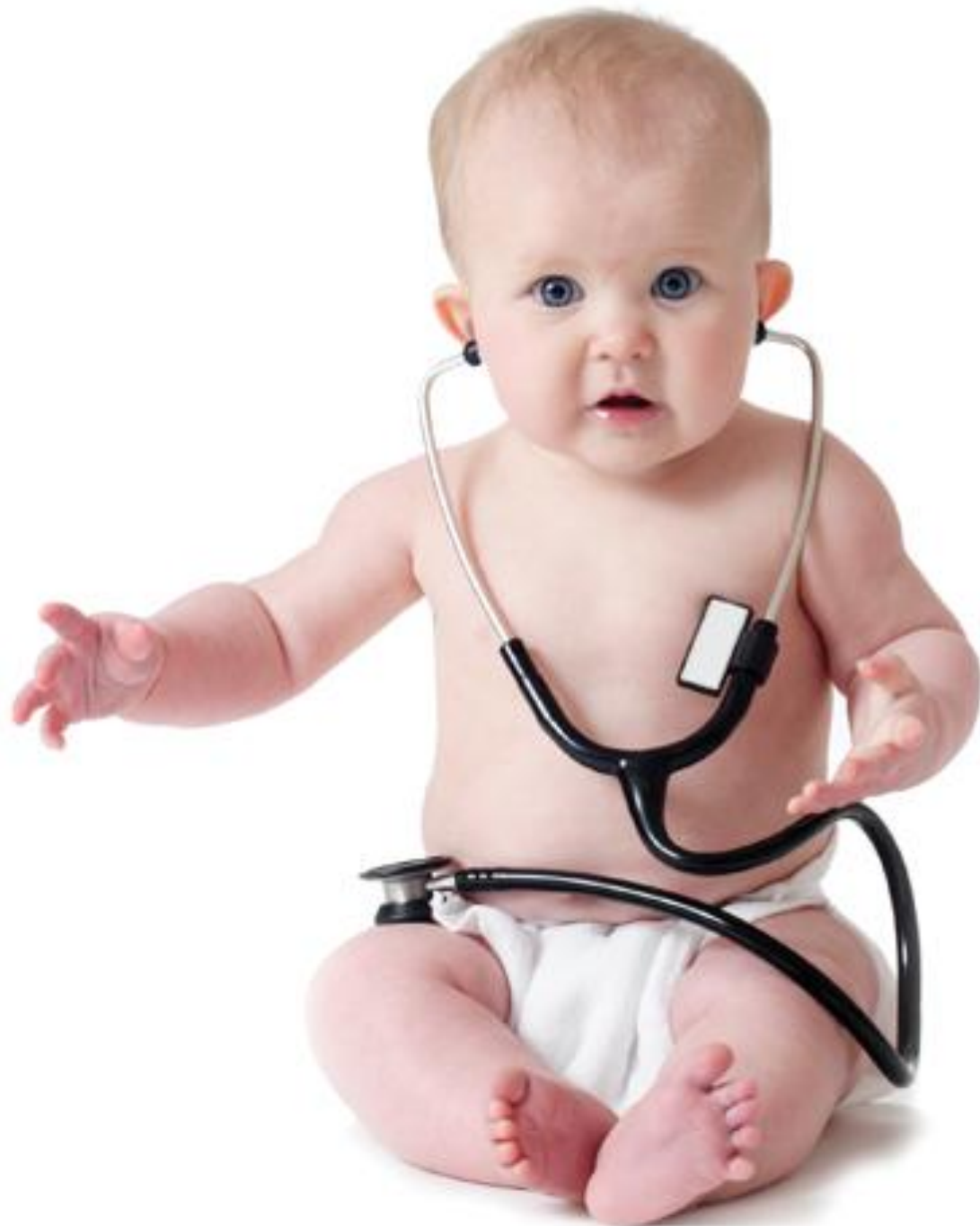A). Endoluminal gastroplasty :

“Esophyx” & “Endocinch” 2006

**Result: Difficult Application  
Expensive , easy Break down**

**Quality of Evidence: (++) Low  
Grade of Recommendation: Weak**

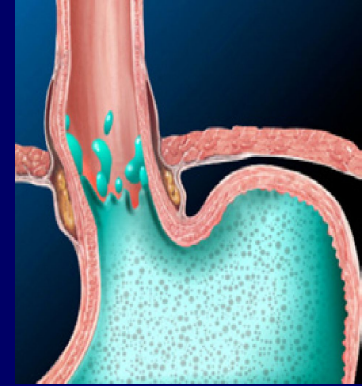
Weak Evidence for Barrett's





# GERD Symposium

## “Endoscopic Therapy”



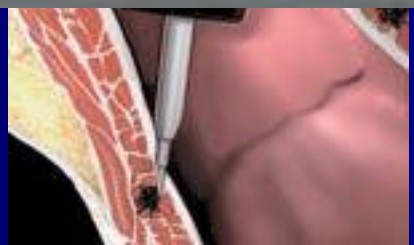
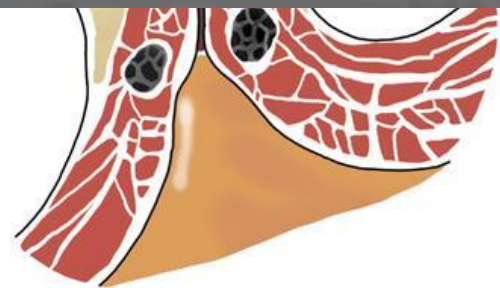
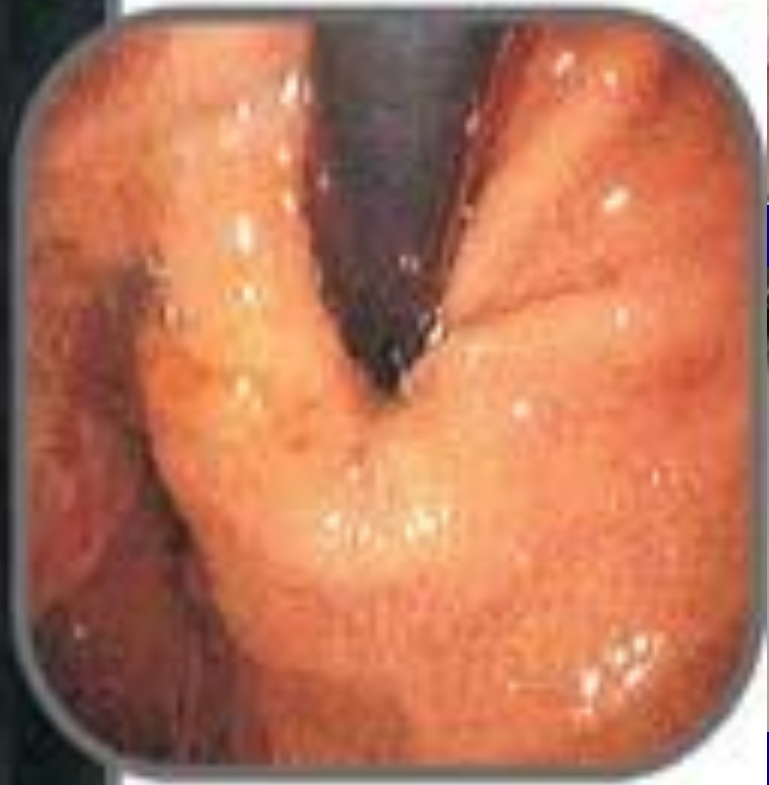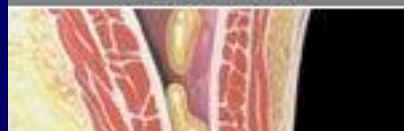Transoral fundoplication;  
“TIF” & “Esophyx” 2005

**B). Polymer Injection :**  
“Enteryx” 2009

Endoscopic implantation of a bulking agent  
(polymer) **into the Muscularis** of Esophagus  
at the region of the LES.


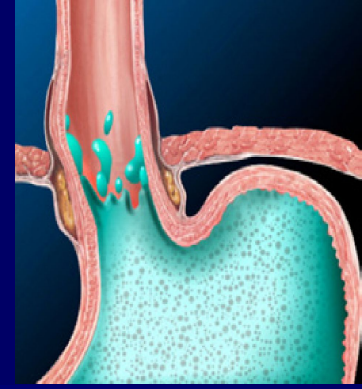
Alternative to Nissen for Barrett's

Acid Reflux

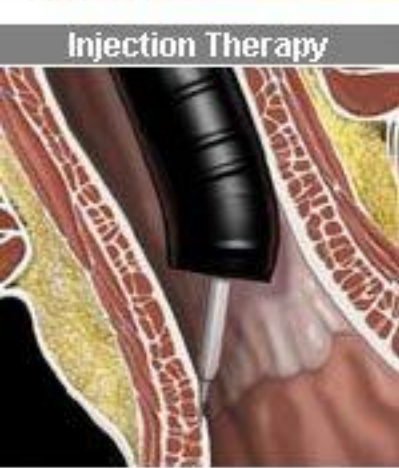


**Enteryx**

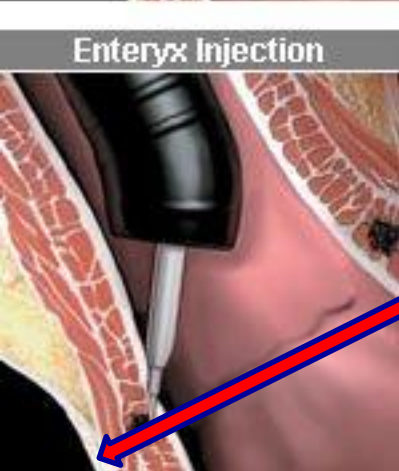
# Quality of Evidence



- \* **Result: Difficult** (Three Stages of Launching)
- \* **Adverse: mild Chest pain , Garlic Smell 48h.**
- \* This technique is no longer commercially available since it has been **withdrawn from the market** due to safety issues (five deaths attributable to the procedure due to Pleural empayema).



Injection Therapy

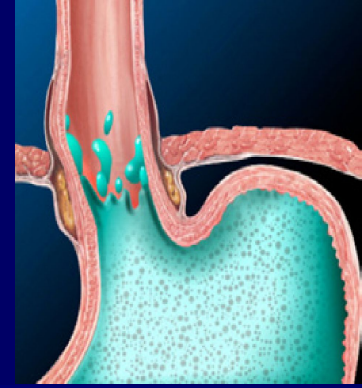


Enteryx Injection

**Enteryx**

# GERD Symposium

## “Endoscopic Therapy”



- Endoscopically guided.
- Outpatient procedure in 60 min.
- Stretta Catheter delivers **RF** energy to LES and gastric Cardia.

- Low power **(5 Watts)** RF energy and generates low tissue temperatures **(65c to 85c)** during a series of **one-minute treatment cycles)**

- Back to work **1-2 DAYS** .

c). Radio Frequency :  
“Stretta” 2005 2010

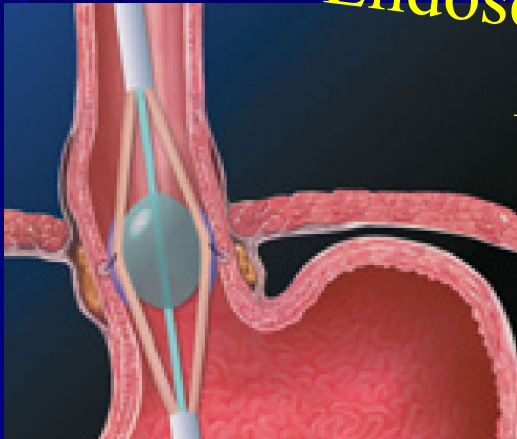
D). Endoscopic Bariatric Therapy

# Stretta in GERD

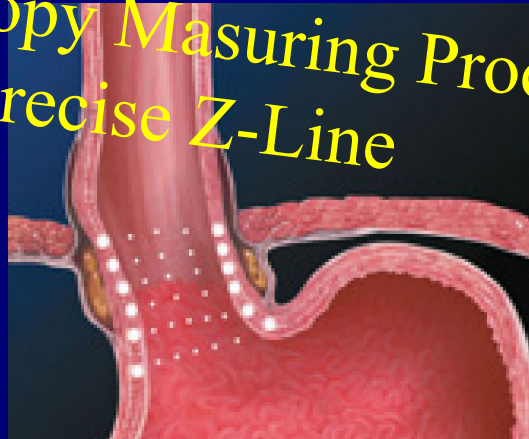
Stretta = Thin & Narrow

## Mechanisms of action (1)

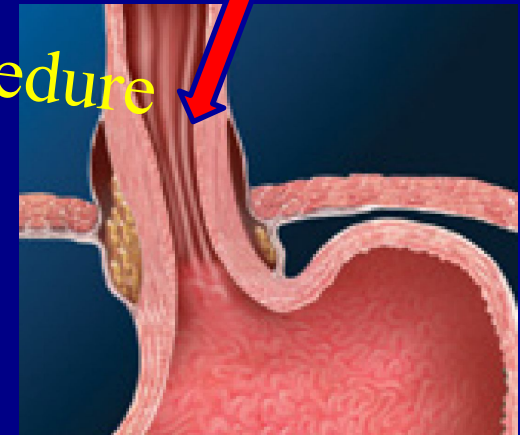
*An Endoscopy Measuring Procedure  
Precise Z-Line*



Concentrated RF energy delivered to tissue

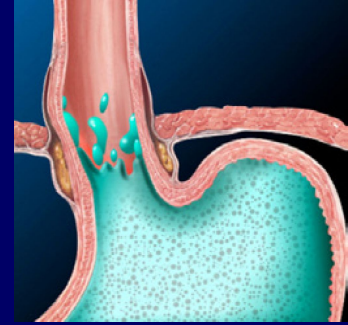


4 levels 5mm apart  
Z-Line & above  
2 levels Fundus  
denatured collagen  
lesions created



Barrier function improved, in 1-2 months

# Stretta in GERD



## Mechanisms of action (2)

1. Mechanical alteration of the gastroesophageal junction...
2. Increased gastric yield pressure within a month (10-35 mm.Hg)
3. Normalized delayed gastric emptying.

*Reymunde A, Santiago N. Long-term results of radiofrequency energy delivery for the treatment of GERD: sustained improvements in symptoms, quality of life, and drug use at 4-year follow-up. Gastrointest Endosc 2007;65:361-6.*

Precise Z-Line

**LEVELS 1-4  
ANTEGRADE**

With GW



**LEVELS 5-6  
RETROGRADE**



Without GW  
+ without SUCTION

## Endoscopy Measuring Procedure "Precise Z line" + 6 levels

4). 10 mm above Z line : 4 needles X 2 = 8 sites

3). 5 mm above Z line 4 needles X 2 = 8 sites

2). **Just at Z line** 4 needles X 2 = 8 sites

1). 5 mm below Z line 4 needles X 2 = 8 sites

## Remove GW + Suction

5). Inflate Balloon **25** ml Pull gently upward with finger 4X2=12 sites

6). Inflate Balloon **20** ml Pull gently upward with finger 4X2=12 sites

**Total 54 burning sites**

أولاً - نحدد خط " Z "  
ثانياً - ستة « ٦ » مستويات

1 - 4 Rotate 15 degrees

5 & 6 Rotate 30 & 60 degrees

**Total 54 sites**

**We should NOT lose more than 14 sites  
Otherwise; should be repeated.**

٥ بالمعدة نفخ بالون ٢٥ مم / سحب بالإصبع حتى يعلق بالسقف

٦ بالمعدة نفخ بالون ٢٠ مم / نفس الشيء

A. Mucosal Temp 25-45c

حرارة المخاطية يجب أن تكون بين ٢٥ - ٤٥ درجة

A

B. Muscularis Temp 65-99c

حرارة العضلية يجب أن تكون بين ٦٥ - ٩٩ درجة

B

C. Impedance 150-900

المعاوضة Impedance يجب أن تكون بين ١٥٠ - ١٠٠٠

C

(ممانعة التيار الكهربائي ، تفصل لوحدها إذا كانت أقل من ١٠٠ ؟ قد يكون سلك الدليل ملموسا)

C

65 - 99 c

B

A

C

B

A

A

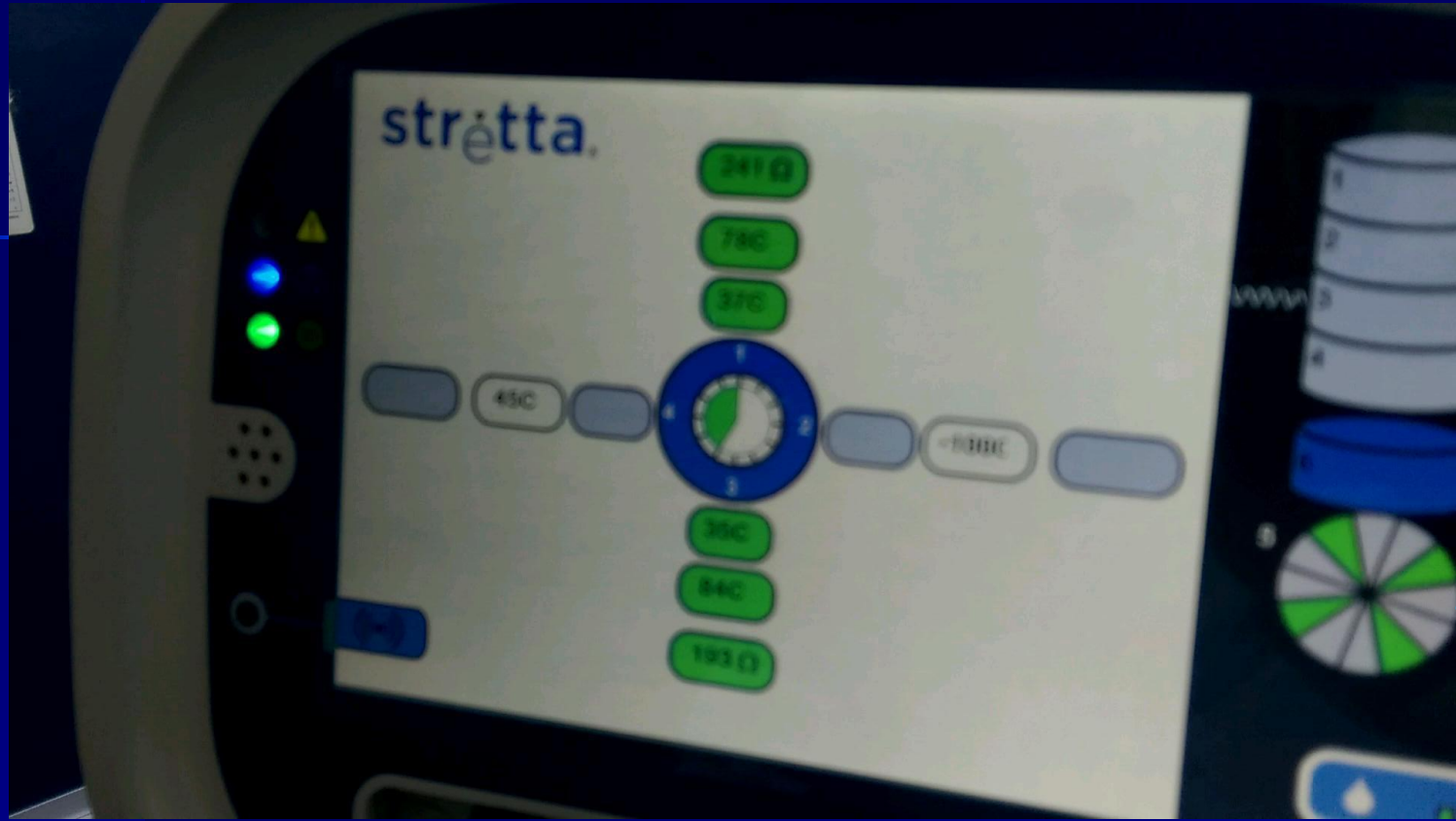
B

C

A

B

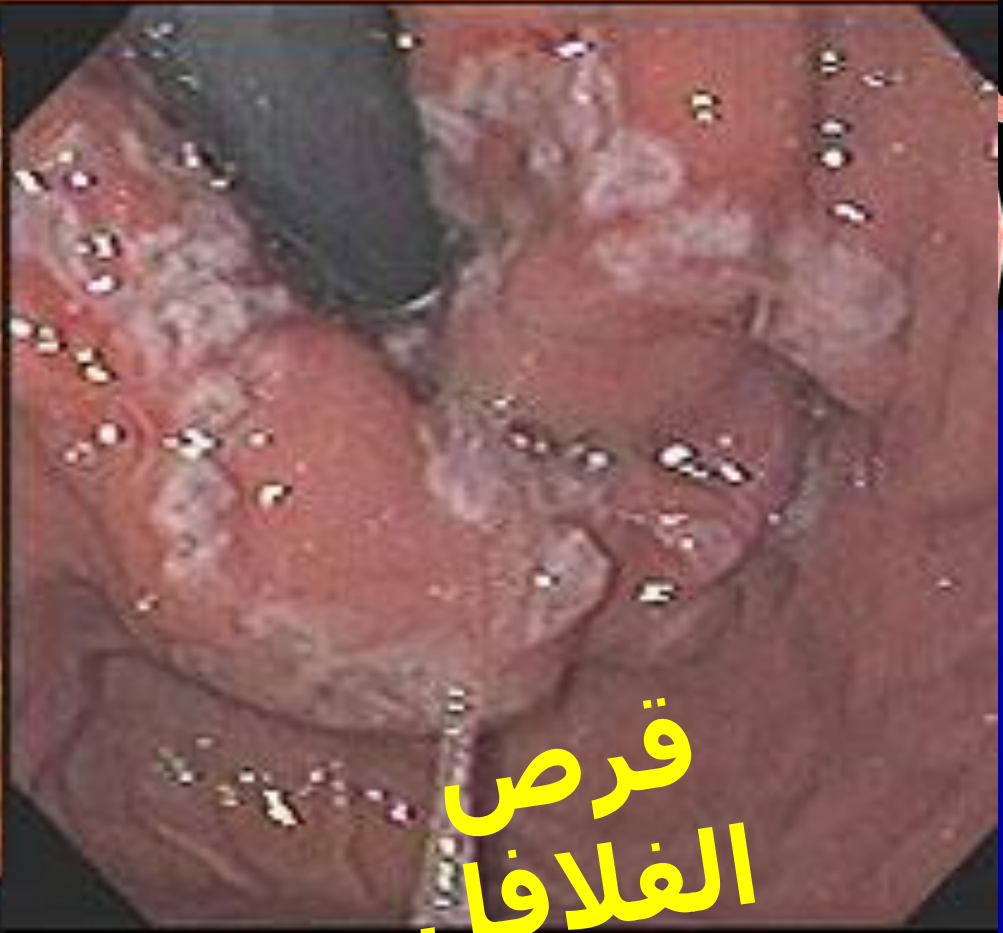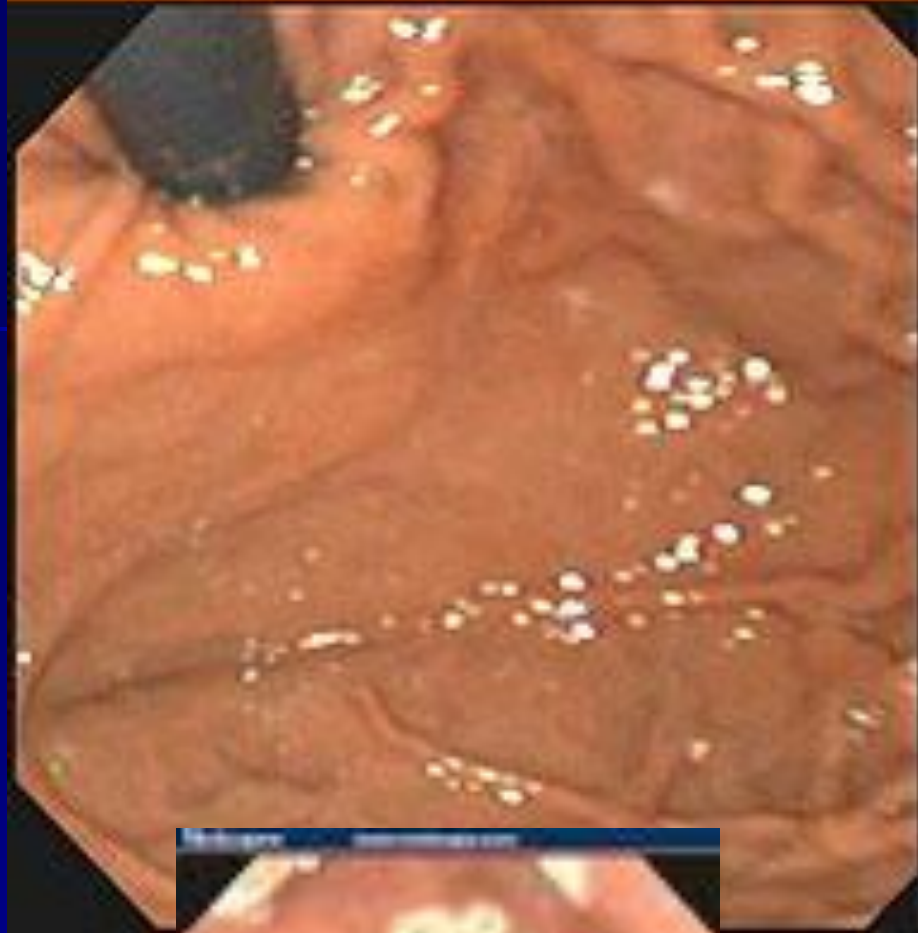
C



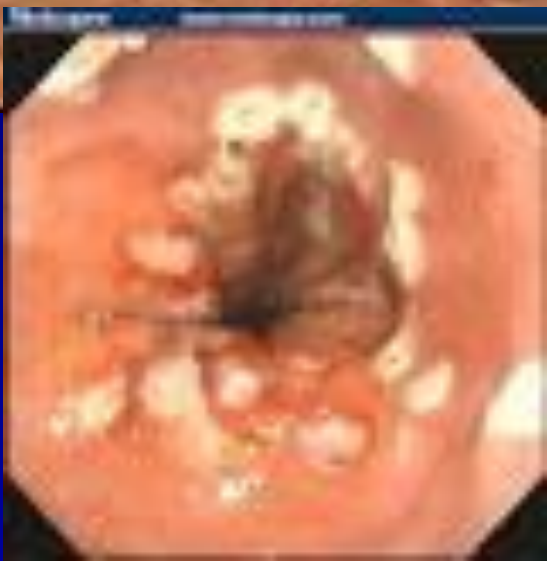6 Levels

Circumfincial

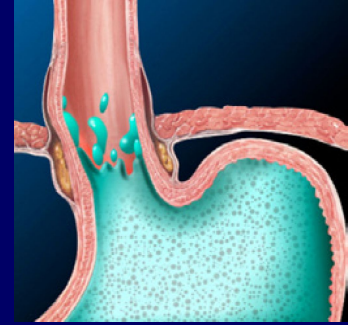




قرص  
الفلافل  
Donuts



# Stretta in GERD

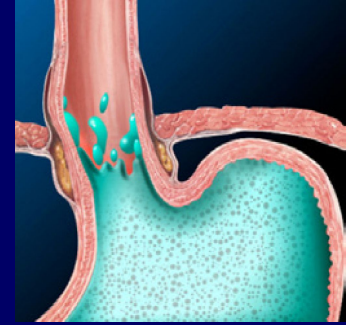


FILM

1 minute



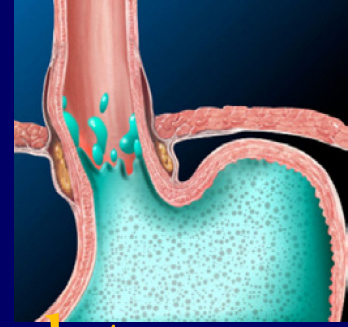# Stretta in GERD



## Minimally Invasive Stretta Therapy Short Term FU

- 1.** Less complications than surgery, mild Chest Pain, Sucralfate for 2-3 days
- 2.** Significant sustained improvement up to 4 years
- 3.** Doesn't prevent surgery later

# Stretta in GERD



Long Term FU (24 & 48 months) with objective data

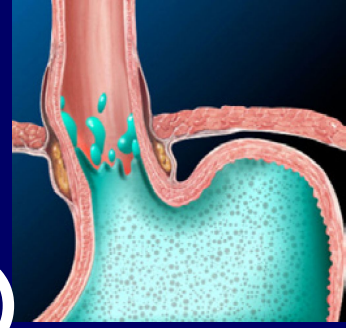1. Improved heartburn scores,
2. Improved GERD specific quality of life scores and general quality of life scores at both 24 and 48 months in 92.8% of patients.
3. Both mean heartburn and GERD-HRQL scores decreased significantly and both mental and physical quality of life as measured by SF-36 improved.
4. At 48 months 72.3% of patients were completely off PPI medications.

## The same Long Term results of Surgery

Dughera & colleagues 2011 Surgical Endoscopy. 2010. 24: 854-858.

# Stretta in GERD

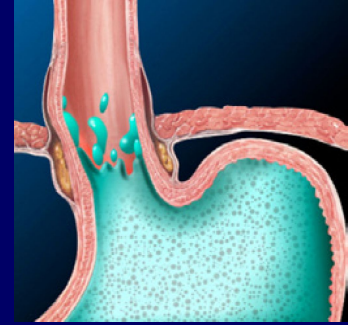
( 2005 - □ 2010 improved (Balloon FDA )



## Adverse Outcomes

1. Mild Temporary post procedure chest discomfort,
2. Mild fever,
3. Transient Vomiting and transient dysphagia,
4. A single Major adverse event occurred in one patient with prolonged but transient **gastroparesis**; the patient required hospitalization for 3 weeks, and gastroparesis resolved completely within 8 weeks.

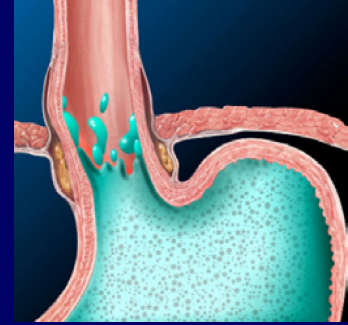
# Stretta in GERD



## The optimal candidate for Stretta Therapy:

1. - **Has failed** or is intolerant of PPI therapy
2. - Has less than a 3 cm hiatal hernia
3. - Has Non-erosive or Non-ulcerative esophagitis
4. - Has extra-esophageal manifestations of GERD
5. - Has reflux related gastroparesis
6. • Failed Nissen patients
7. • Post Gastric Bypass patients with GERD

# Stretta in GERD

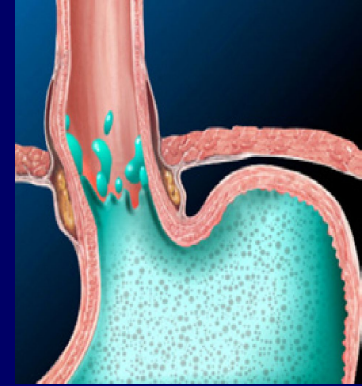


## Contraindications for Stretta:

1. Subjects under the age of 18
2. Pregnant women
3. Patients without a diagnosis of GERD
4. Patients with a hiatal hernia larger than 3 cm
5. Achalasia or incomplete LES relaxation in response to swallow



# GERD Symposium “Endoscopic Therapy”



## Evidence Base Evaluation Metanalysis

### A. Quality of Evidence:

1. (+) Very Low
2. (++) Low
3. (+++) Moderate
4. (+++++) High

### B. Grade of Recommendation:

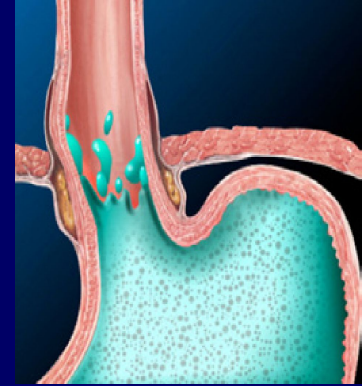
Weak / Strong

Expert Rev Gastroenterol Hepatol. 2010;4(2):235-243

Acta Otorhinolaryngol Ital. 2006 Oct; 26(5): 281–286.



# GERD Symposium “Endoscopic Therapy”

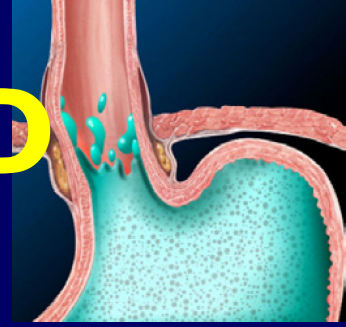


## Summery

| Procedure            | Quality of Evidence | Grade of Recommendation |
|----------------------|---------------------|-------------------------|
| Endocinch & Esophyx  | ++                  | Weak                    |
| Enteryx Implantation | Withdrawn           |                         |
| <b>Stretta</b>       | <b>+++ /++++</b>    | <b>Strong</b>           |
| Barrett's ESD & EMR  |                     |                         |

# Endoscopic RX for GERD

## Summery



- Similar results of Surgery and Medications
- Guidelines and recommendations are intended to be flexible (not firm)
- Should be properly selective
- Left for Experience , cost , patient decision
- My personal opinion

## References

- Cadiere GB, Buset M, Muls V et al. Antireflux Transoral Incisionless fundoplication using EsophyX: 12-Month Results of a prospective multicenter study. *World Journal of Surgery*. 2008. 32:1676-1688.
- Cadiere GB; Rajan A et al. Endoluminal fundoplication (ELF) – evolution of EsophyX, a new surgical device for transoral surgery. *Minimally invasive therapy*. 2006. 15:6. 348-355.
- Cadiere GB; Rajan A et al. Endoluminal fundoplication by a transoral device for the treatment of GERD: a feasibility study. *Surgical Endoscopy*. 2008. 22: 333-342.
- Bergman S, Mikami J et al. Endoluminal fundoplication with EsophyX: The initial North American Experience. *Surgical Innovation*. 2008. 15:3. 166-170.
- Demyttenaere S; Bergman S et al. Transoral Incisionless fundoplication for gastroesophageal reflux disease in an unselected patient population. *Surgical Endoscopy*. 2010. 24: 854-858.
- Cadiere GB; Sante N et al. Two year results of a feasibility study on antireflux transoral incisionless using EsophyX. *Surgical Endoscopy*. 2009. 23:957 -964.
- Testoni P; Corsetti M et al. Effect of transoral Incisionless fundoplication on symptoms, PPI use, and pH impedance refluxes of GERD patients. *World Journal of Surgery*. 2010. 34: 750-757.
- Velanovich V. Endoscopic, endoluminal fundoplication for gastroesophageal reflux disease: initial experience and lessons learned. *Surgery*. 148. 4. 648-653.
- Barnes, W; Hoddinott, K et al. Transoral Incisionless Fundoplication offers high patient satisfaction and relief of therapy-resistant typical and atypical symptoms of GERD in community practice. *Surgical Innovation*. 2011. 18.
- Hoppo T; Immanuel A et al. Transoral Incisionless fundoplication 2.0 procedure using EsophyX for gastroesophageal reflux disease. *Journal of Gastrointestinal Surgery*. 2010. 14: 1895-1901.
- Bell R and Freeman K. Clinical and pH-metric outcomes of transoral esophogogastric fundoplication for the treatment of gastroesophageal reflux disease. *Surgical Endoscopy*. 2011. 25: 1975 – 1984.
- Trad K; Turgeon D et al. Long term outcomes after transoral Incisionless fundoplication in

## Cont. Refeferences:

- Trad K; Turgeon D et al. Long term outcomes after transoral Incisionless fundoplication in patients with GERD and LPR symptoms. *Surgical Endoscopy*. 2012. 26: 650-660.
- Narsule C; Burch M et al. Endoscopic Fundoplication for the treatment of gastroesophageal reflux disease: initial experience. *The Journal of Thoracic and Cardiovascular Surgery*. 2012: 143.1.
- Testoni P; Vailati C et al. Transoral Incisionless fundoplication (TIF 2.0) with EsophyX for gastroesophageal reflux disease: long term results and findings affecting outcome. *Surgical Endoscopy*. 2011.
- Svoboda P; Kantorova I et al. Our experience with transoral Incisionless plication of gastroesophageal reflux disease: NOTES Procedure. *Hepatogastroenterology*. 2011. 58: 1208-1213.
- Ihde G; Besancon K et al. Short term safety and symptomatic outcomes of transoral Incisionless fundoplication with or without hiatal hernia repair in patients with chronic gastroesophageal reflux disease. *The American Journal of Surgery*. 2011. 202. 740-747.
- Bell R; Mavrelis P et al. A prospective multicenter registry of patients with chronic gastroesophageal reflux disease receiving transoral incisionless fundoplication. *Journal of the American College of Surgeons*. 2012.
- Chen S; Jarboe MD; Teitlebaum DH; Effectiveness of a transluminal endoscopic fundoplication for the treatment of pediatric gastroesophageal reflux disease. *Pediatr Surg Int*. 2012 28:229-234

Thank You



Faye

