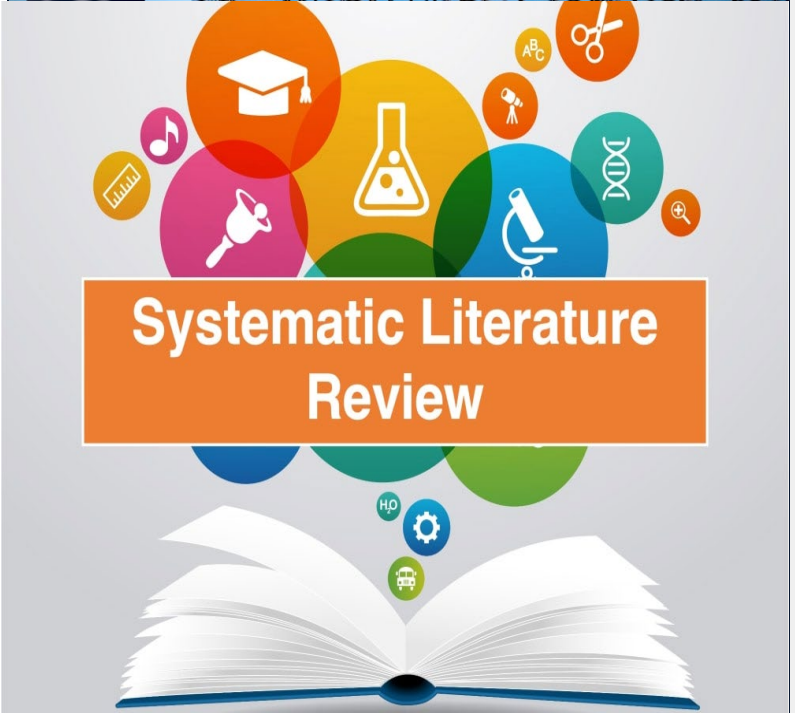
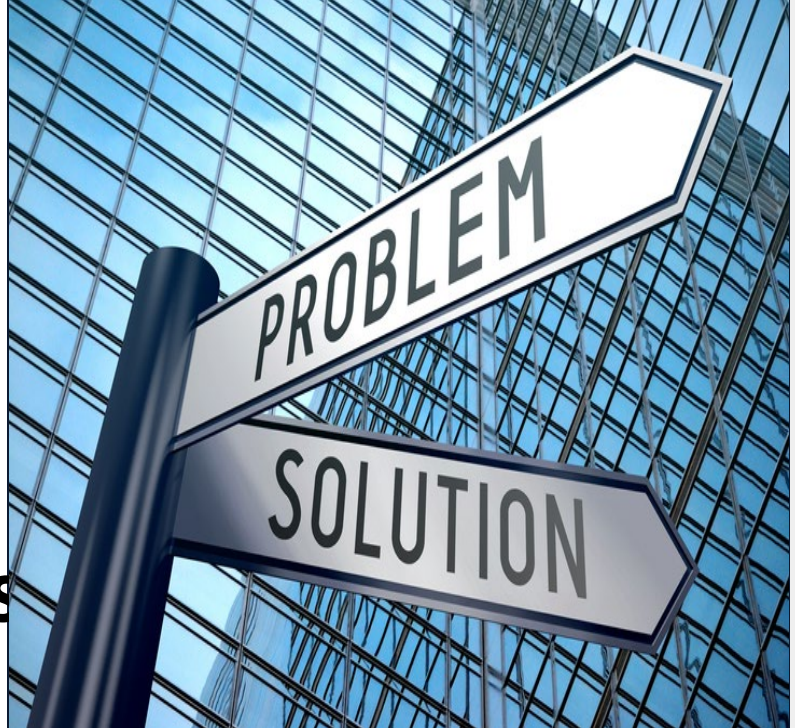

Toward Evidence Based Practice

Dilemma of acute sever ulcerative colitis

Dr. Soumar Alziadan (resident doctor)

Supervised by Dr.Marouf Alhalabi





Case presentation

“

- A 28-year-old Syrian female with 7 years of pancolitis
- She experienced a new flare of ASUC
- Despite completing two induction doses of infliximab (5mg/kg)

”

Non-response ?

1

Primary non-response to biologics

A dark blue envelope-shaped icon with a white flap at the top. A dark grey circle with the number '1' is positioned on the flap. The text 'Primary non-response to biologics' is centered in white. A white pill-shaped button is at the bottom.

2

Secondary loss of response


A yellow envelope-shaped icon with a white flap at the top. A yellow circle with the number '2' is positioned on the flap. The text 'Secondary loss of response' is centered in white. A white pill-shaped button is at the bottom.

3

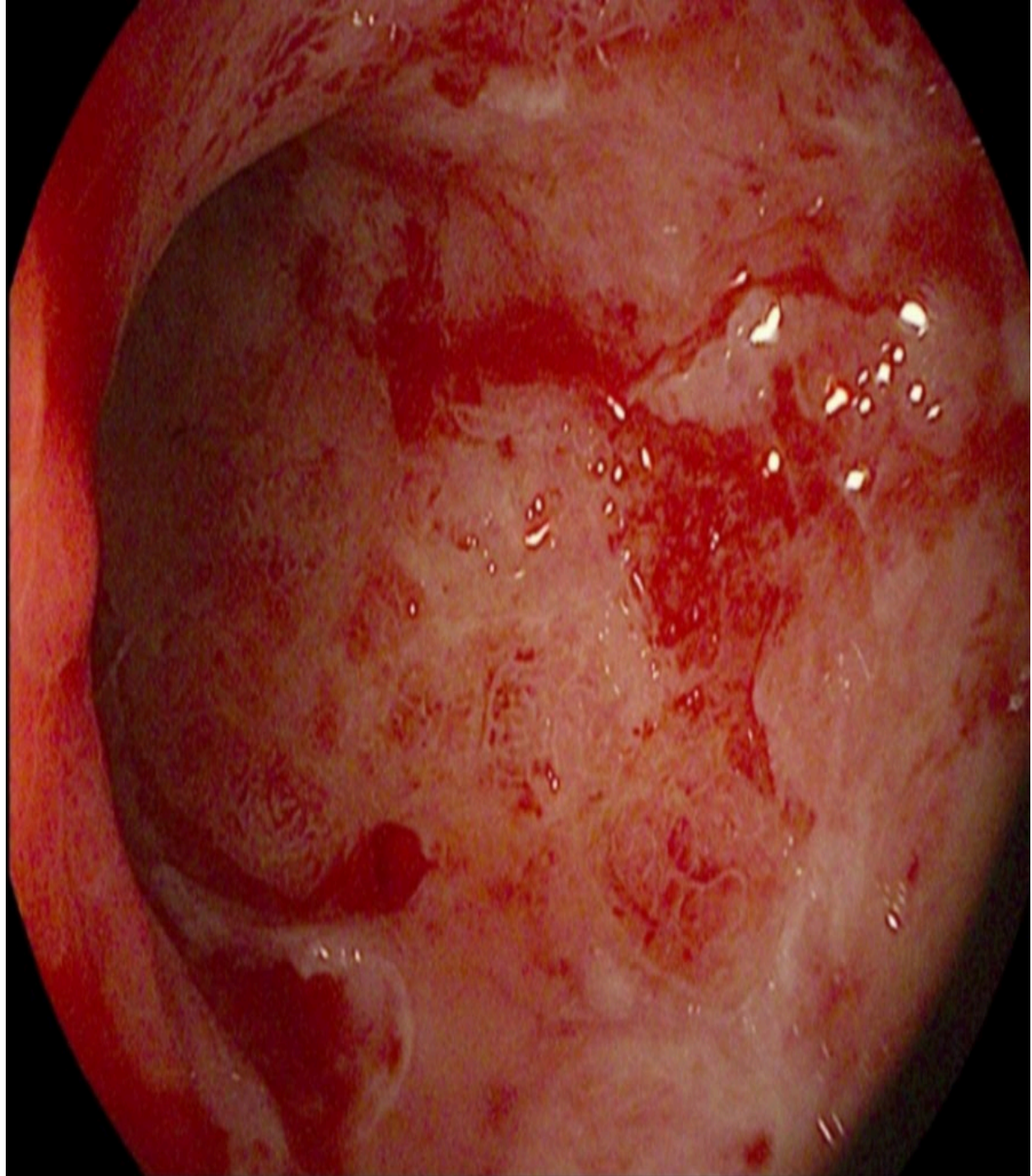
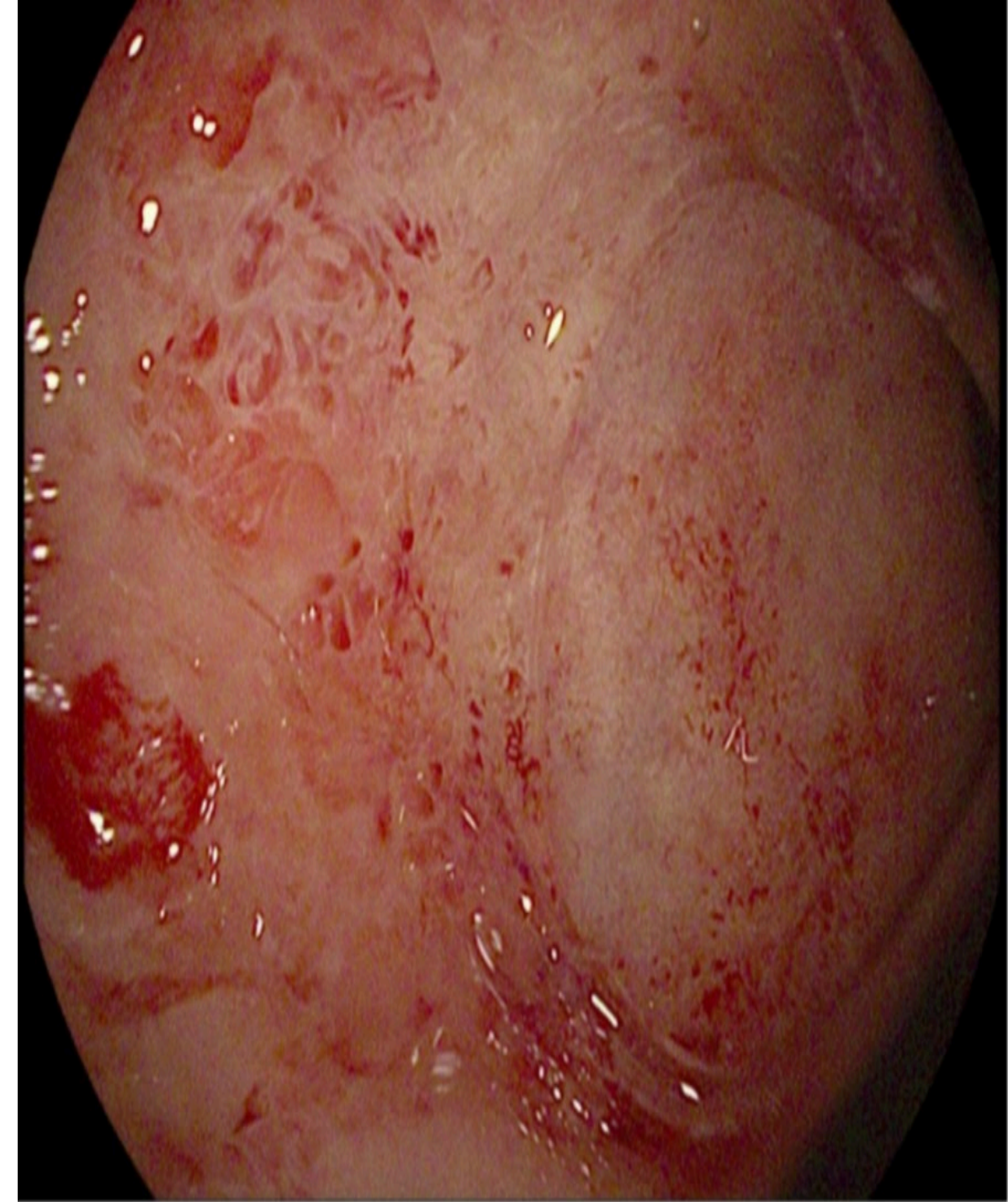Surgical options


A blue envelope-shaped icon with a white flap at the top. A blue circle with the number '3' is positioned on the flap. The text 'Surgical options' is centered in white. A white pill-shaped button is at the bottom.

Patient adimmitted

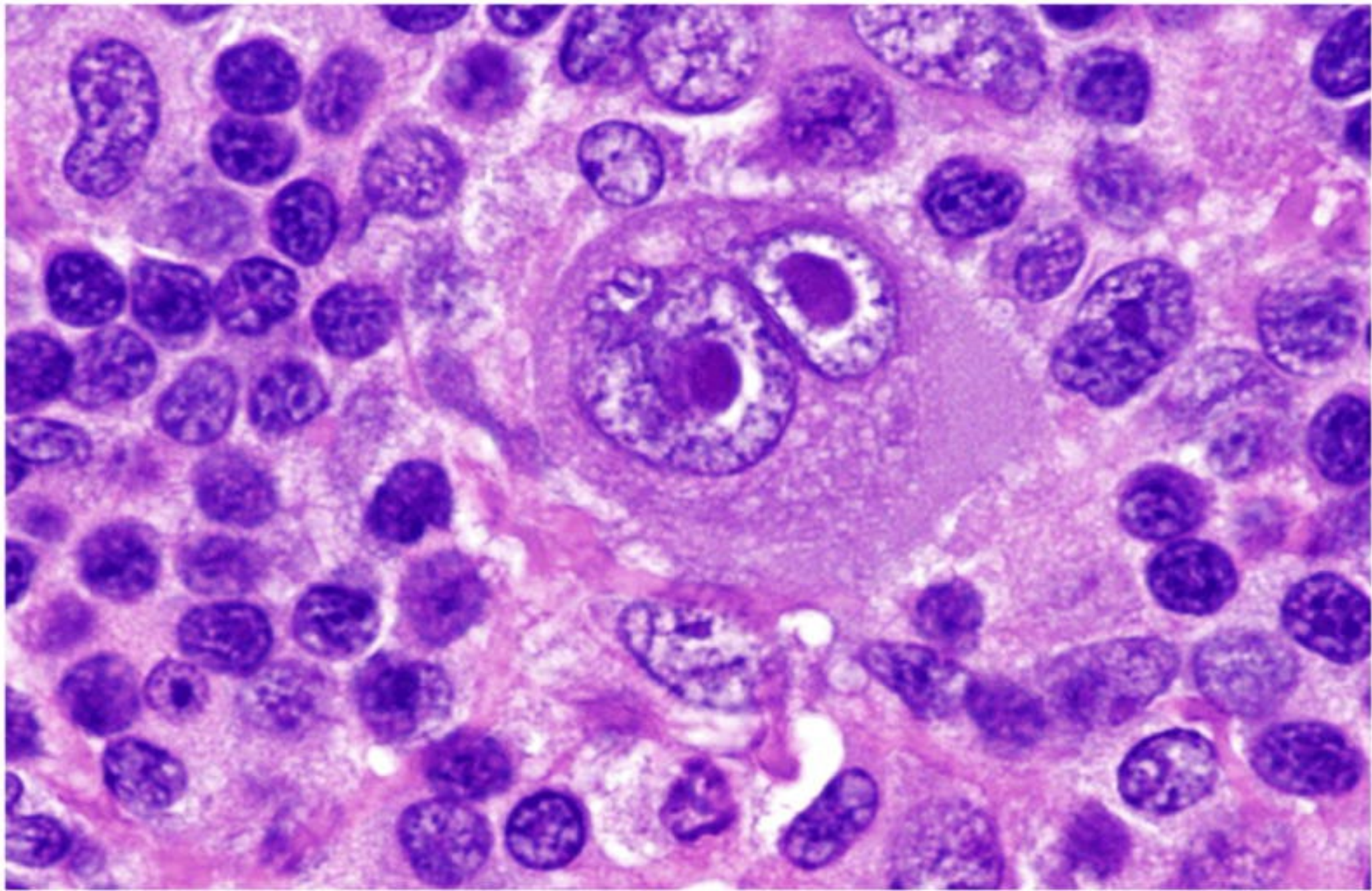


sigmoidscopy





Pathalogy
Owl eye inclusion bodies



DDX owl eye Inclusion bodies:

01

Cytomegalovirus (CMV)
infection

02

Herpes simplex virus (HSV)
infection

03

Varicella zoster virus (VZV)
infection

04

Adenovirus infection

05

Reed-sternberg cells in hodgkin's
lymphoma

Immunohistochemistry (IHC):



CMV positive

CMV Diagnostic challenges



CMV IgM serology



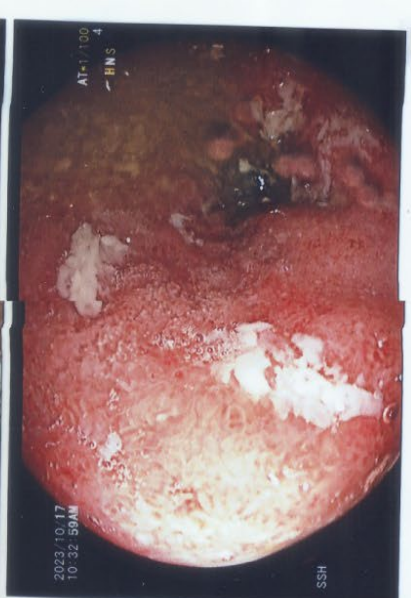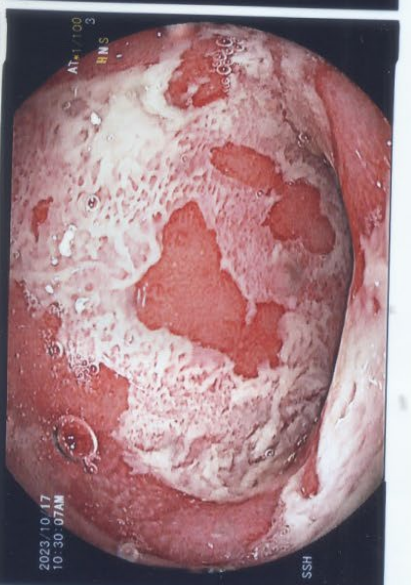
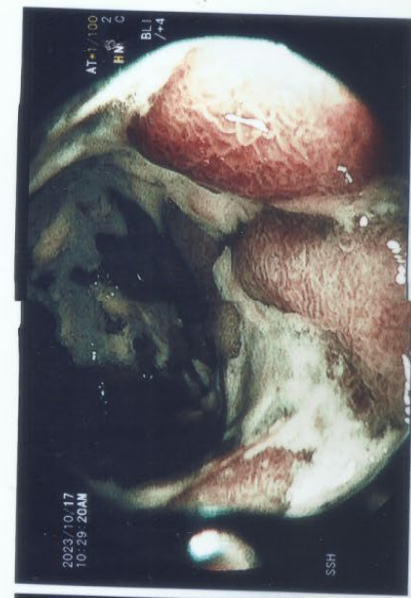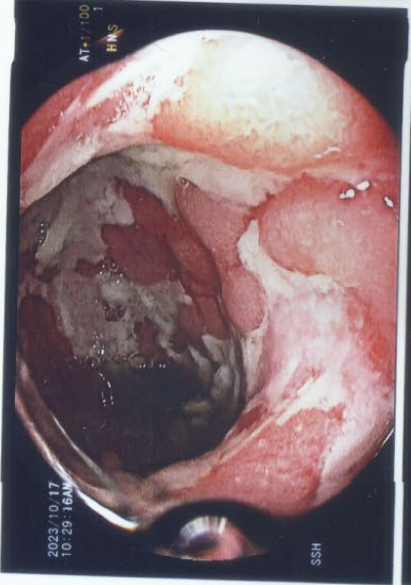

**Immunohistochemistry
(IHC)**



CMV PCR from tissue biopsy



CMV PCR from SERUM



Treatment




A

Antiviral


ECCO: ganciclovir IV 5mg/kg twice daily for 5-10day
valganciclovir po 900mg twice daily
2-3 weeks

BSG :ganciclovir IV 5mg/kg twice daily for 2 weeks

Treatment



Treatment



steroid

Treatment



Immunosuppressive



Ulcerative
colitis



Crohn's



Case Report | [Open access](#) | Published: 16 August 2024

A diagnostic dilemma: cytomegalovirus colitis as an uncommon comorbidity in inflammatory bowel disease: a case report

[Marouf Alhalabi](#)  & [Soumar Mueen Alziadan](#)

Virology Journal **21**, Article number: 188 (2024) | [Cite this article](#)

9142 Accesses | **1** Citations | [Metrics](#)



 Thank You 