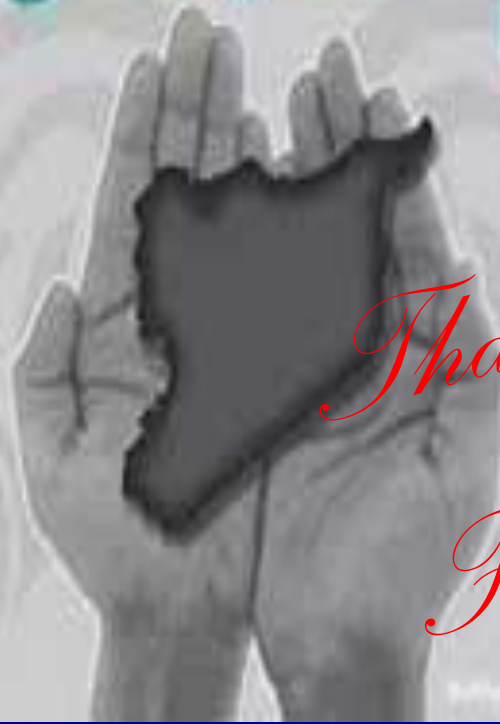



اللهم احفظ سورية واهل سورية



Thanks

Fayez



Post Sleeve Surgery Leak

Double Pigtail Plastic Stenting

“New Technique”

Fayez Sandouk

MD FRCP

*Chairman Young Clinicians Program in Africo Middleast
Association of Gastro-Enterology*

YCP in AMAGE

الدكتور فائز صندوق

**أخصائي الجهاز الهضمي
المستشفى السوري التخصصي**

دمشق - سوريا



Introduction-1



The management of Laparoscopic Sleeve Leak **“Remains A Challenge”**

As it might need:

- 1. Long Hospital Stay**
- 2. Require Different Interventions**
(Surgical, Radiological & Endoscopic)
- 3. Significant Morbidity and sometime Mortalities.**

Introduction-2

NO standard algorithm to follow

The management should be planned based on the:


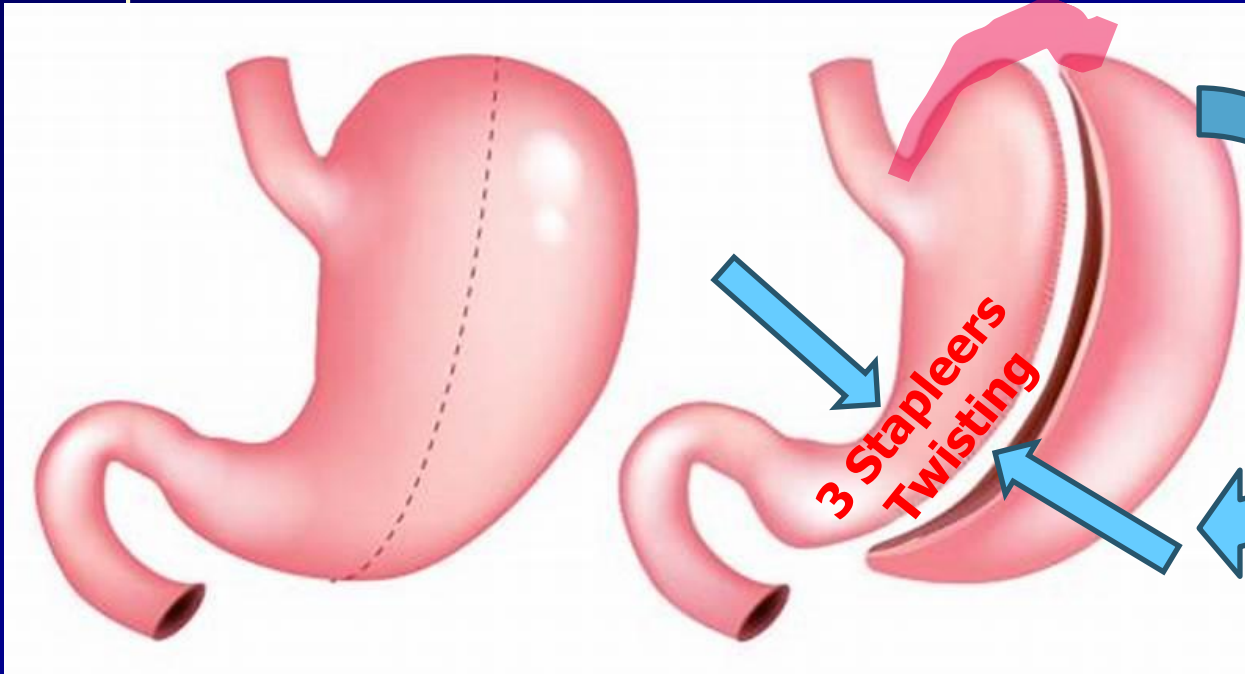
- (1) clinical evaluation,
- (2) time of diagnosis and finally,
- (3) the location of the leak.

Causes

(1) Mechanical

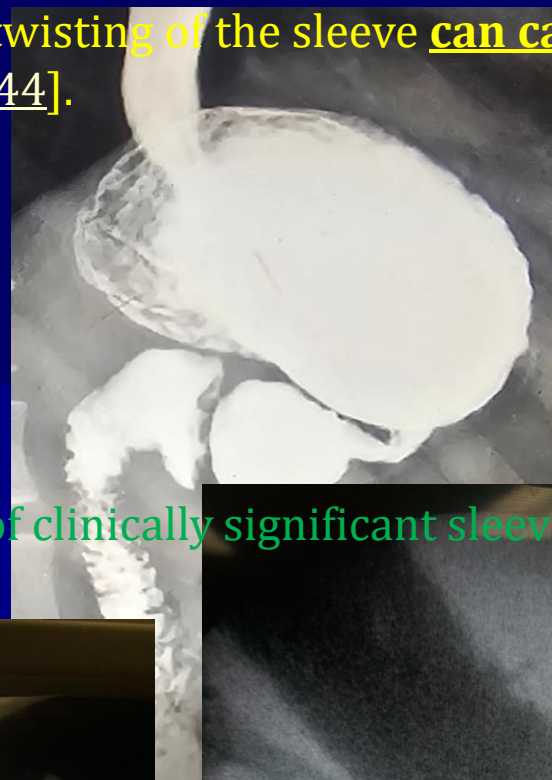
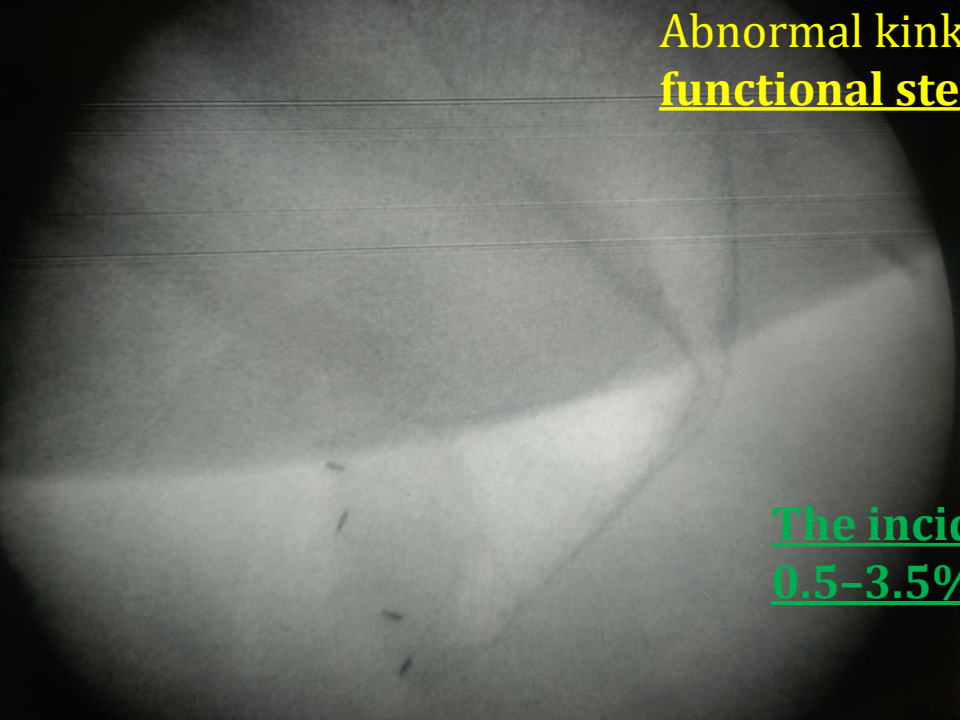(2) Technical and

(3) Ischemic causes.

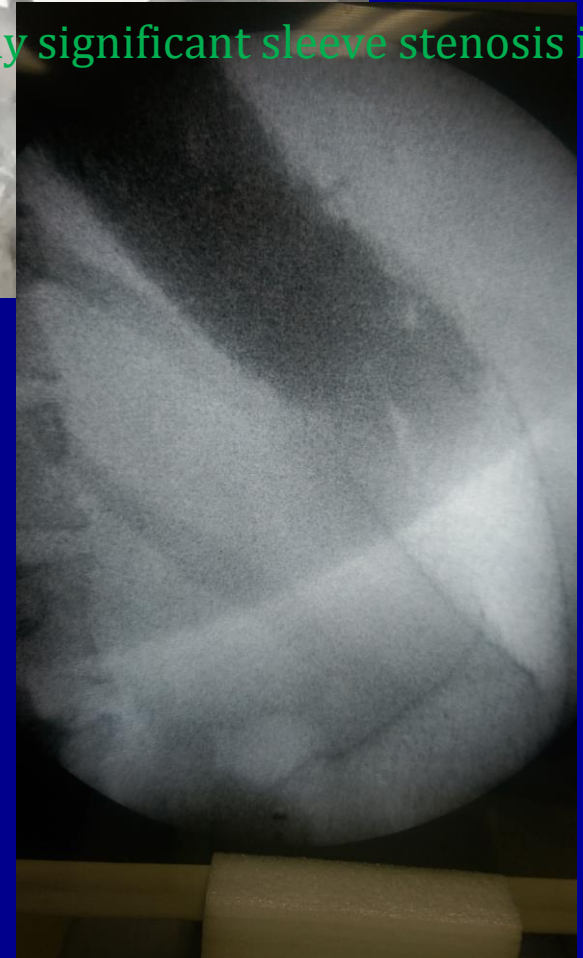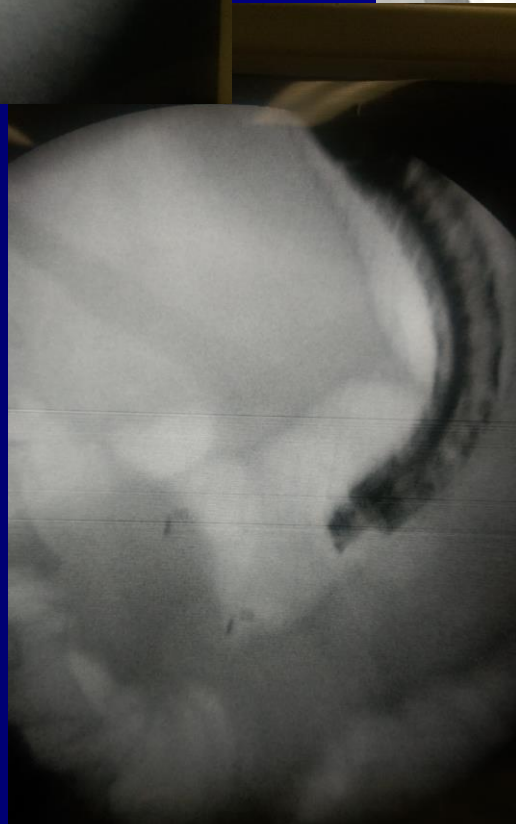


6 - 12 weeks

Abnormal kinking or twisting of the sleeve can cause functional stenosis [44].



The incidence of clinically significant sleeve stenosis is 0.5-3.5% [43]



Important Early Sign for Leak

Fever and tachycardia

which mandate the use of

CT + Oral Contrast

Or

Gastroscopy



Depends On



The choice of which management option to use is often made based on

- 1. Clinical Condition of the patient.**
- 2. Timing of diagnosis.**
- 3. Anastomotic level.**
- 4. Size of the defect.**



MODALITIES



1. Conservative & Surgical Drain
2. Over the scope Clips
3. Metallic Stents
4. Double pigtail Intraluminal Plastic Stenting

[A Comprehensive Review of Endoscopic Management of Sleeve Gastrectomy Leaks - PubMed \(nih.gov\)](#)



MODALITIES



1. Conservative & Surgical Drain

Managed conservatively with a combination of:

1. Antibiotics.
2. Adequate drainage, which is traditionally often external.
3. Nasogastric or **Jejunal Feeding Tubes** that bypass the site of anastomotic leakage and enable Enteral Nutrition , parenteral nutrition.



MODALITIES



2. Endo CLIPS

Efficacy & Safety

1. 1-2 clips
2. 86% Healed in a month time
3. **Complications:** Tears , Migration , Stenosis
Very rare to be used nowadays because the edges of the fistula are very inflamed & friable.

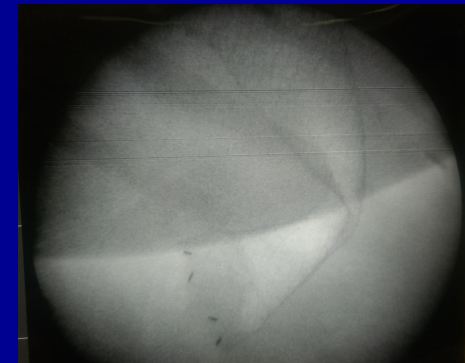
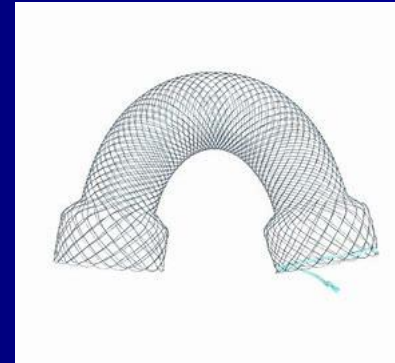
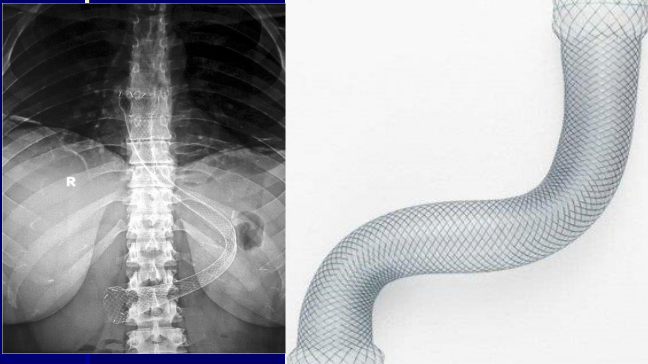
3. Metallic Stents

There are TWO main Types



A Mega stent MS

A Small Stent SS



1. Success rate of MS was 91% compared to only 50% for SS.
2. An average of 2.3 vs 6.8 endoscopies were required to achieve healing in the MS and SS.
3. Nutrition was shorter in the MS group (1.4 vs. 23.1 days, $p = 0.003$)

Only Esophago-duodenal Mega stent



3. Metallic Mega Stents

Only Esophago-duodenal Mega stent


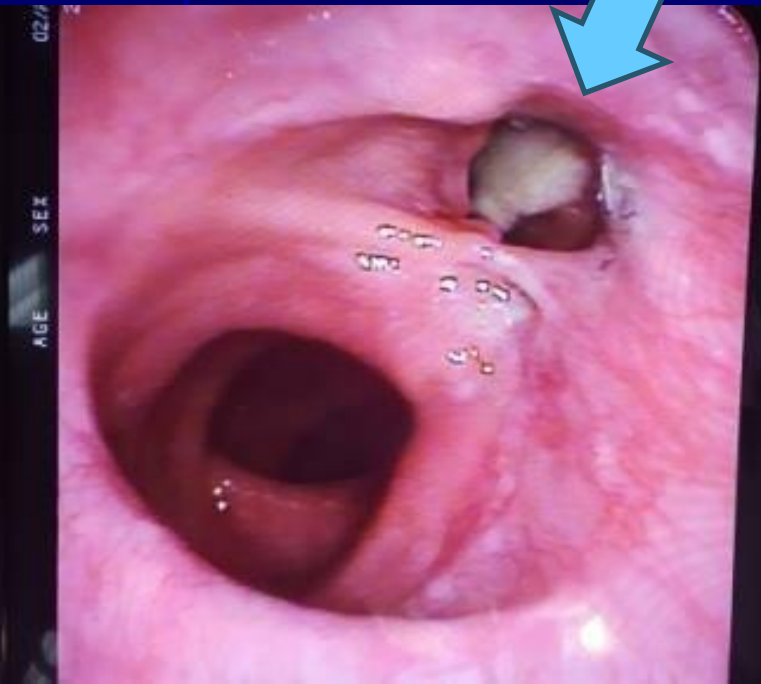


1. **100% Success Insertion**
2. **85.5 – 95% Clinical Success within 75 days**
3. **Complications:**
 - 33% Chest tightness
 - 43% Migration: Upper Endo-clip fixation
 - stent erosion into large vessels
 - Very Expensive



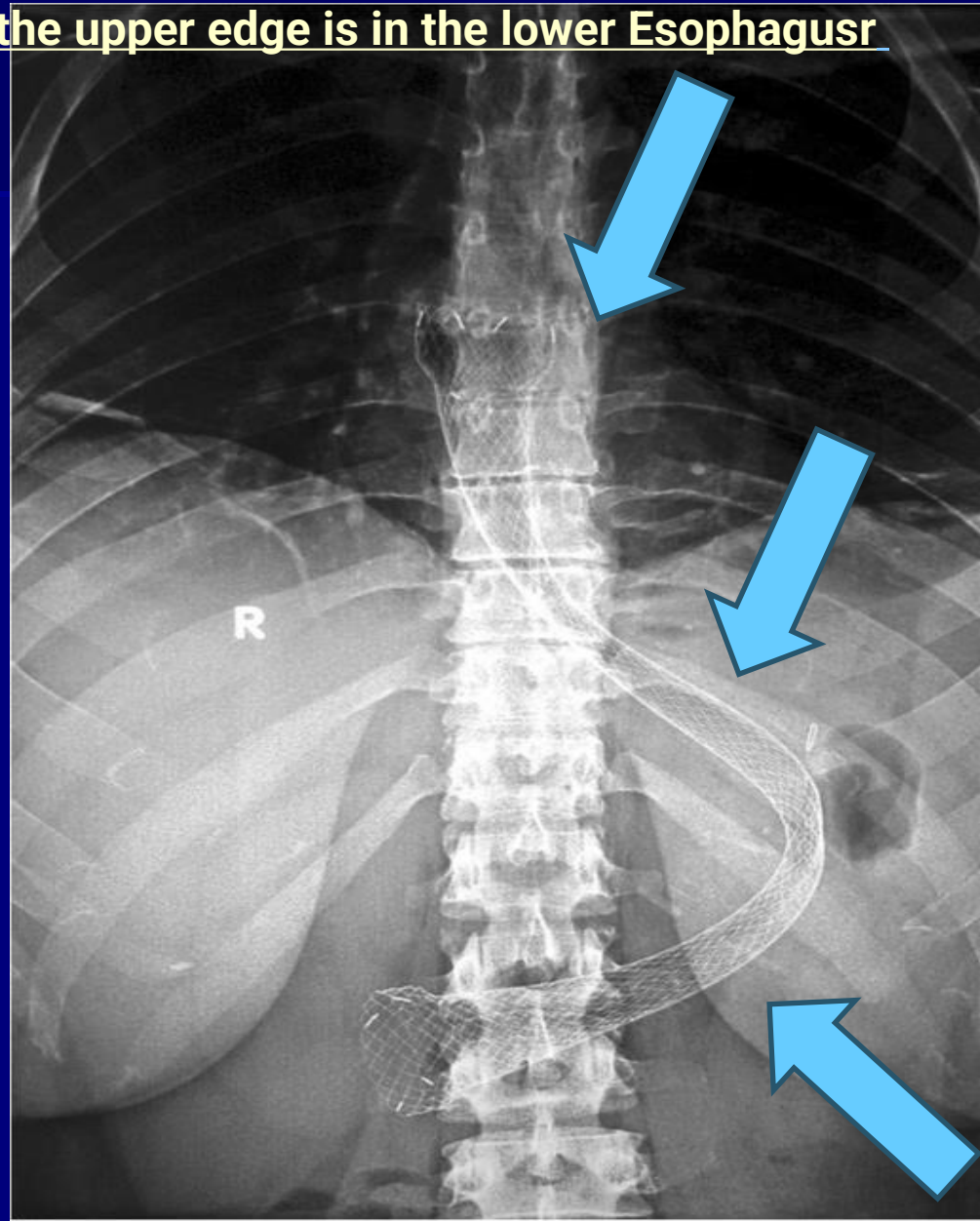

3. Metallic Mega Stents

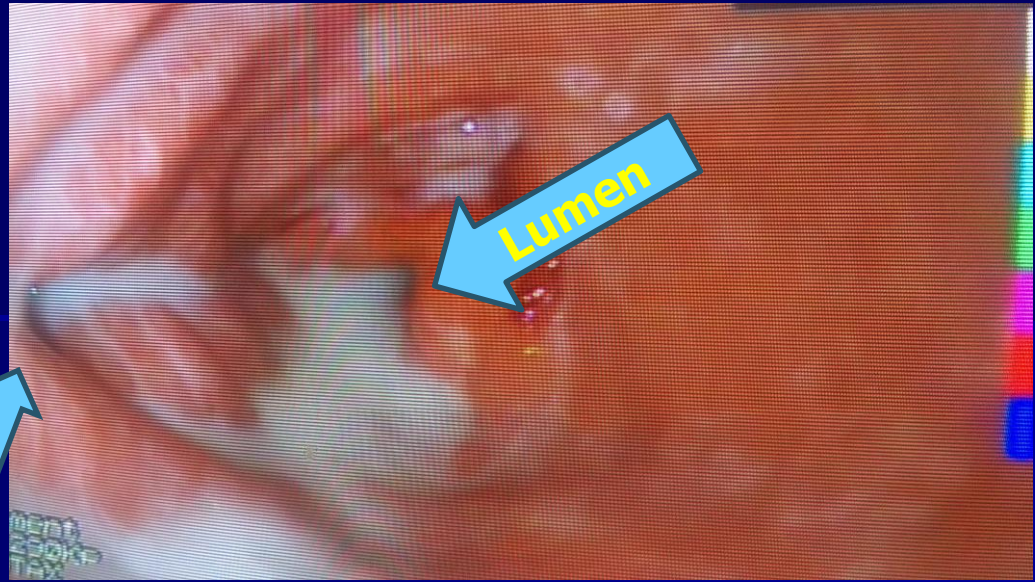
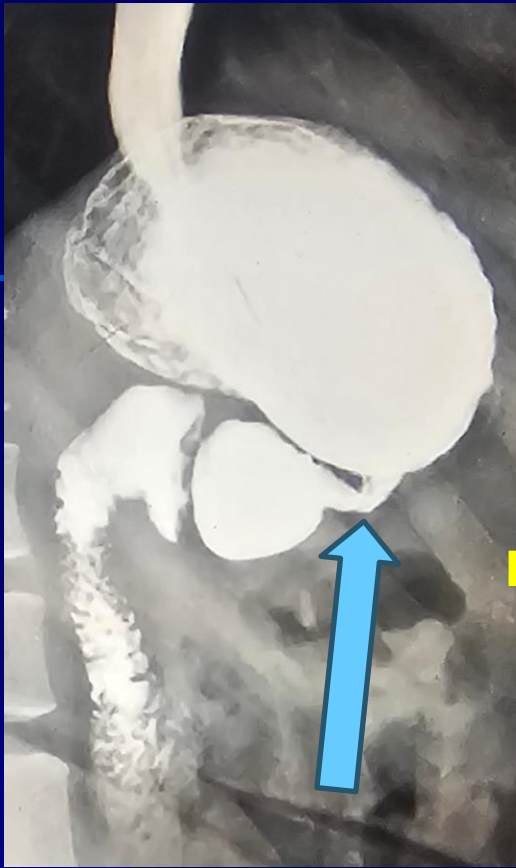Only Esophago-duodenal Mega stent



3. Metallic Mega Stents

A Mega stent in a gastric sleeve; the upper edge is in the lower Esophagus

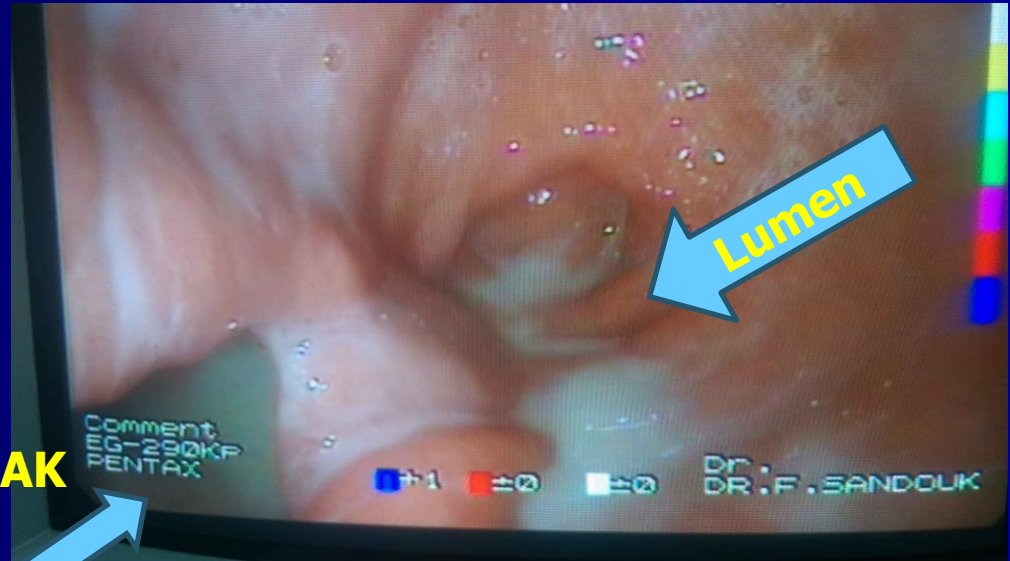



LEAK

Lumen

ساعة رملية



Wide Orifice LEAK

Lumen

Comment:
1001290KFP
TENTAX

■ ±1 ■ ±0 ■ ±0

DR: F. SANDOUK



MODALITIES



1. Surgical Drain
2. Over the scope Clip
3. Metallic Stents
4. Double pigtail Intraluminal Plastic Stenting

[A Comprehensive Review of Endoscopic Management of Sleeve Gastrectomy Leaks - PubMed \(nih.gov\)](#)



Double pigtail Intraluminal Plastic Stent



Endoscopic Internal Drain (EID)

Double-Pigtail Plastic Stents

is well known after many types of surgeries:

- Distal Esophagectomies
- Roux-en-Y gastric bypass
- Pancreatico-Duodenectomy
- LASTLY; Gastric Sleeve Leak



Endoluminal Placement to Facilitate Gastrointestinal Flow



1. Transmural double pigtail plastic stents (DPPS) for treatment of anastomotic leaks have shown high Clinical Success rates (>95%) **while being well-tolerated.**
2. Often combined with dilation of distal sleeve stenoses or kinks.
3. Fistula measures LESS than 1 cm.
4. Cost-effective.



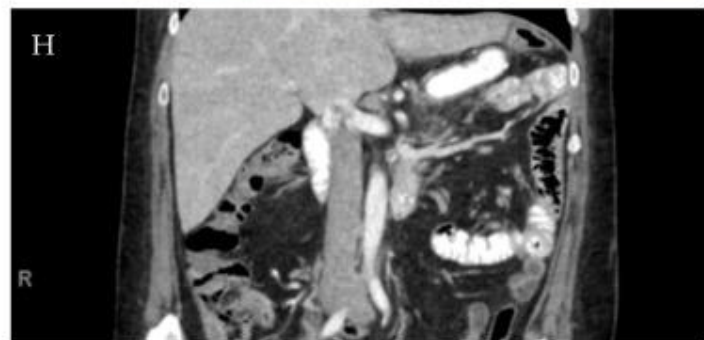
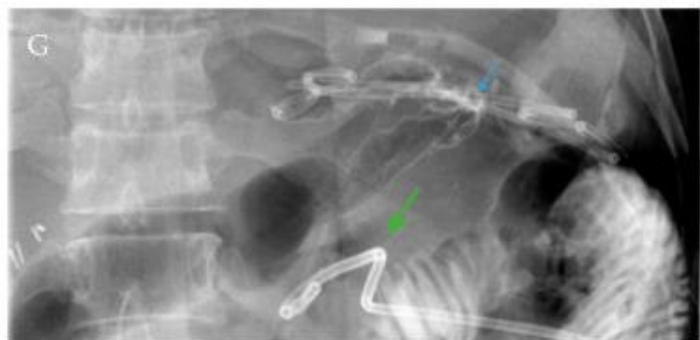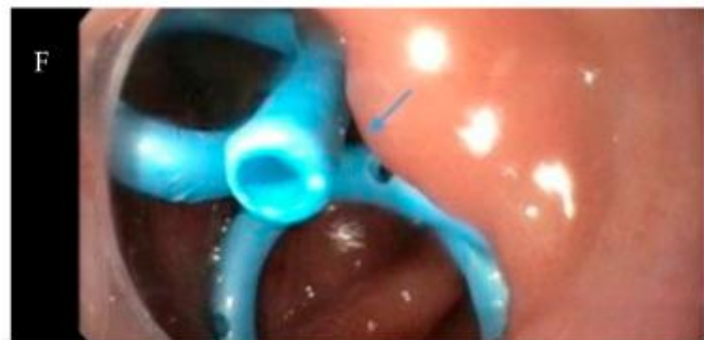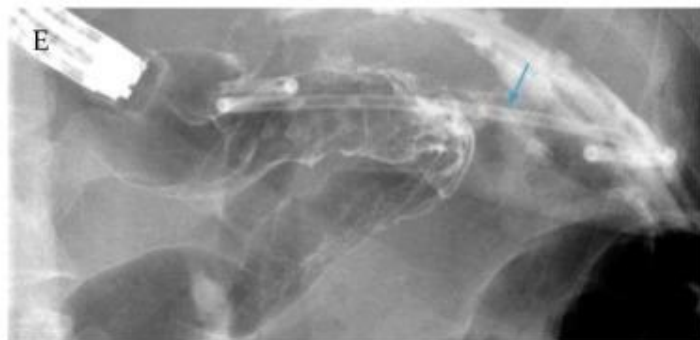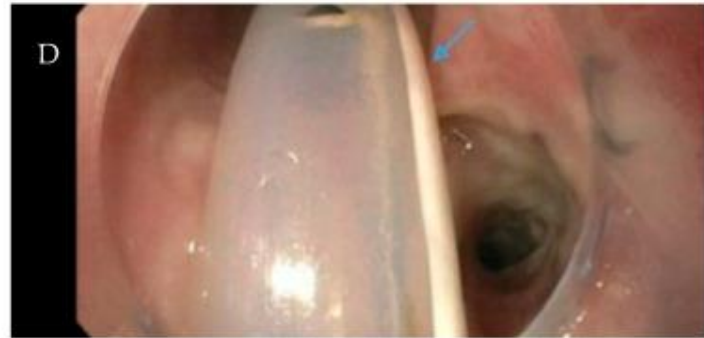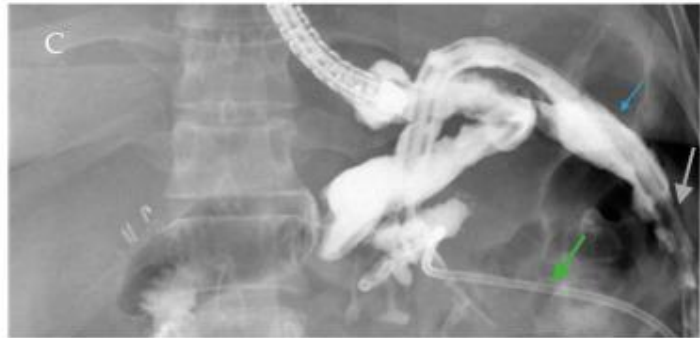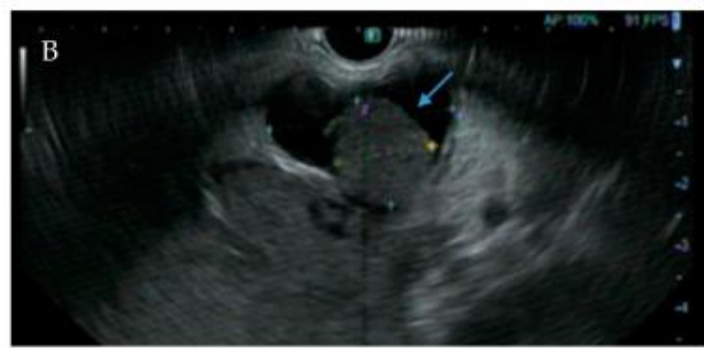
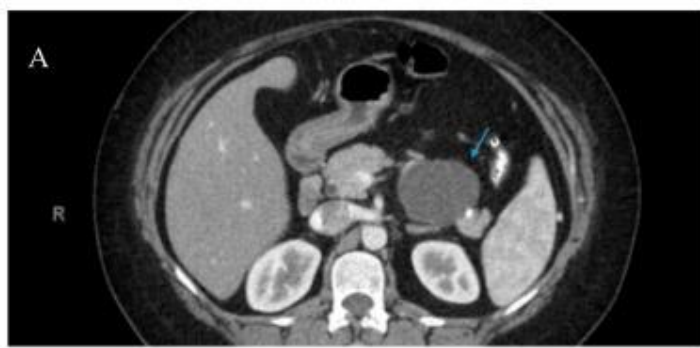- *Endoscopy*; 2016 Sep;48(9):809-16. doi: 10.1055/s-0042-108726. Epub 2016 Jun 17
- PMID: 32389513 , DOI: [10.1016/j.soard.2020.03.028](https://doi.org/10.1016/j.soard.2020.03.028)
- *The American Journal of Gastroenterology* 117(10S):p e1884, Octobe 2022. | DOI: [10.14309/01.ajg.0000868208.96826.64r](https://doi.org/10.14309/01.ajg.0000868208.96826.64r)

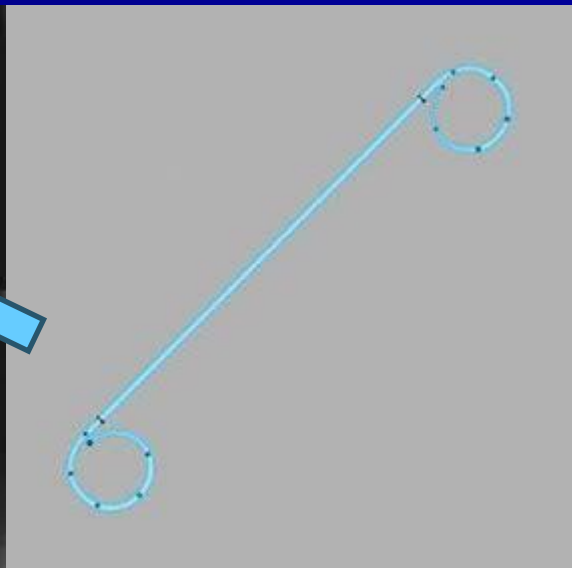
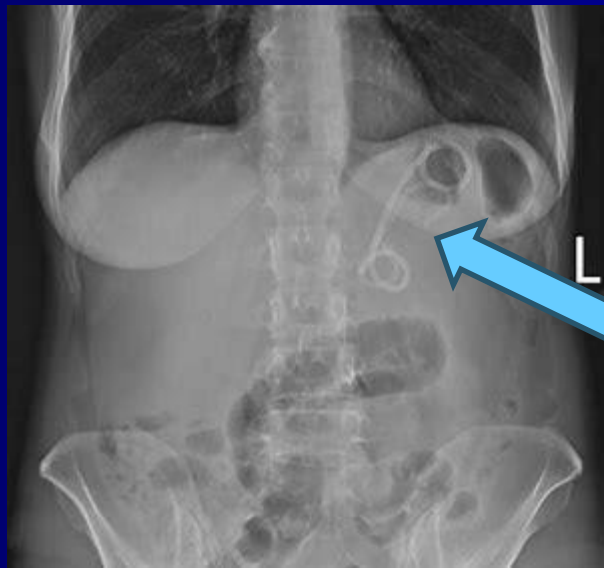
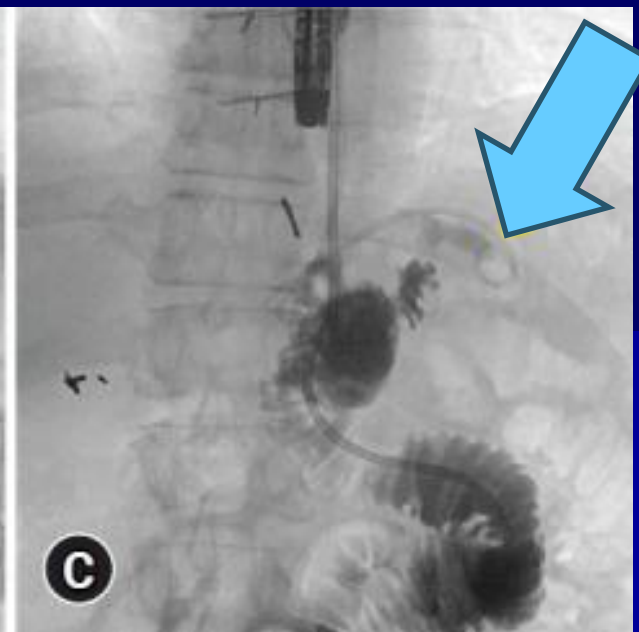
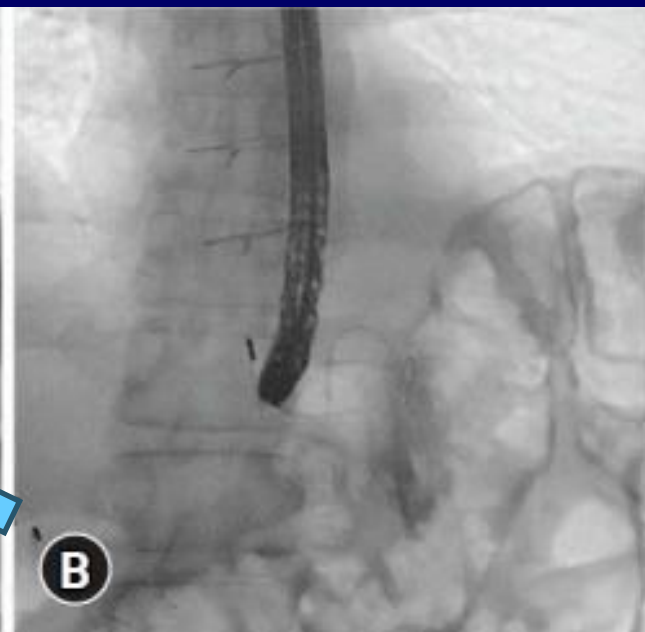
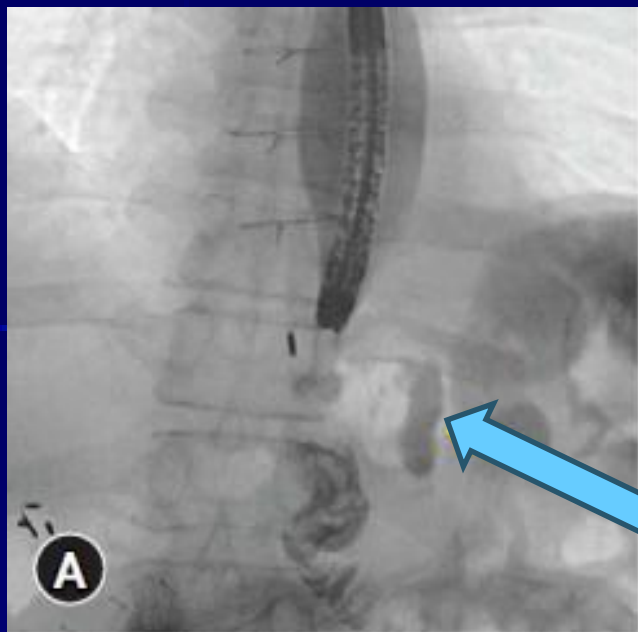


Endoluminal Placement to Facilitate Gastrointestinal Flow



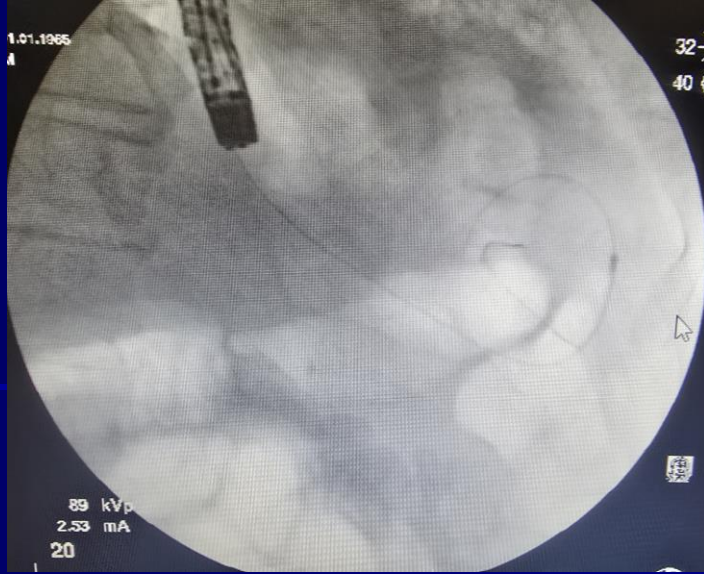
1. Technical success was achieved in **77.7-100 %**.
2. Required ≤ 3 endoscopic procedures **77.8 %**.
3. Median hospital stay after the first endoscopic procedure was **12 days** (IQR 6.5-17.5 days).
4. Median time until leak healing was **118.5 days** (IQR 84.5-170).





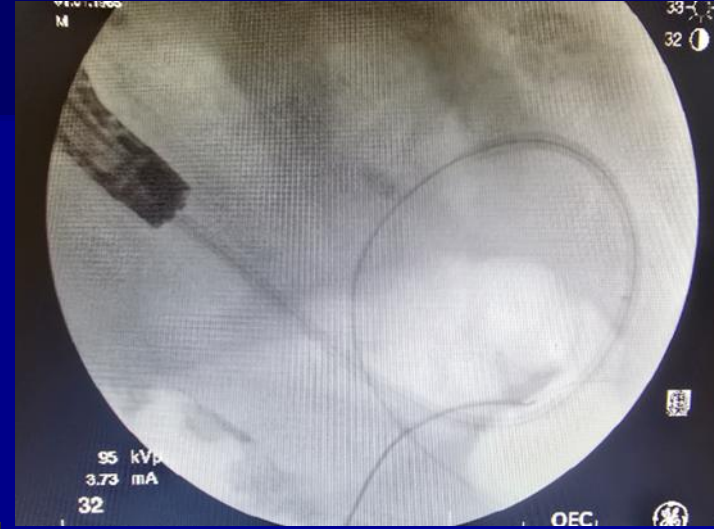1

2

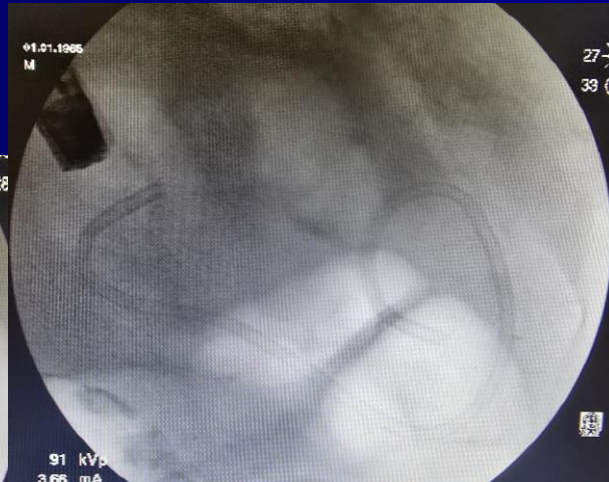
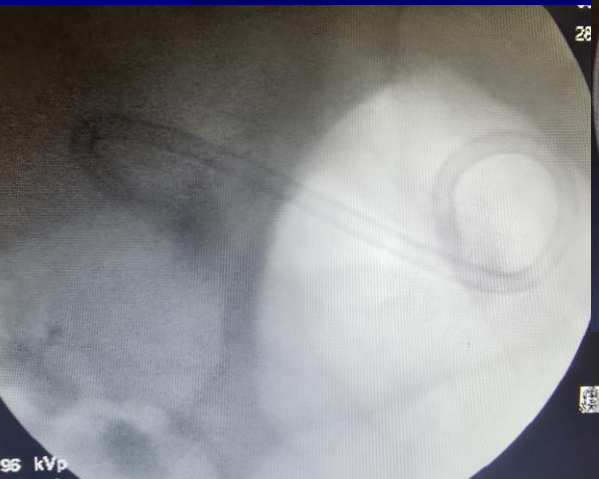


3

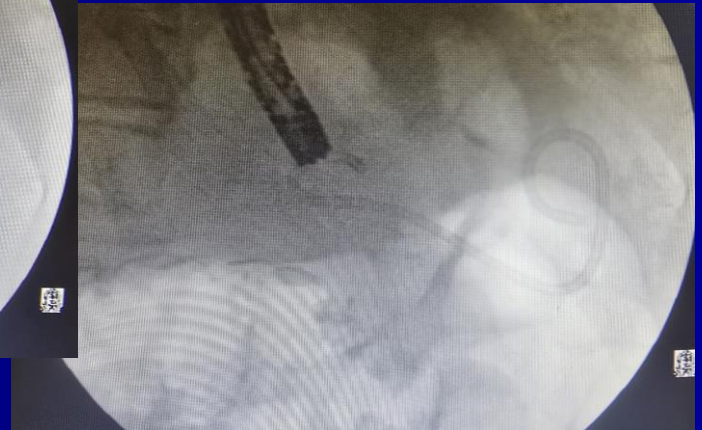
4



6



5





Endoscopic internal drainage (EID) double-pigtail stent

Conclusions



Increasingly used as an effective approach
after as it showed

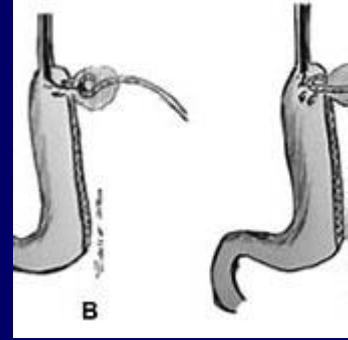
1. Required fewer procedures per patient.
2. Better tolerated.
3. Had lower morbidity-mortality compared to SEMS.
4. Allows for early oral nutritional feeding.
5. Minimizes discomfort from conventional external drainage.

• *Endoscopy*; 2016 Sep;48(9):809-16. doi: 10.1055/s-0042-108726. Epub 2016 Jun 17

• PMID: 32389513 , DOI: [10.1016/j.soard.2020.03.028](https://doi.org/10.1016/j.soard.2020.03.028)

• *The American Journal of Gastroenterology* 117(10S):p e1884, Octobe 2022. | DOI: [10.14309/01.ajg.0000868208.96826.64r](https://doi.org/10.14309/01.ajg.0000868208.96826.64r)

Endoscopic internal drainage (EID) double-pigtail stent Complications



1. Inner Migration
2. Deviation during the procedure due to tissue fibrosis,
3. Obstruction at the esophagogastric junction,
4. Fistula injury,
5. Micro perforation of ulcers
6. Damage to the perforated sites.
7. Rare Complication: post-esophagectomy intrathoracic leak developed a Esophageo-Tracheal fistula.

DOI: 10.5230/jgc.2024.24.e12

Publication: J Gastric Cancer. 2024 Jan; 24(1): 108-121.

Published: 2024/01

Limitation

- Morbidity is minimal for up to three months
- But longer indwelling times are associated with an increasing frequency of:
 1. Infections,
 2. Secondary stone formation and obstruction of the stented tract.

Lastly : Prevention

- *Number of preventive measures to decrease the leak rate:*
 1. Gentle handling of tissues,
 2. Staple line reinforcement,
 3. Larger bougie size and
 4. Routine use of methylene blue test per operatively.

References

1. Regan JP, Inabnet WB, Gagner M, Pomp A. Early experience with two-stage laparoscopic Roux-en-Y gastric bypass as an alternative in the super-super obese patient. *Obes Surg*. 2003;13:861–864. [[PubMed](#)] [[Google Scholar](#)]
2. Angrisani L, Santonicola A, Iovino P, Ramos A, Shikora S, Kow L. Bariatric surgery survey 2018: similarities and disparities among the 5 IFSO chapters. *Obes Surg*. 2021;31:1937–1948. [[PMC free article](#)] [[PubMed](#)] [[Google Scholar](#)]
3. Kumar SB, Hamilton BC, Wood SG, Rogers SJ, Carter JT, Lin MY. Is laparoscopic sleeve gastrectomy safer than laparoscopic gastric bypass? a comparison of 30-day complications using the MBSAQIP data registry. *Surg Obes Relat Dis*. 2018;14:264–269. [[PubMed](#)] [[Google Scholar](#)]
4. D'Ugo S, Gentileschi P, Benavoli D, Cerci M, Gaspari A, Berta RD, et al. Comparative use of different techniques for leak and bleeding prevention during laparoscopic sleeve gastrectomy: a multicenter study. *Surg Obes Relat Dis*. 2014;10:450–454. [[PubMed](#)] [[Google Scholar](#)]
5. Gagner M, Deitel M, Kalberer TL, Erickson AL, Crosby RD. The second international consensus summit for sleeve gastrectomy, March 19–21, 2009. *Surg Obes Relat Dis*. 2009;5:476–485. [[PubMed](#)] [[Google Scholar](#)]
6. Gagner M, Deitel M, Erickson AL, Crosby RD. Survey on laparoscopic sleeve gastrectomy (LSG) at the Fourth International Consensus Summit on Sleeve Gastrectomy. *Obes Surg*. 2013;23:2013–2017. [[PubMed](#)] [[Google Scholar](#)]
7. Sroka G, Milevski D, Shteinberg D, Mady H, Matter I. Minimizing hemorrhagic complications in laparoscopic sleeve gastrectomy--a randomized controlled trial. *Obes Surg*. 2015;25:1577–1583. [[PubMed](#)] [[Google Scholar](#)]
8. Chen YS, Loh EW, Shen SC, Su YH, Tam KW. Efficacy of fibrin sealant in reducing complication risk after bariatric surgery: a systematic review and meta-analysis. *Obes Surg*. 2021;31:1158–1167. [[PubMed](#)] [[Google Scholar](#)]
9. Çalıkoğlu İ, Hamzaoğlu H, Yerdel MA. Combined use of endoscopy to guide laparoscopic management of intraluminal bleeding from the staple-line after sleeve gastrectomy: a video case report. *Surg Obes Relat Dis*. 2020;16:1156–1157. [[PubMed](#)] [[Google Scholar](#)]
10. De Angelis F, Abdelgawad M, Rizzello M, Mattia C, Silecchia G. Perioperative hemorrhagic complications after laparoscopic sleeve gastrectomy: four-year experience of a bariatric center of excellence. *Surg Endosc*. 2017;31:3547–3551. [[PubMed](#)] [[Google Scholar](#)]
11. Aboueisha MA, Freeman M, Allotey JK, Evans L, Caposole MZ, Tatum D, et al. Battle of the buttress: 5-year propensity-matched analysis of staple-line reinforcement techniques from the MBSAQIP database. *Surg Endosc*. 2022 Forthcoming. [[PubMed](#)] [[Google Scholar](#)]

12. Gagner M, Hutchinson C, Senthil R. Fifth International Conference: current status of sleeve gastrectomy. *Surg Obes Relat Dis*. 2016;12:750–756. [[PubMed](#)] [[Google Scholar](#)]

13. Yeo E, Thompson J, Hanseman D, Dunki-Jacobs A, Thompson B, Goodman M, et al. Increased staple loading pressures and reduced staple heights in laparoscopic sleeve gastrectomy reduce intraoperative bleeding. *Surgery*. 2021;169:1110–1115. [[PMC free article](#)] [[PubMed](#)] [[Google Scholar](#)]

14. Nakayama S, Hasegawa S, Nagayama S, Kato S, Hida K, Tanaka E, et al. The importance of precompression time for secure stapling with a linear stapler. *Surg Endosc*. 2011;25:2382–2386. [[PubMed](#)] [[Google Scholar](#)]

15. Shah SS, Todkar JS, Shah PS. Buttressing the staple line: a randomized comparison between staple-line reinforcement versus no reinforcement during sleeve gastrectomy. *Obes Surg*. 2014;24:2014–2020. [[PMC free article](#)] [[PubMed](#)] [[Google Scholar](#)]

16. Gagner M, Kemmeter P. Comparison of laparoscopic sleeve gastrectomy leak rates in five staple-line reinforcement options: a systematic review. *Surg Endosc*. 2020;34:396–407. [[PMC free article](#)] [[PubMed](#)] [[Google Scholar](#)]

17. Rebibo L, Dhahri A, Chati R, Cosse C, Huet E, Regimbeau JM. Effectiveness of fibrin sealant application on the development of staple line complications after sleeve gastrectomy: a prospective randomized trial. *Ann Surg*. 2018;268:762–768. [[PubMed](#)] [[Google Scholar](#)]

18. Márquez MF, Ayza MF, Lozano RB, Morales MM, Díez JM, Poujoulet RB. Gastric leak after laparoscopic sleeve gastrectomy. *Obes Surg*. 2010;20:1306–1311. [[PubMed](#)] [[Google Scholar](#)]

19. Abou Rached A, Basile M, El Masri H. Gastric leaks post sleeve gastrectomy: review of its prevention and management. *World J Gastroenterol*. 2014;20:13904–13910. [[PMC free article](#)] [[PubMed](#)] [[Google Scholar](#)]

20. Baker RS, Foote J, Kemmeter P, Brady R, Vroegop T, Serveld M. The science of stapling and leaks. *Obes Surg*. 2004;14:1290–1298. [[PubMed](#)] [[Google Scholar](#)]

21. Parikh M, Issa R, McCrillis A, Saunders JK, Ude-Welcome A, Gagner M. Surgical strategies that may decrease leak after laparoscopic sleeve gastrectomy: a systematic review and meta-analysis of 9991 cases. *Ann Surg*. 2013;257:231–237. [[PubMed](#)] [[Google Scholar](#)]

22. Gjeorgjievski M, Imam Z, Cappell MS, Jamil LH, Kahaleh M. A comprehensive review of endoscopic management of sleeve gastrectomy leaks. *J Clin Gastroenterol*. 2021;55:551–576. [[PubMed](#)] [[Google Scholar](#)]

23. Brockmeyer JR, Simon TE, Jacob RK, Husain F, Choi Y. Upper gastrointestinal swallow study following bariatric surgery: institutional review and review of the literature. *Obes Surg*. 2012;22:1039–1043. [[PubMed](#)] [[Google Scholar](#)]

24. Chivot C, Rebibo L, Robert B, Dhahri A, Regimbeau JM, Yzet T. Value of routine upper gastrointestinal swallow study after laparoscopic sleeve gastrectomy. *Surg Obes Relat Dis*. 2017;13:758–765. [[PubMed](#)] [[Google Scholar](#)]

25. Musella M, Cantoni V, Green R, Acampa W, Velotti N, Maietta P, et al. Efficacy of postoperative upper gastrointestinal series (UGI) and computed tomography (CT) scan in bariatric surgery: a meta-analysis on 7516 patients. *Obes Surg.* 2018;28:2396–2405. [[PubMed](#)] [[Google Scholar](#)]

26. Alban EA, García CA, Ospina LM, Munevar HE. Imaging after bariatric surgery: when interpretation is a challenge, from normal to abnormal. *Obes Surg.* 2018;28:2923–2931. [[PubMed](#)] [[Google Scholar](#)]

27. Csendes A, Braghetto I, León P, Burgos AM. Management of leaks after laparoscopic sleeve gastrectomy in patients with obesity. *J Gastrointest Surg.* 2010;14:1343–1348. [[PubMed](#)] [[Google Scholar](#)]

28. Rosenthal RJ, Diaz AA, Arvidsson D, Baker RS, Basso N, Bellanger D, et al. International Sleeve Gastrectomy Expert Panel Consensus Statement: best practice guidelines based on experience of >12,000 cases. *Surg Obes Relat Dis.* 2012;8:8–19. [[PubMed](#)] [[Google Scholar](#)]

29. Johari Y, Catchlove W, Tse M, Shaw K, Paul E, Chen R, et al. A 4-tier protocolized radiological classification system for leaks following sleeve gastrectomy. *Ann Surg.* 2022;275:e401–e409. [[PubMed](#)] [[Google Scholar](#)]

30. Burgos AM, Braghetto I, Csendes A, Maluenda F, Korn O, Yarmuch J, et al. Gastric leak after laparoscopic-sleeve gastrectomy for obesity. *Obes Surg.* 2009;19:1672–1677. [[PubMed](#)] [[Google Scholar](#)]

31. Shehab H, Abdallah E, Gawdat K, Elattar I. Large bariatric-specific stents and over-the-scope clips in the management of post-bariatric surgery leaks. *Obes Surg.* 2018;28:15–24. [[PubMed](#)] [[Google Scholar](#)]

32. Shehab H. Enteral stents in the management of post-bariatric surgery leaks. *Surg Obes Relat Dis.* 2018;14:393–403. [[PubMed](#)] [[Google Scholar](#)]

33. Fishman S, Shnell M, Gluck N, Meirsdorf S, Abu-Abeid S, Santo E. Use of sleeve-customized self-expandable metal stents for the treatment of staple-line leakage after laparoscopic sleeve gastrectomy. *Gastrointest Endosc.* 2015;81:1291–1294. [[PubMed](#)] [[Google Scholar](#)]

34. Tringali A, Bove V, Perri V, Landi R, Familiari P, Boškoski I, et al. Endoscopic treatment of post-laparoscopic sleeve gastrectomy leaks using a specifically designed metal stent. *Endoscopy.* 2017;49:64–68. [[PubMed](#)] [[Google Scholar](#)]

35. Billmann F, Pfeiffer A, Sauer P, Billeter A, Rupp C, Koschny R, et al. Endoscopic stent placement can successfully treat gastric leak following laparoscopic sleeve gastrectomy if and only if an esophagoduodenal megastent is used. *Obes Surg.* 2022;32:64–73. [[PMC free article](#)] [[PubMed](#)] [[Google Scholar](#)]

36. Shoar S, Poliakin L, Khorgami Z, Rubenstein R, El-Matbouly M, Levin JL, et al. Efficacy and safety of the over-the-scope clip (OTSC) system in the management of leak and fistula after laparoscopic sleeve gastrectomy: a systematic review. *Obes Surg.* 2017;27:2410–2418. [[PubMed](#)] [[Google Scholar](#)]

37. Mizrahi I, Grinbaum R, Elazary R, Mordechay-Heyn T, Kahahna N, Epshtein J, et al. Staple line leaks following laparoscopic sleeve gastrectomy: low efficacy of the over-the-scope clip. *Obes Surg.* 2021;31:813–819. [[PubMed](#)] [[Google Scholar](#)]

38. Assalia A, Ilivitzki A, Ofer A, Suissa A, Manassa E, Khamaysi I, et al. Management of gastric fistula complicating laparoscopic sleeve gastrectomy with biological glue in a combined percutaneous and endoscopic approach. *Surg Obes Relat Dis*. 2018;14:1093–1098. [[PubMed](#)] [[Google Scholar](#)]
39. Siddique I, Alazmi W, Al-Sabah SK. Endoscopic internal drainage by double pigtail stents in the management of laparoscopic sleeve gastrectomy leaks. *Surg Obes Relat Dis*. 2020;16:831–838. [[PubMed](#)] [[Google Scholar](#)]
40. Donatelli G, Dumont JL, Cereatti F, Ferretti S, Vergeau BM, Tuszynski T, et al. Treatment of leaks following sleeve gastrectomy by endoscopic internal drainage (EID) *Obes Surg*. 2015;25:1293–1301. [[PubMed](#)] [[Google Scholar](#)]
41. Giuliani A, Romano L, Marchese M, Necozone S, Cianca G, Schietroma M, et al. Gastric leak after laparoscopic sleeve gastrectomy: management with endoscopic double pigtail drainage. A systematic review. *Surg Obes Relat Dis*. 2019;15:1414–1419. [[PubMed](#)] [[Google Scholar](#)]
42. Archid R, Wichmann D, Klingert W, Nadiradze G, Hönes F, Archid N, et al. Endoscopic vacuum therapy for staple line leaks after sleeve gastrectomy. *Obes Surg*. 2020;30:1310–1315. [[PubMed](#)] [[Google Scholar](#)]
43. Rebibo L, Hakim S, Dhahri A, Yzet T, Delcenserie R, Regimbeau JM. Gastric stenosis after laparoscopic sleeve gastrectomy: diagnosis and management. *Obes Surg*. 2016;26:995–1001. [[PubMed](#)] [[Google Scholar](#)]
44. Contival N, Gautier T, Le Roux Y, Alves A. Stenosis without stricture after sleeve gastrectomy. *J Visc Surg*. 2015;152:339–341. [[PubMed](#)] [[Google Scholar](#)]
45. Shnell M, Nevo N, Lahat G, Abu-Abeid S, Goldstein AL, Fishman S, et al. Endoscopic management of sleeve stenosis. *Obes Surg*. 2021;31:4749–4753. [[PubMed](#)] [[Google Scholar](#)]
46. Deslauriers V, Beauchamp A, Garofalo F, Atlas H, Denis R, Garneau P, et al. Endoscopic management of post-laparoscopic sleeve gastrectomy stenosis. *Surg Endosc*. 2018;32:601–609. [[PubMed](#)] [[Google Scholar](#)]
47. Hassan MI, Khalifa MS, Elsayed MA, ElGhamrini YM. Role of endoscopic stent insertion on management of gastric twist after sleeve gastrectomy. *Obes Surg*. 2020;30:2877–2882. [[PubMed](#)] [[Google Scholar](#)]
48. Parikh A, Alley JB, Peterson RM, Harnisch MC, Pfluke JM, Tapper DM, et al. Management options for symptomatic stenosis after laparoscopic vertical sleeve gastrectomy in the morbidly obese. *Surg Endosc*. 2012;26:738–746. [[PubMed](#)] [[Google Scholar](#)]
49. Villagrán R, Smith G, Rodriguez W, Flores C, Cariaga M, Araya S, et al. Portomesenteric vein thrombosis after laparoscopic sleeve gastrectomy: incidence, analysis and follow-up in 1236 consecutive cases. *Obes Surg*. 2016;26:2555–2561. [[PMC free article](#)] [[PubMed](#)] [[Google Scholar](#)]
50. Goitein D, Matter I, Raziell A, Keidar A, Hazzan D, Rimon U, et al. Portomesenteric thrombosis following laparoscopic bariatric surgery: incidence, patterns of clinical presentation, and etiology in a bariatric patient population. *JAMA Surg*. 2013;148:340–346. [[PubMed](#)] [[Google Scholar](#)]

51. Tan SB, Greenslade J, Martin D, Talbot M, Loi K, Hopkins G. Portomesenteric vein thrombosis in sleeve gastrectomy: a 10-year review. *Surg Obes Relat Dis.* 2018;14:271–275. [[PubMed](#)] [[Google Scholar](#)]

52. AlSabah SA, AlRuwaished M, Almazeedi S, Al Haddad E, Chouillard E. Portomesenteric vein thrombosis post-laparoscopic sleeve gastrectomy: case series and literature review. *Obes Surg.* 2017;27:2360–2369. [[PubMed](#)] [[Google Scholar](#)]

53. Karaman K, Aziret M, Bal A, Öter V, Ercan M, Bostancı EB. Porto-mesenteric venous thrombosis after laparoscopic sleeve gastrectomy: a case report and systematic review of the 104 cases. *Obes Res Clin Pract.* 2018;12:317–325. [[PubMed](#)] [[Google Scholar](#)]

Team Work



WISDOM OF THE DAY



Management Lesson


Never start a project unless all resources are available

لا تبدأ المشروع إلا إذا توفرت جميع الموارد



شكراً
فائز

Fayez



مجرد ورقة وقعت على الأرض
فصنعت أجمل ابتسامة
Just a leave , fell on ground
And makes the most beautiful smile

- CAT SALAM