

# أورام الكولون نظرة حديثة

## ENHANCED ENDOSCOPY IMAGE

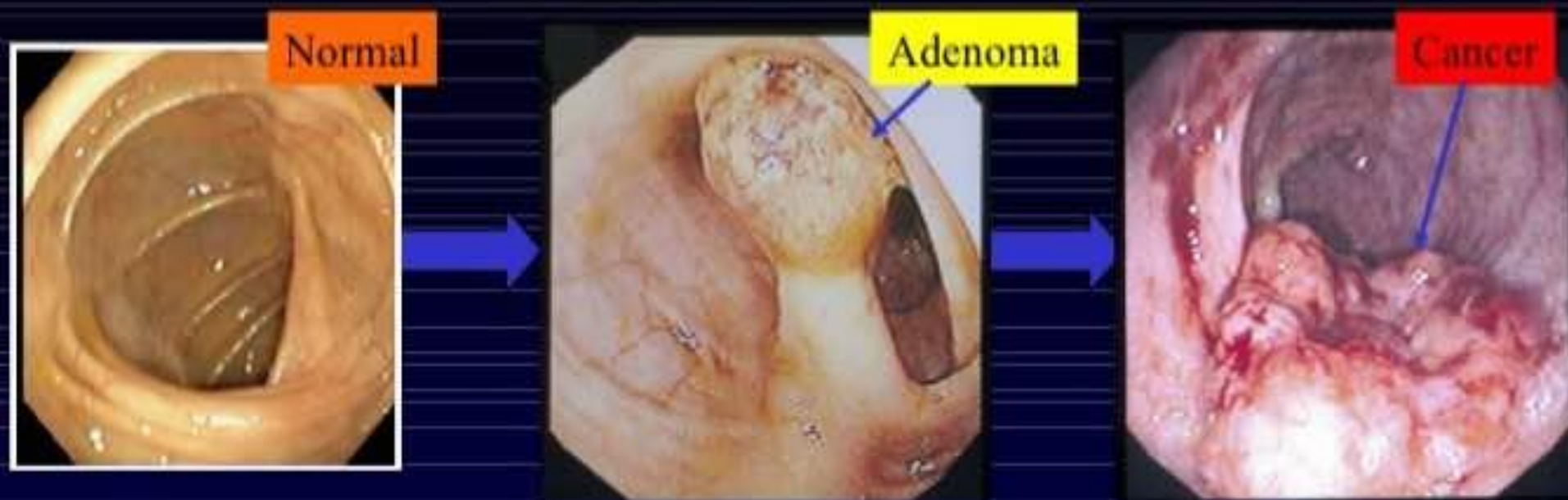د. ناصر عدي  
مستشفى الأسد الجامعي

# INTRODUCTION

- 2<sup>nd</sup> commonest cancer in men and ranks 3<sup>rd</sup> in frequency in women in the western countries
- 2<sup>nd</sup> m/c cause of cancer mortality (after Ca Lung)
- Globally 800,000 new CRCs occur each year, accounting for 10% of all incident cancers with 450,000 deaths/year
- About 75-80% present with localized disease
- Incidence : 35.8/100,000 (USA)
- Developing countries < 10/100,000
- India: incidence - 7/1,00,000
- Median age of diagnosis- 62 yrs
- Unfavorable prognosis if age <40 yrs

*SOURCE: RRCR 2007*

# Adenoma to Carcinoma Pathway



Normal

Adenoma

Cancer

APC  
loss

K-ras  
mutation

Chrom 18  
loss

p53  
loss

Normal  
Epithelium

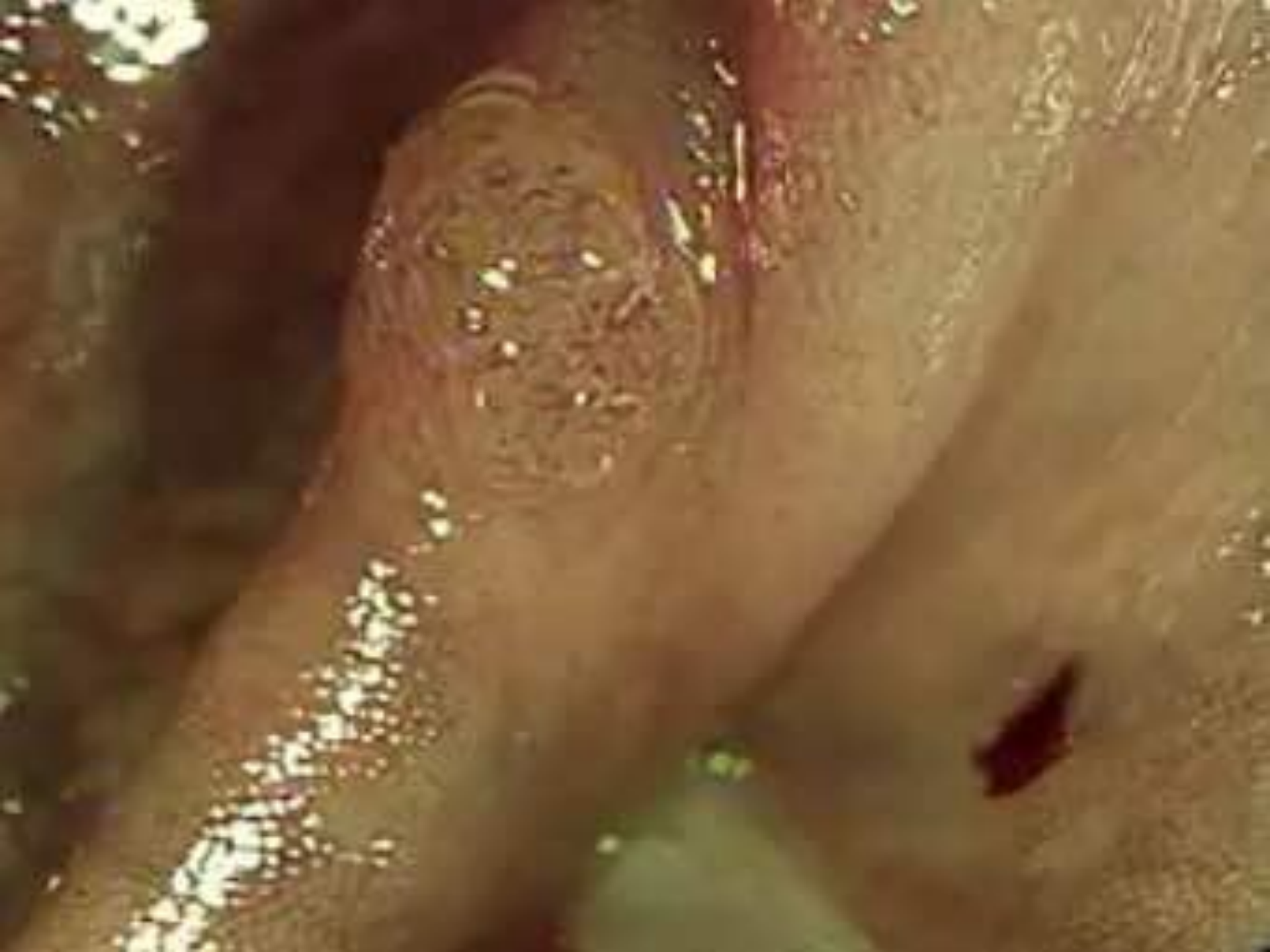Hyper-  
proliferation

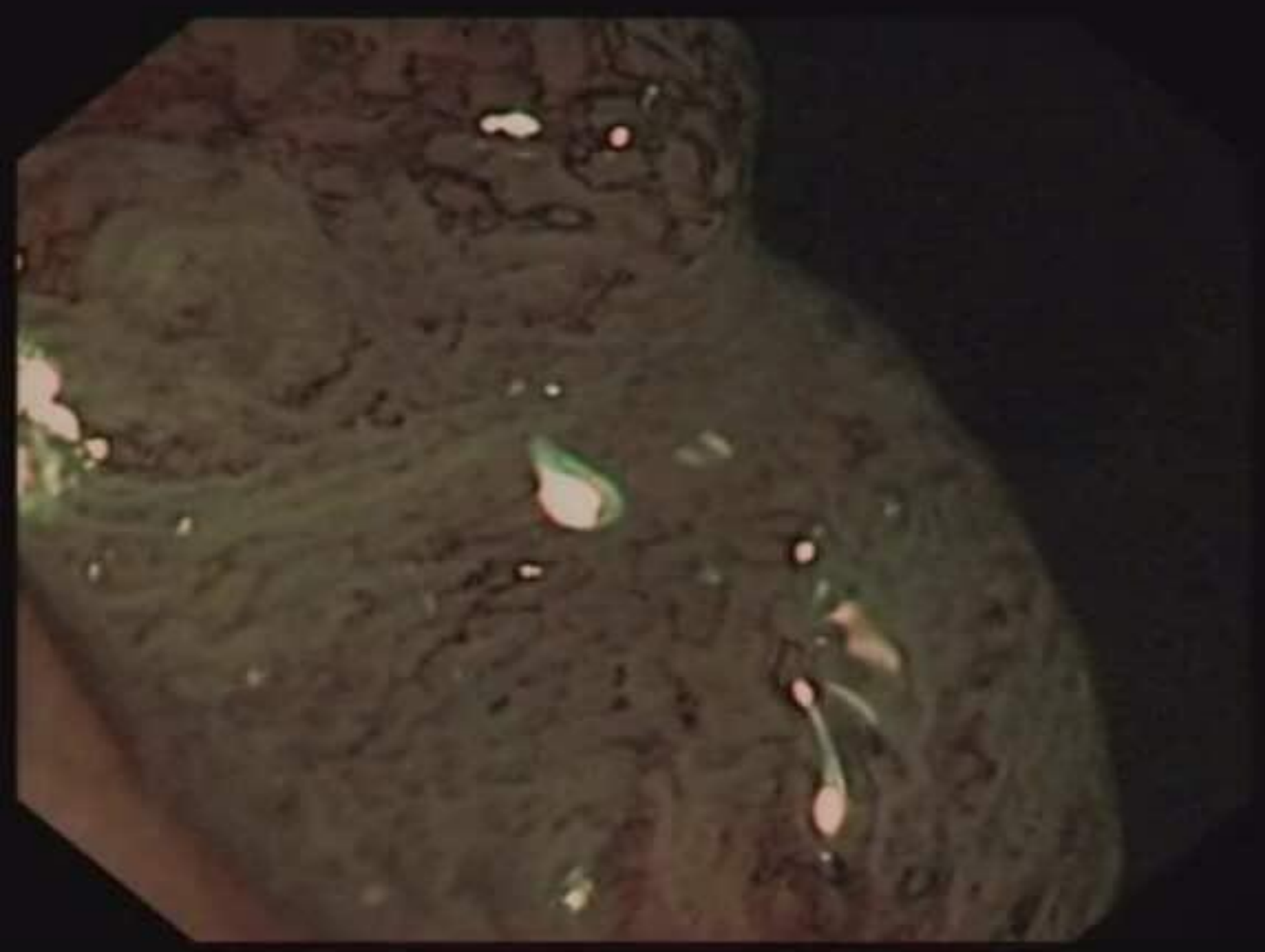Early  
Adenoma

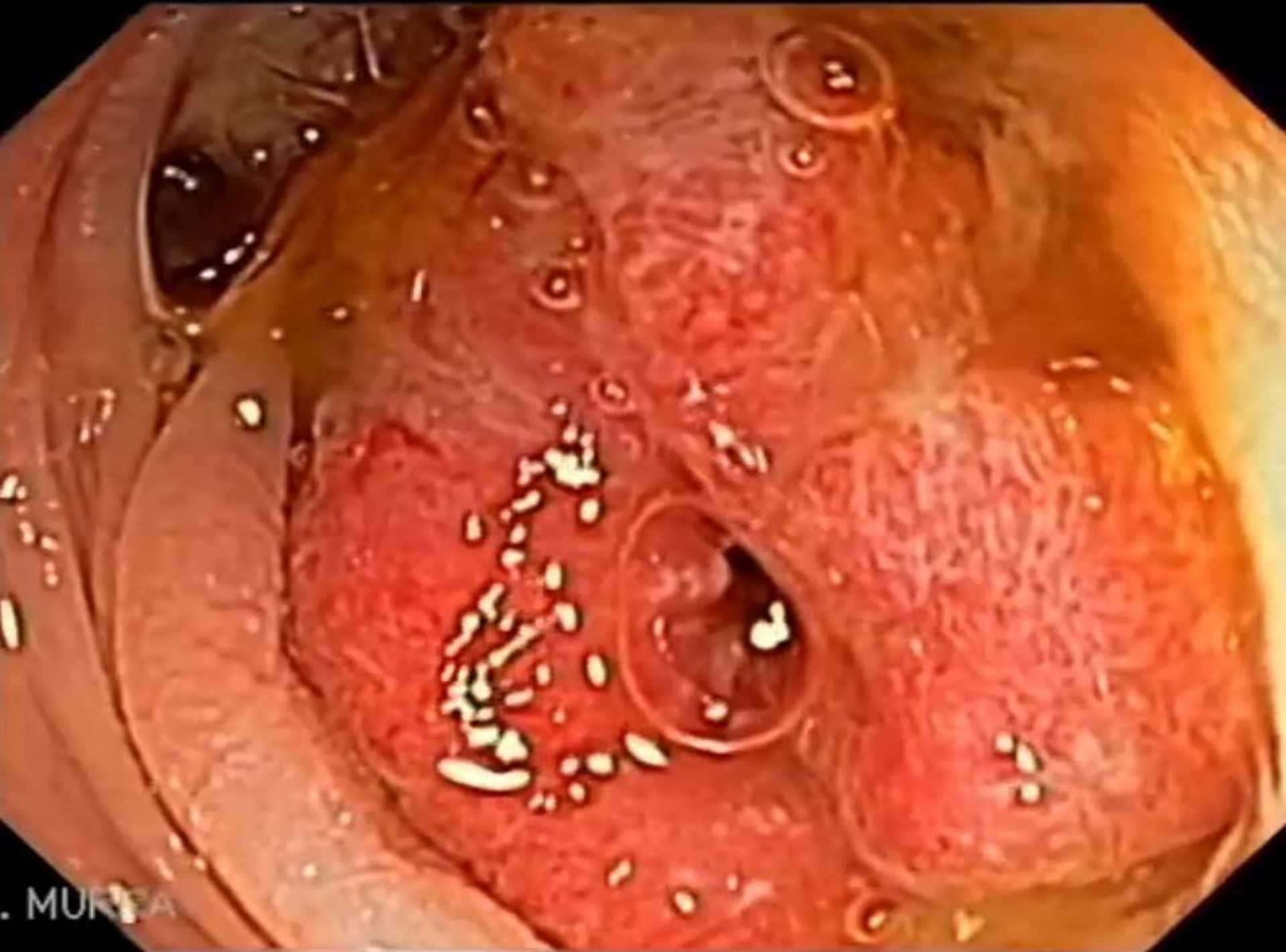
Intermediate  
Adenoma

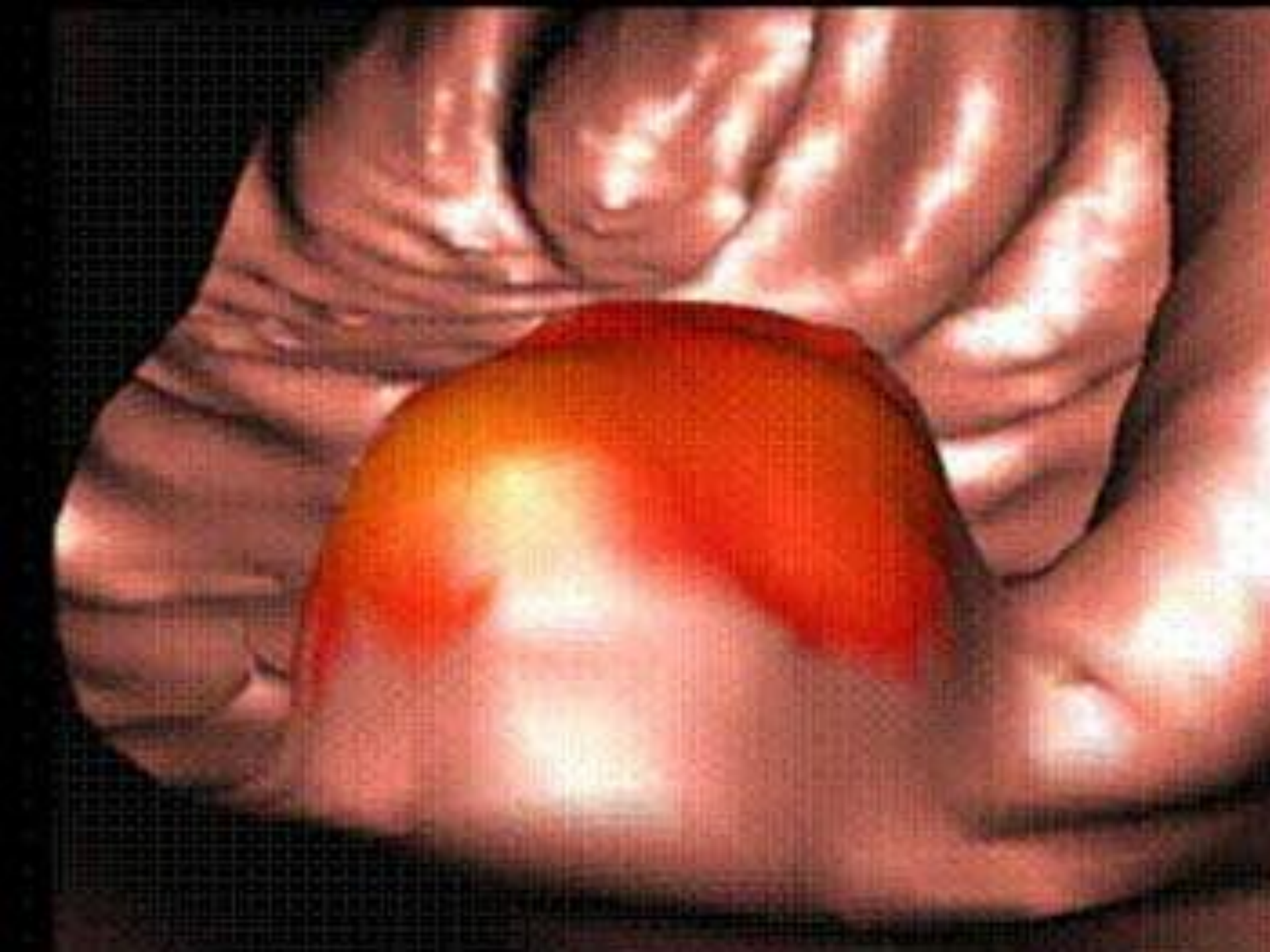
Late  
Adenoma

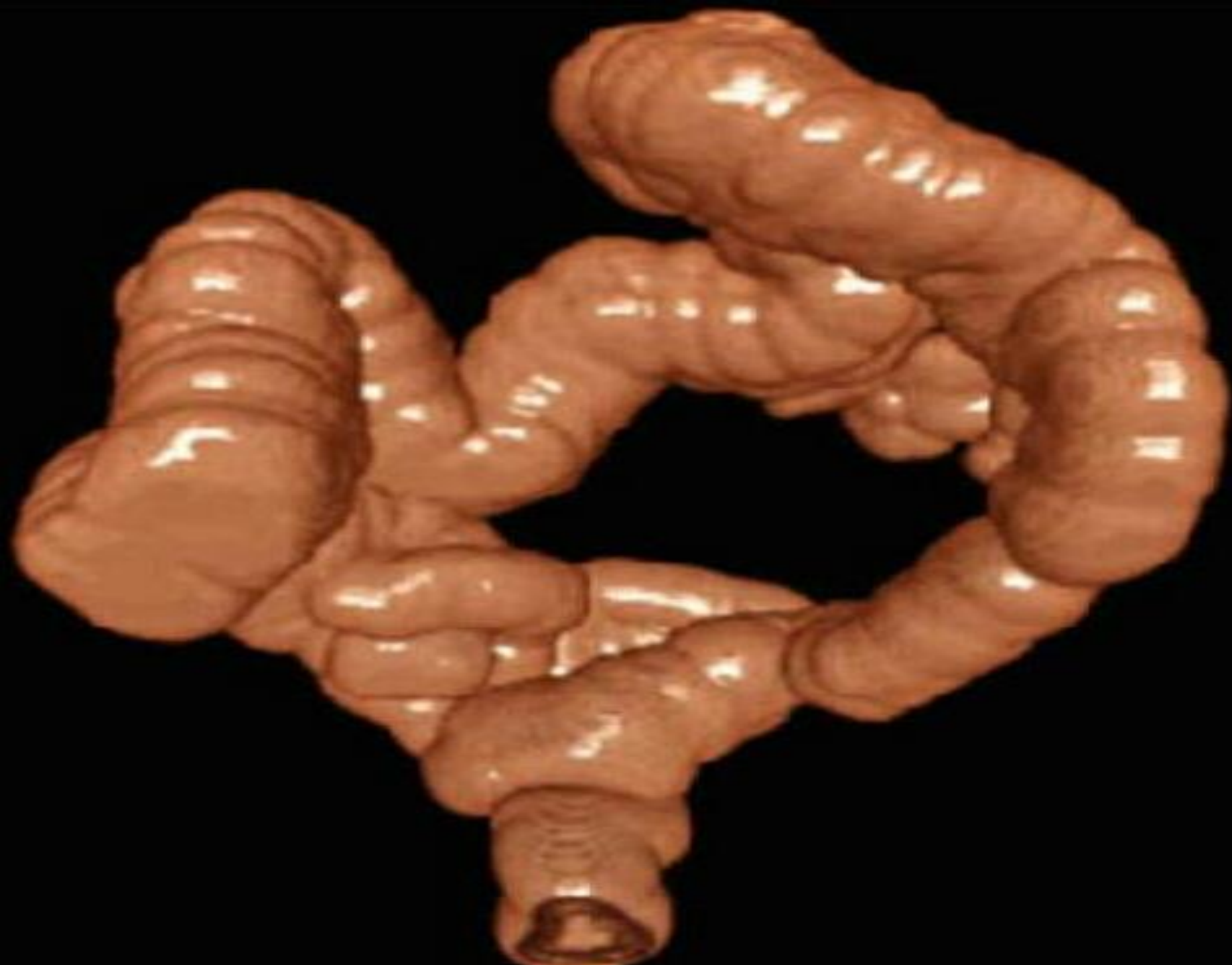
Cancer



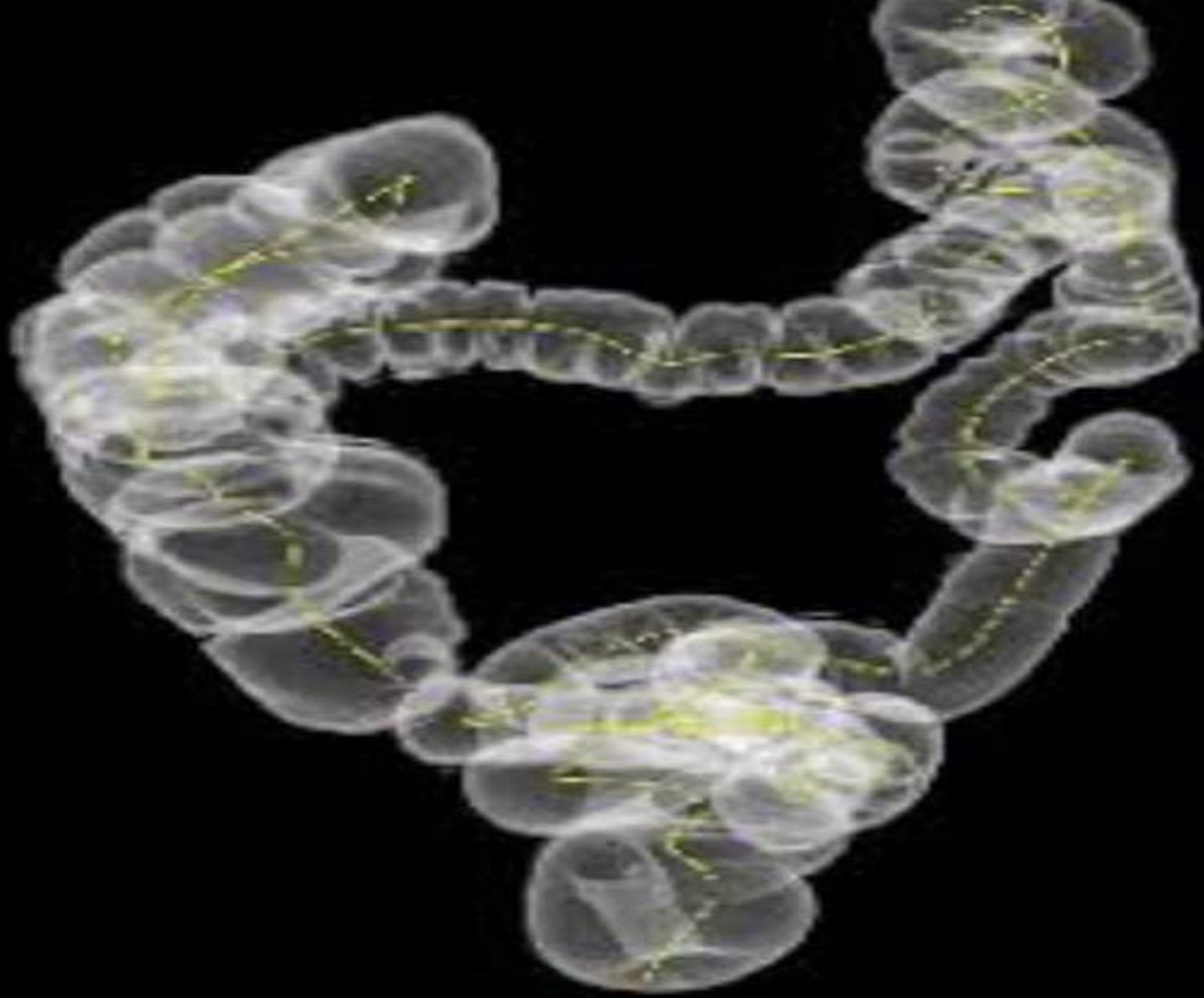


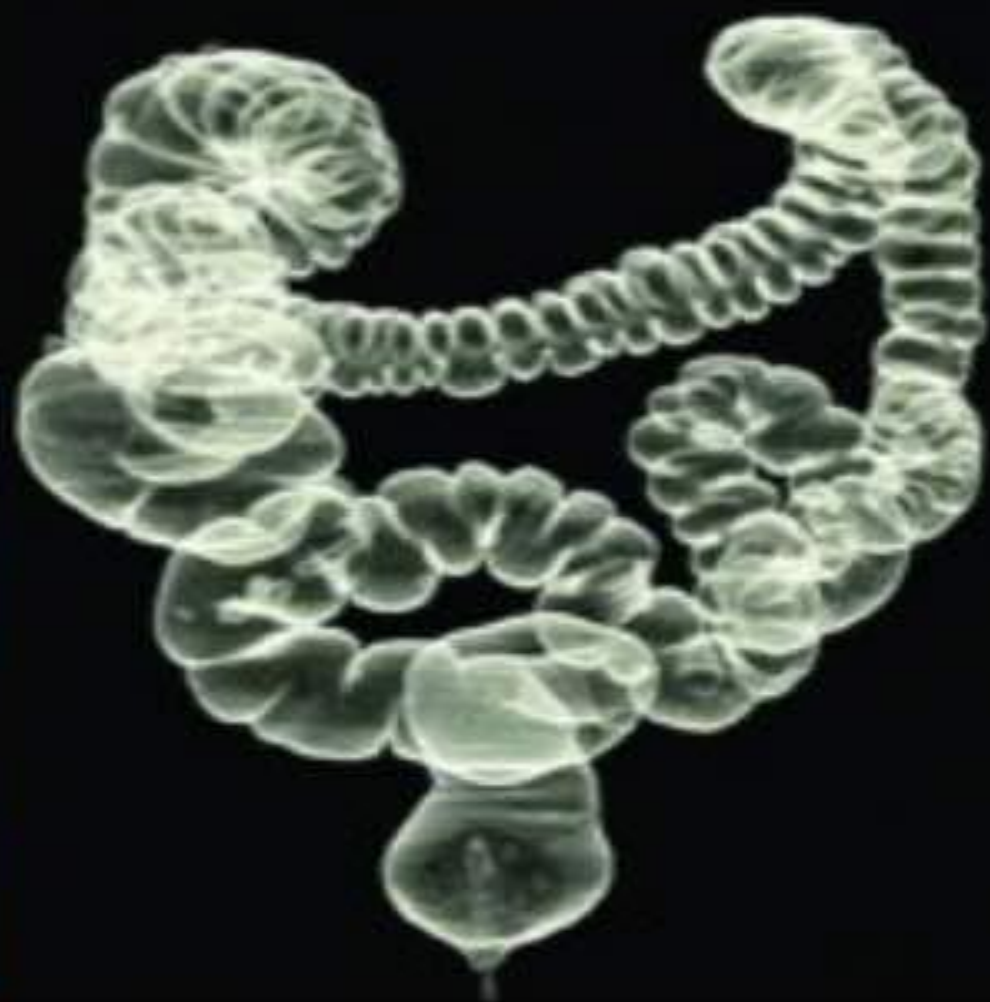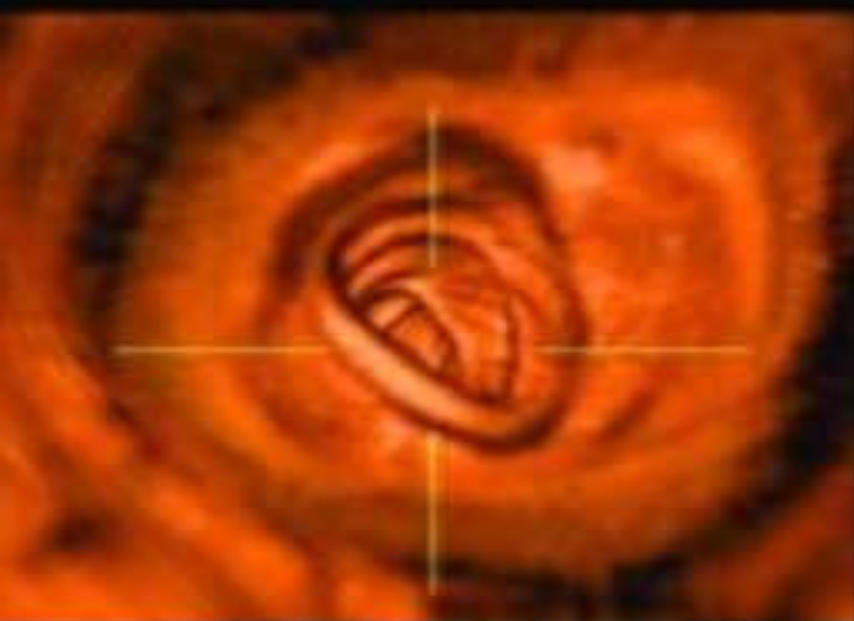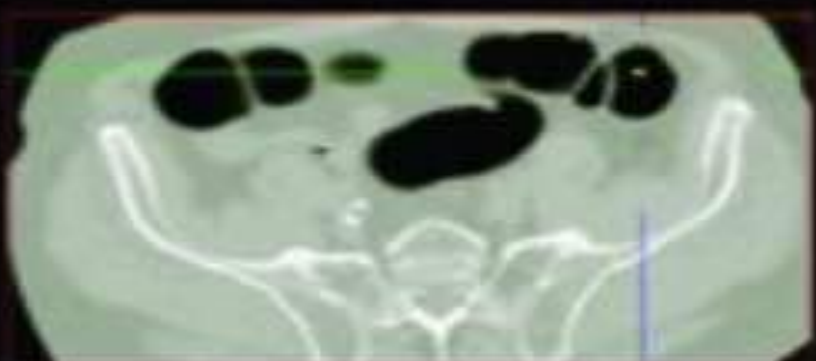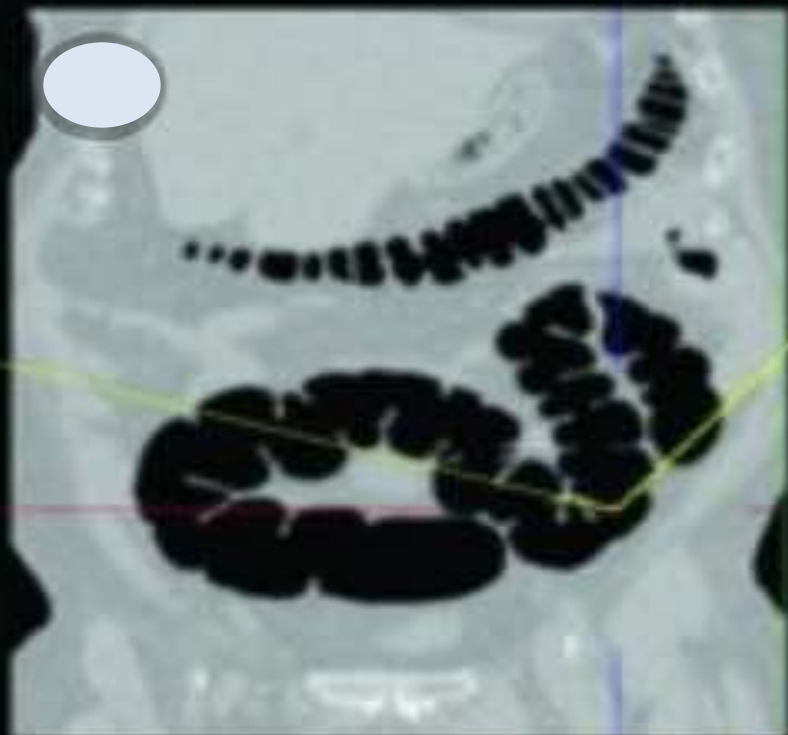












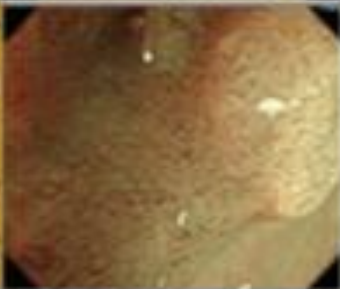









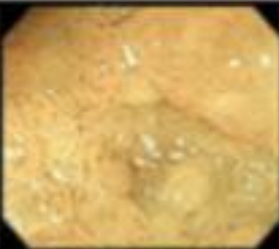





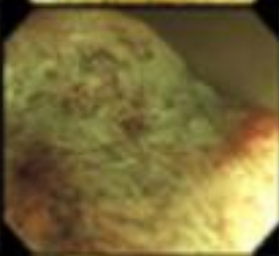
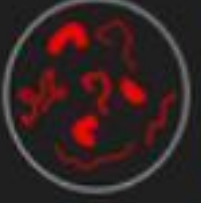
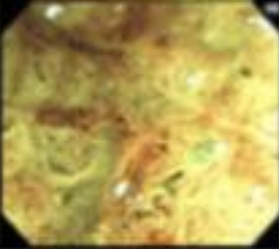


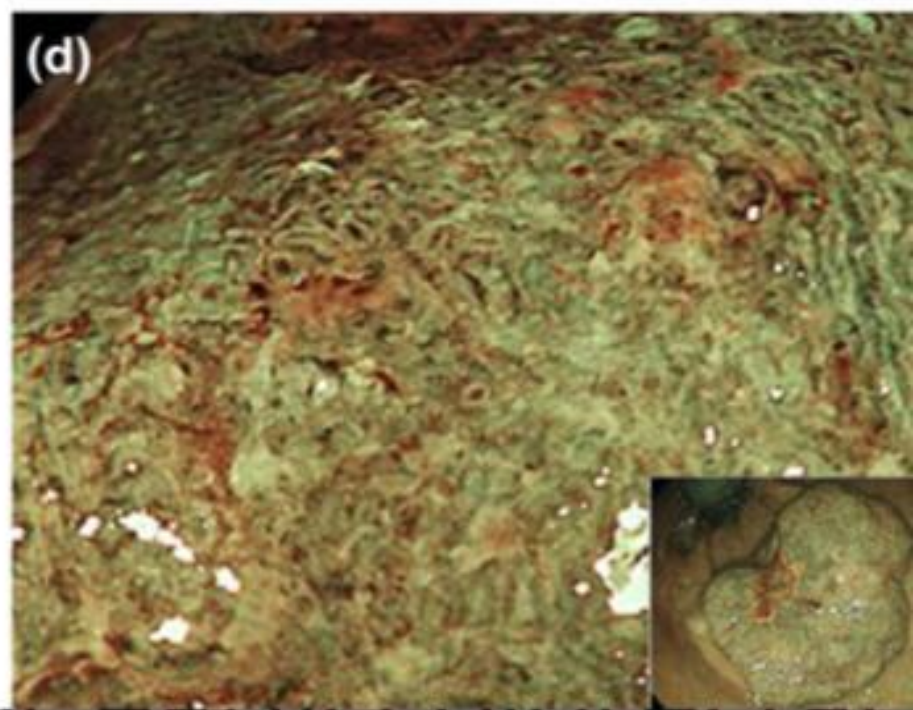
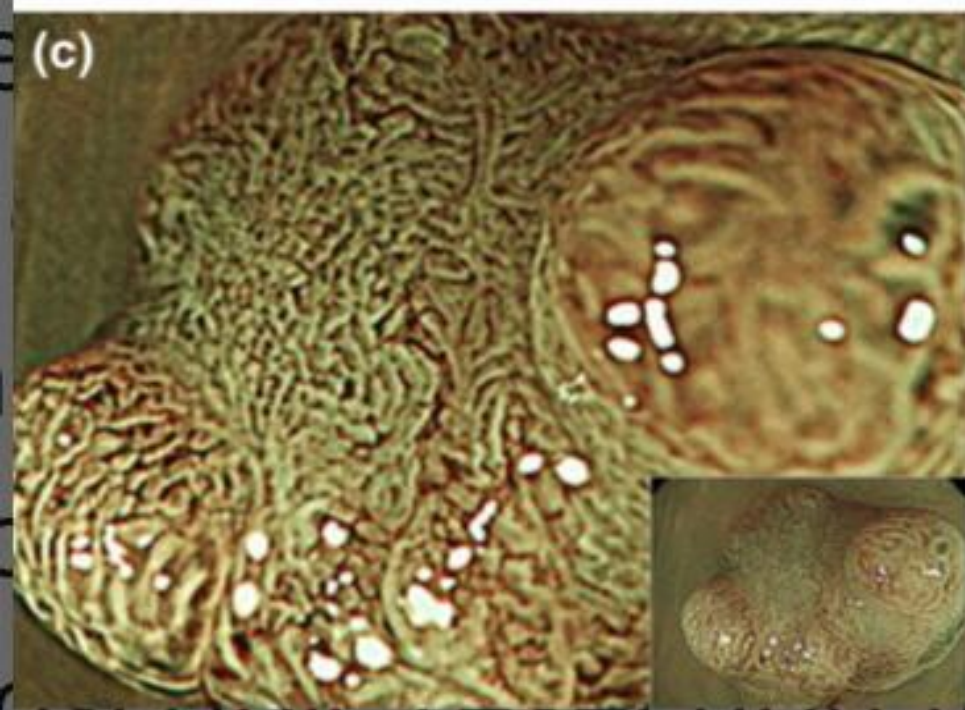
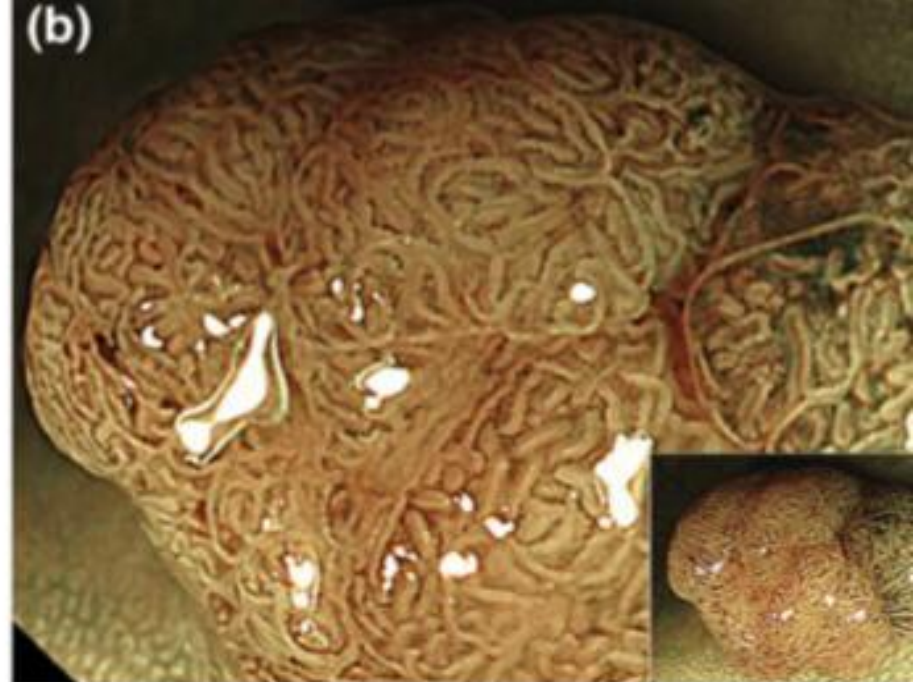
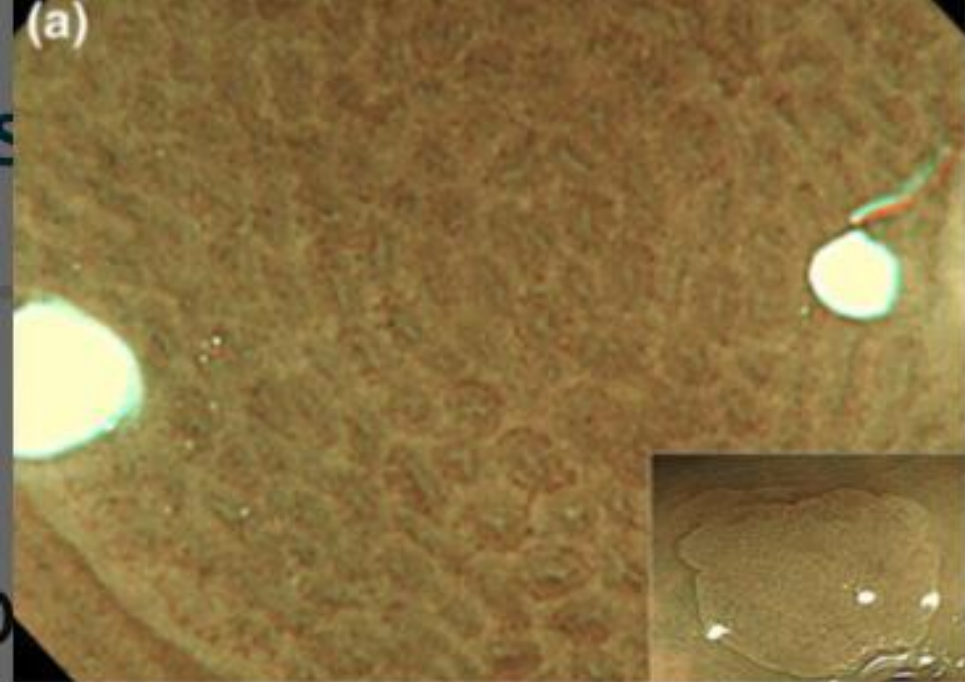


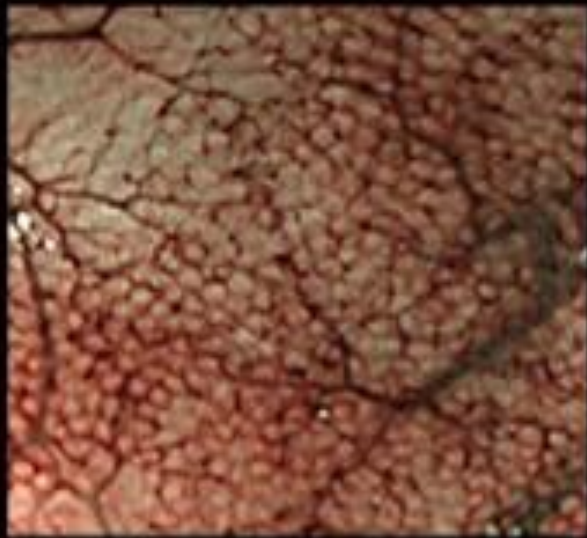
# **JNET classification**

	Type 1	Type 2A	Type 2B
<b>Vessel pattern</b>	<ul style="list-style-type: none"> <li>- Invisible<sup>*1</sup></li> </ul>	<ul style="list-style-type: none"> <li>- Regular caliber</li> <li>- Regular distribution (meshed/spiral pattern)<sup>**2</sup></li> </ul>	<ul style="list-style-type: none"> <li>- Variable caliber</li> <li>- Irregular distribution</li> </ul>
<b>Surface pattern</b>	<ul style="list-style-type: none"> <li>- Regular dark or white spots</li> <li>- Similar to surrounding normal mucosa</li> </ul>	<ul style="list-style-type: none"> <li>- Regular (tubular/branched/papillary)</li> </ul>	<ul style="list-style-type: none"> <li>- Irregular or obscure</li> </ul>
<b>Most likely histology</b>	Hyperplastic polyp/ Sessile serrated polyp	Low grade intramucosal neoplasia	High grade intramucosal neoplasia/ Shallow submucosal invasive cancer
<b>Endoscopic image</b>			

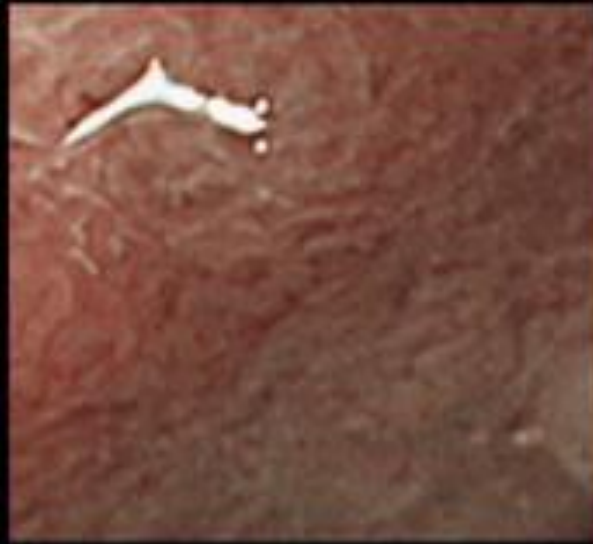
<p><b>pattern 1</b></p>			<p><b>Invisible vessels</b></p>
<p><b>pattern 2</b></p>			<p><b>Slight caliber dilatation</b></p>
<p><b>pattern 3V</b></p>			<p><b>Regular arrangement of dilated vessels in the same places as the stroma of the ducts that are thought to have a villous structure</b></p>
<p><b>pattern 3I</b></p>			<p><b>Marked caliber dilatation</b></p>
<p><b>pattern 4</b></p>			<p><b>Sparse distribution of vessels and untraceable vessel arrangement</b></p>

<p><b>A</b> type</p>			<p>Microvessel intensity are vague or invisible. None or isolated lacy vessels may be present coursing across the lesion. Brown or black dots, star or round shaped surrounded by white</p>	
<p><b>B</b> type</p>			<p>Regular surface pattern is observed by the increased microvessel intensity around the pits and image enhance. Or regular meshed microvessel network pattern is observed.</p>	
<p><b>C</b> type</p>	<p>1</p>			<p>Irregular surface pattern is observed by the increased microvessel intensity around the pits and image enhance. Thickness and distribution of vessels are homogenous.</p>
	<p>2</p>			<p>More irregular surface pattern is observed by the increased microvessel intensity around the pits and image enhance. Thickness and distribution of vessels are heterogenous.</p>
	<p>3</p>			<p>Surface pattern is completely unclear. Thickness and distribution of vessels are heterogenous. Avascular area (AVA) and scattered microvessel fragments are observed</p>

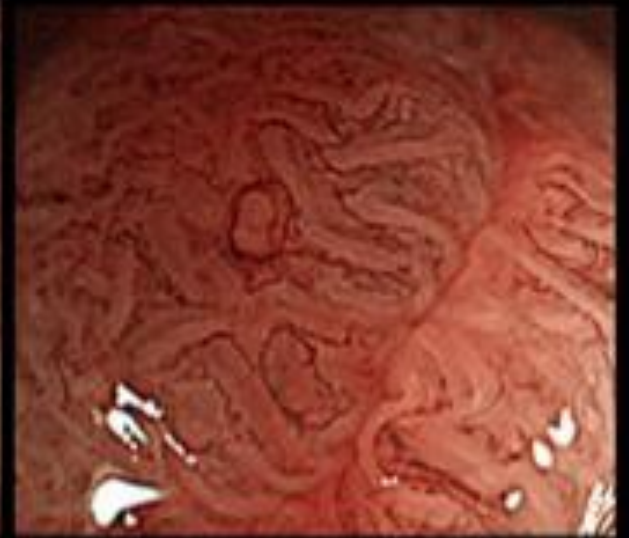




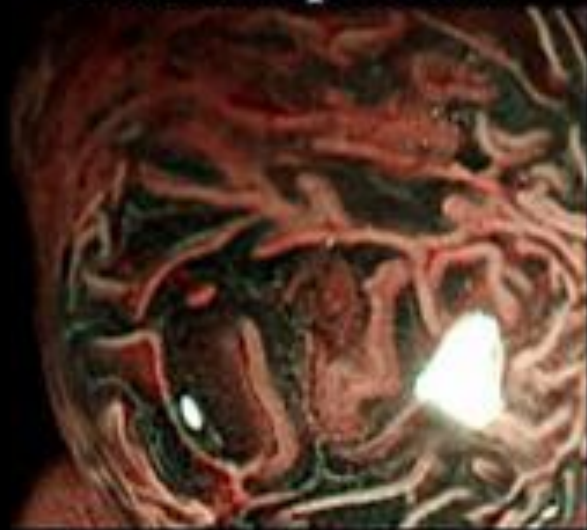**Normal pattern**



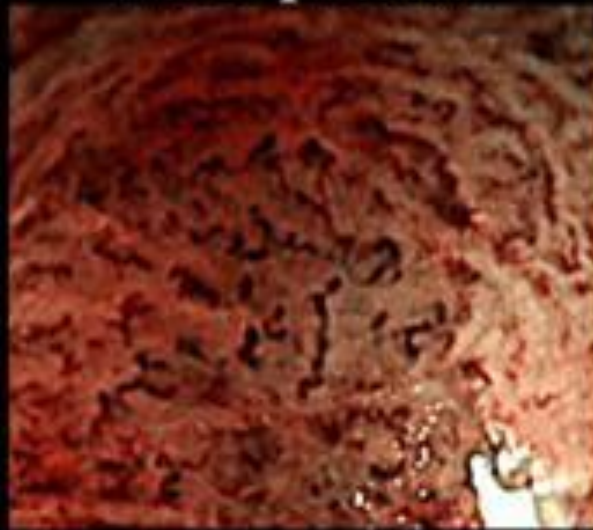
**Faint pattern**



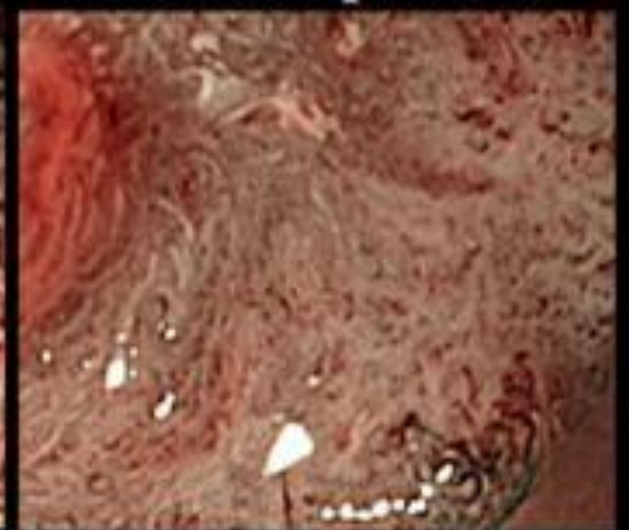
**Network pattern**



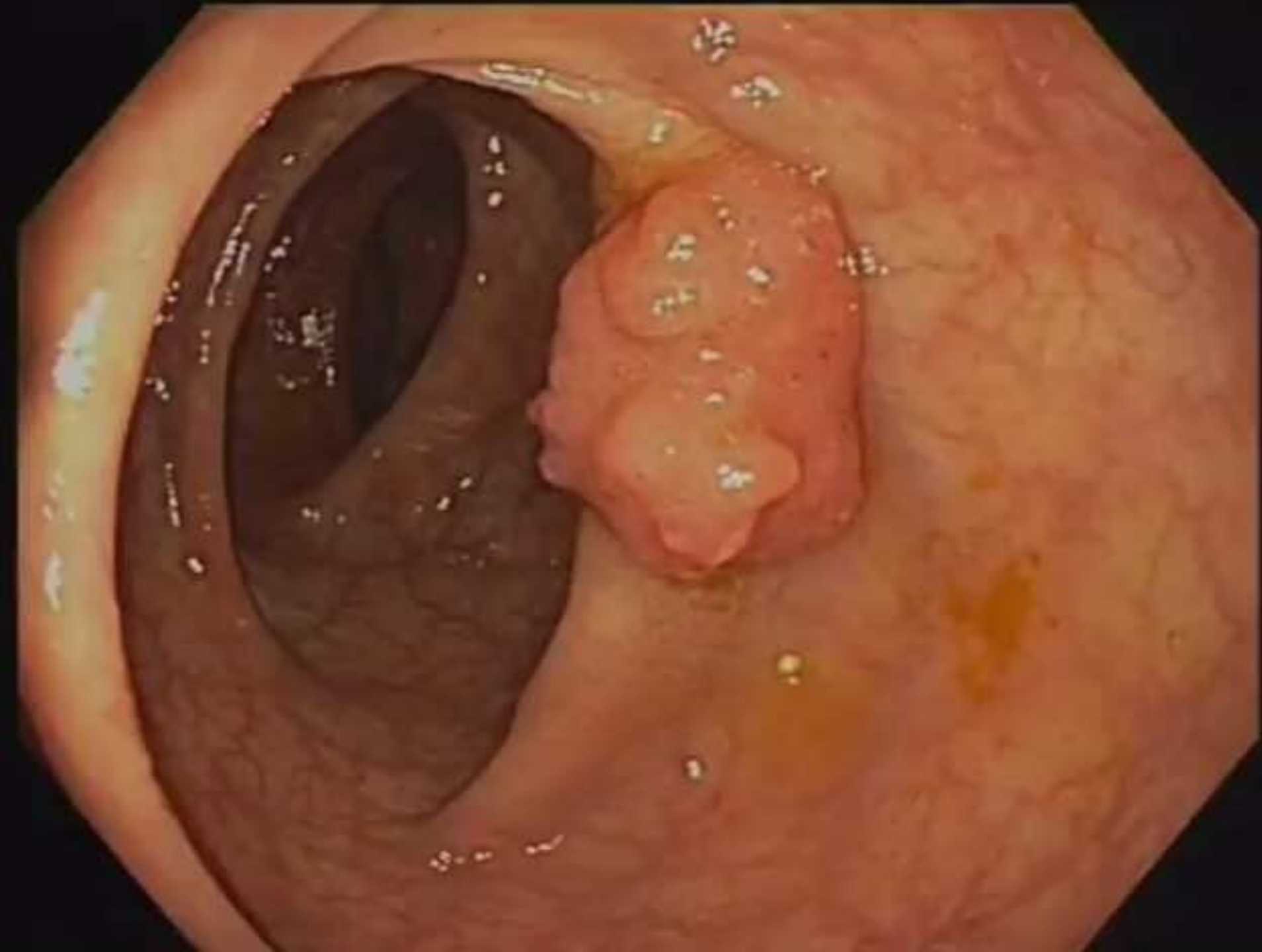
**Dense pattern**

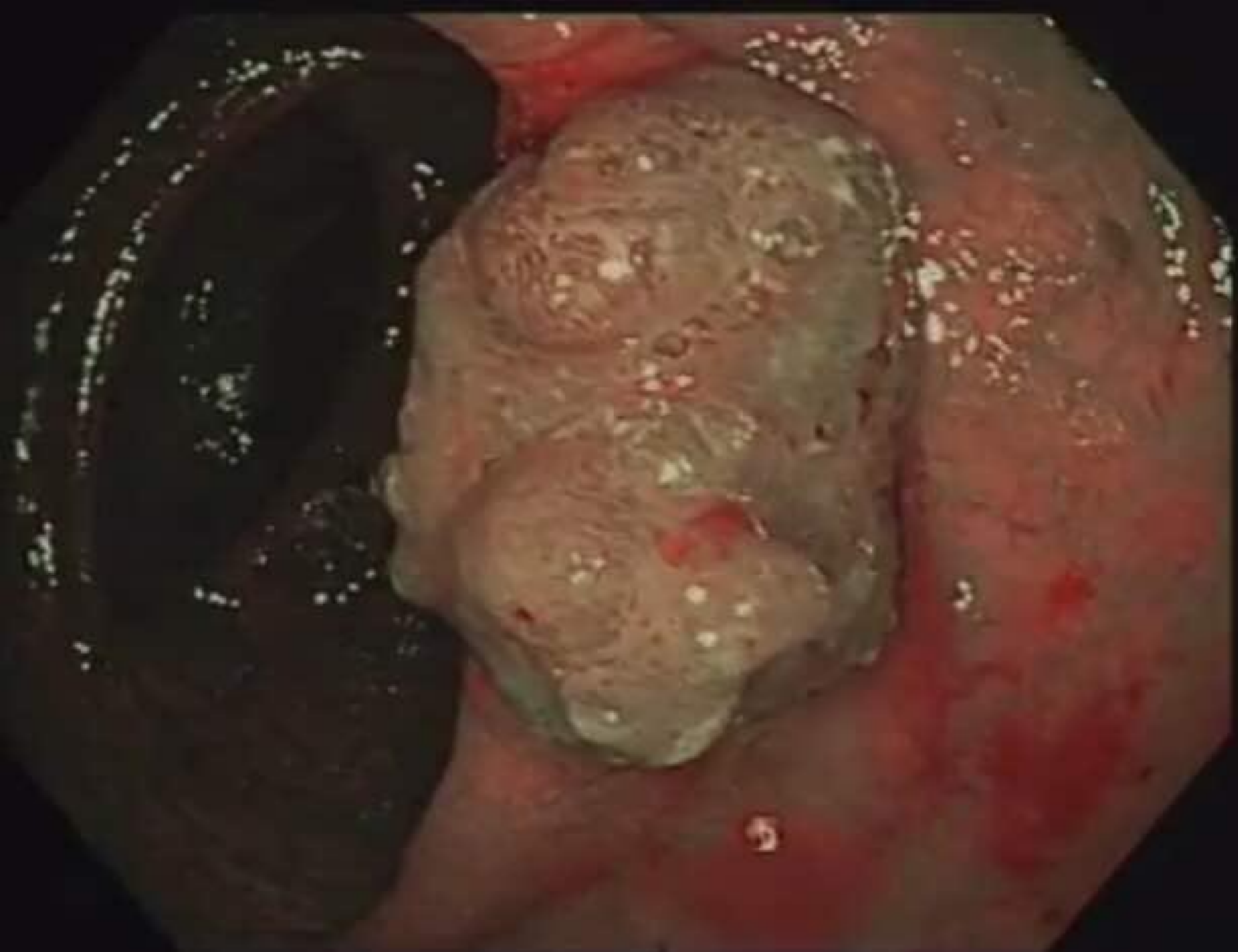


**Irregular pattern**

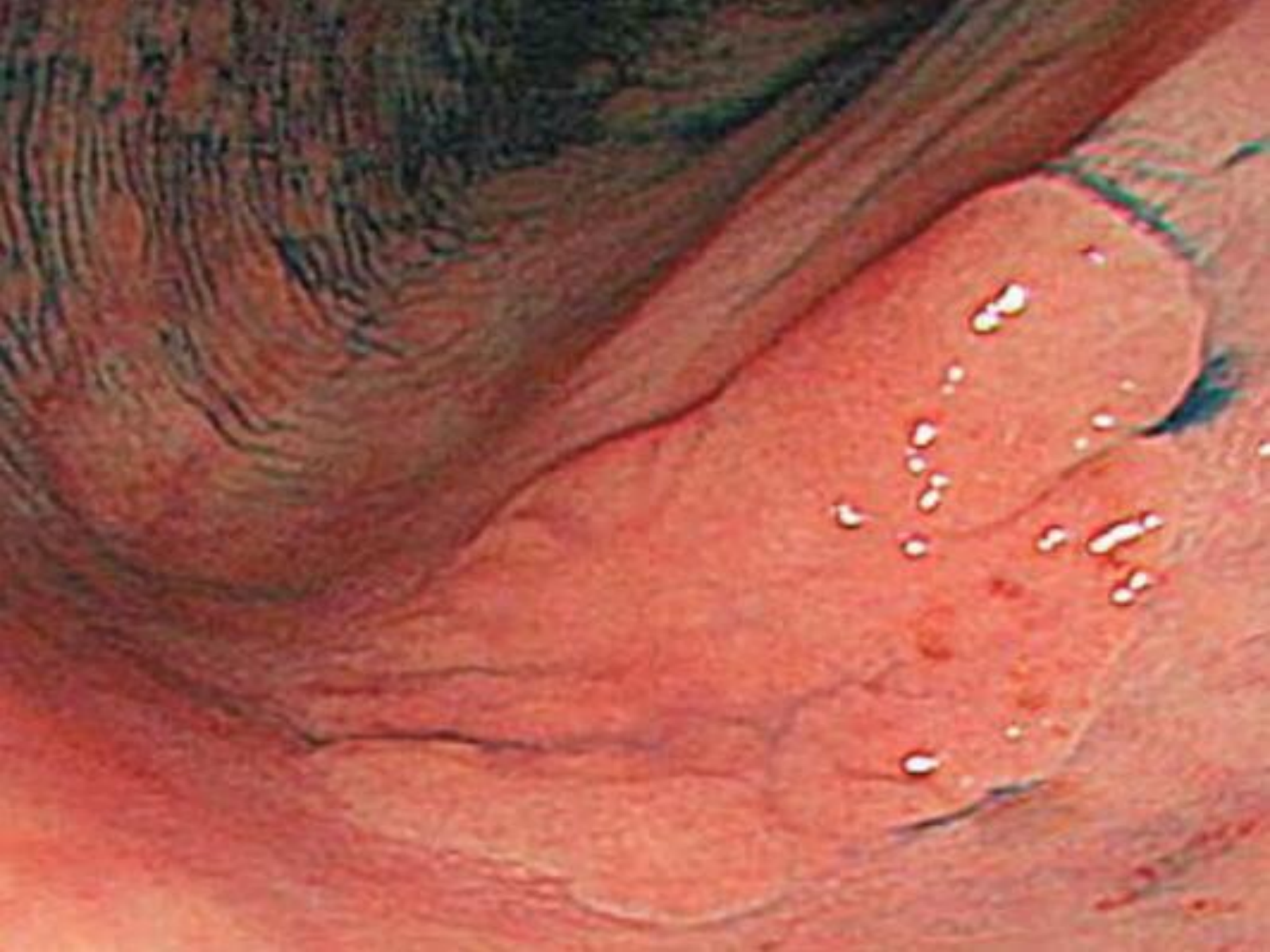

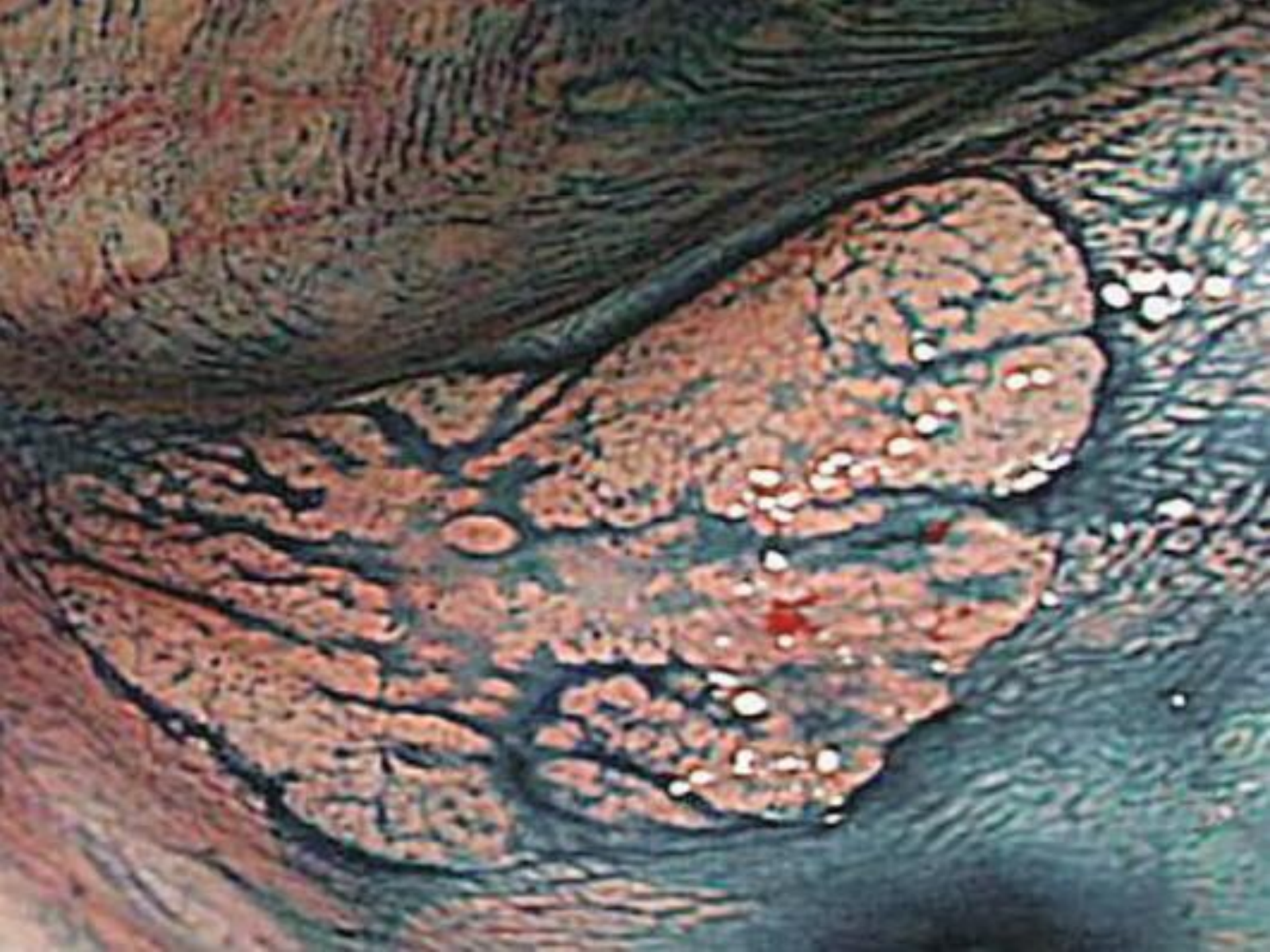**Sparse pattern**

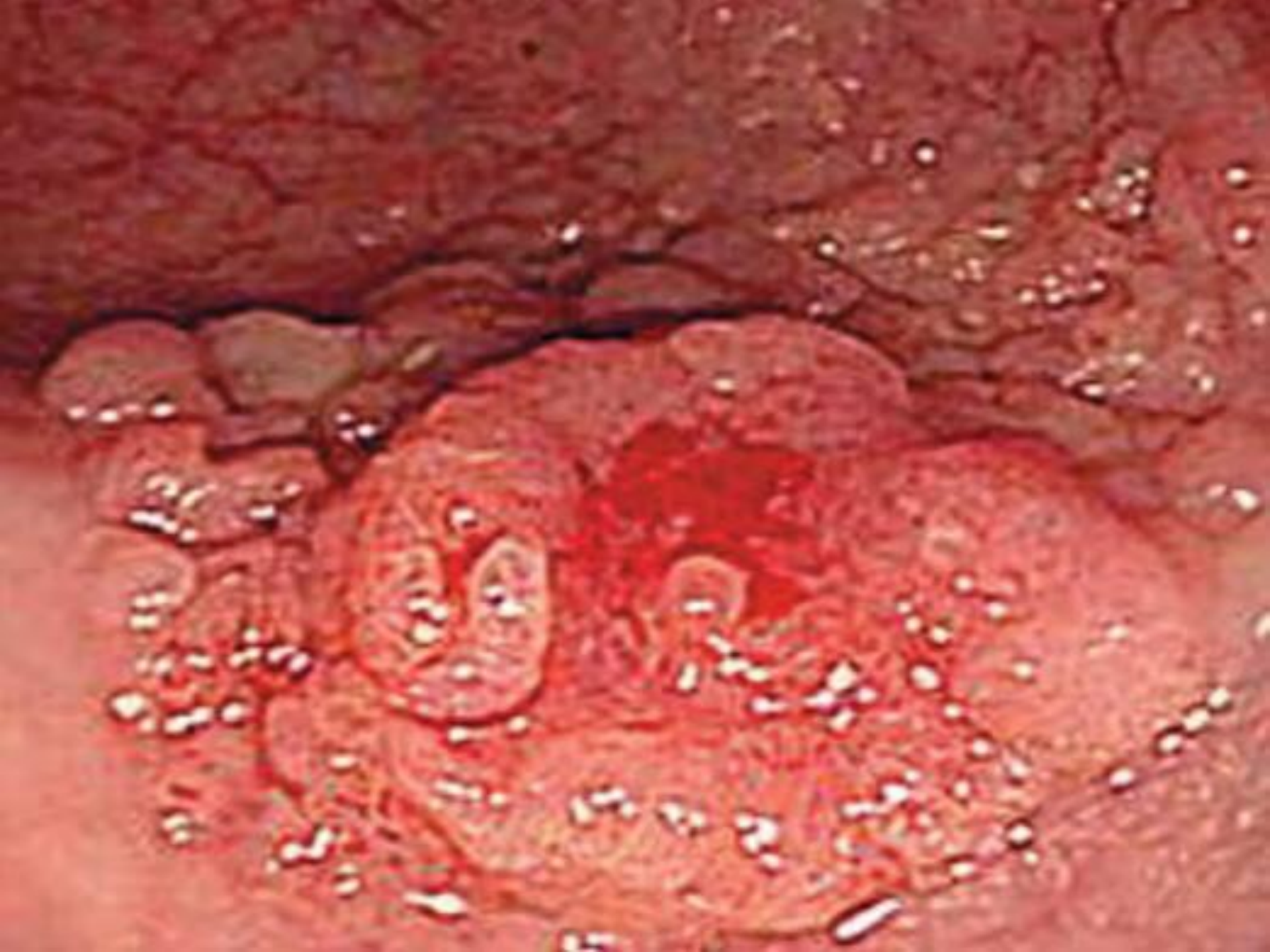

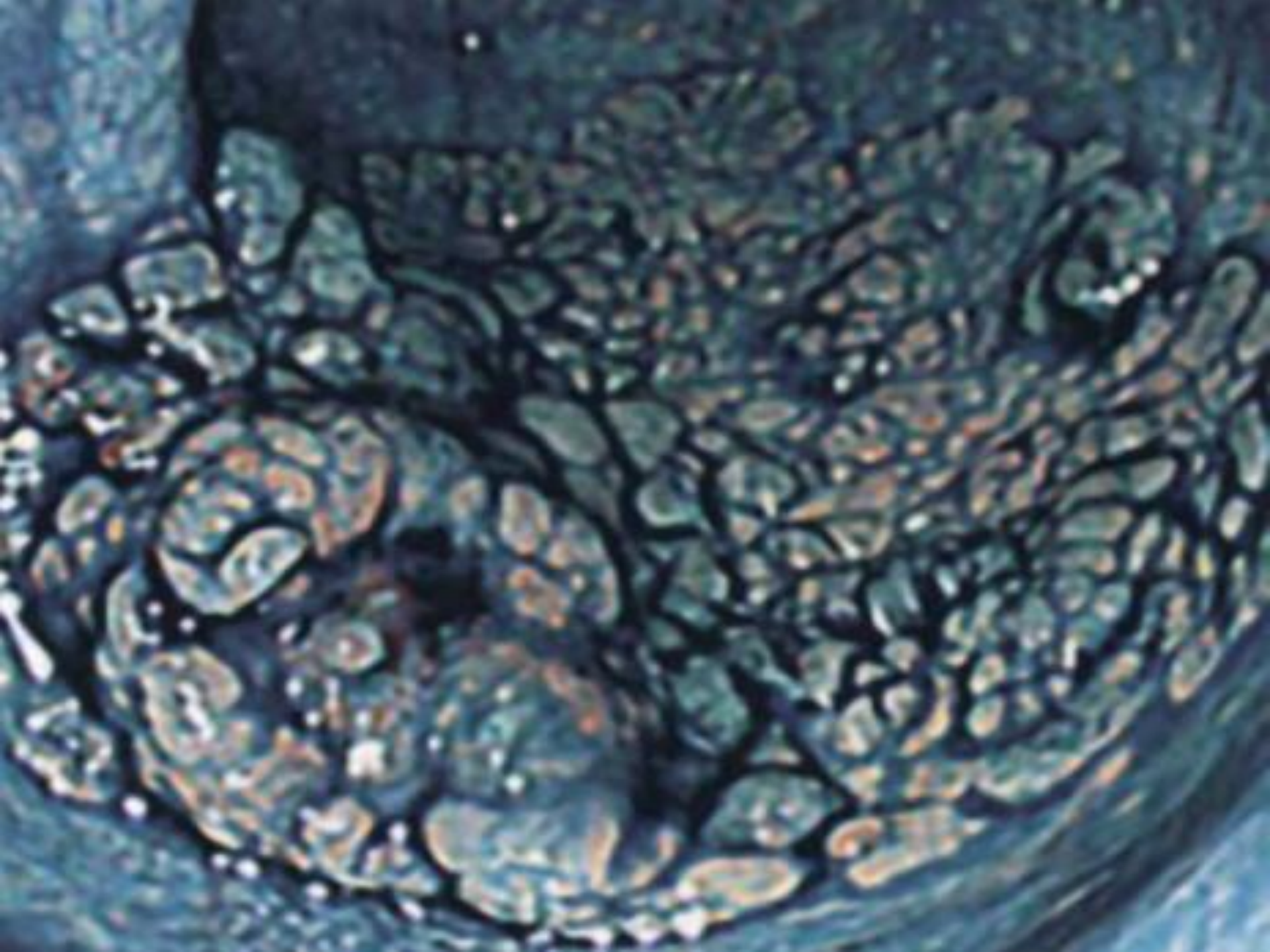


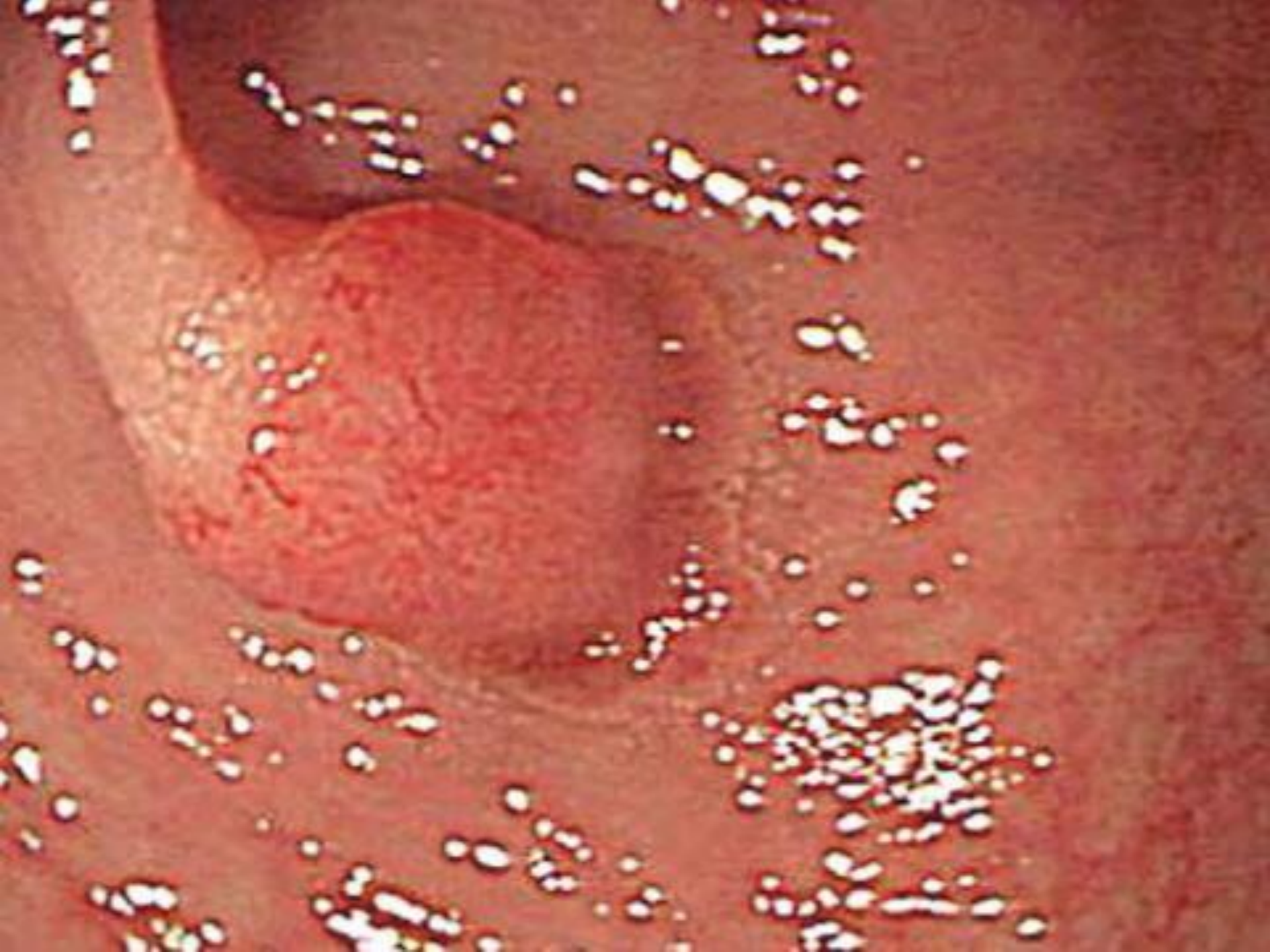# **PARIS Classification**

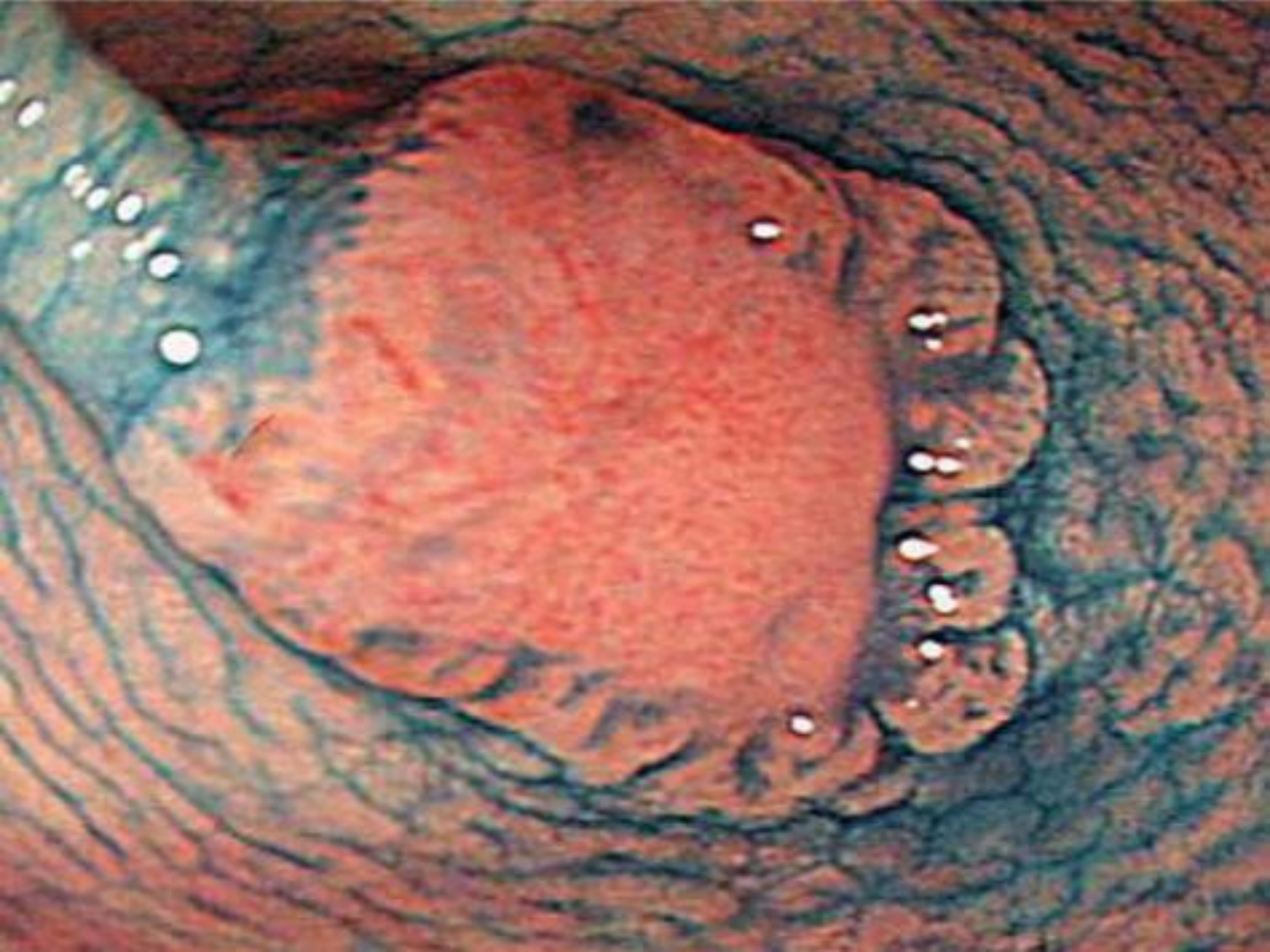


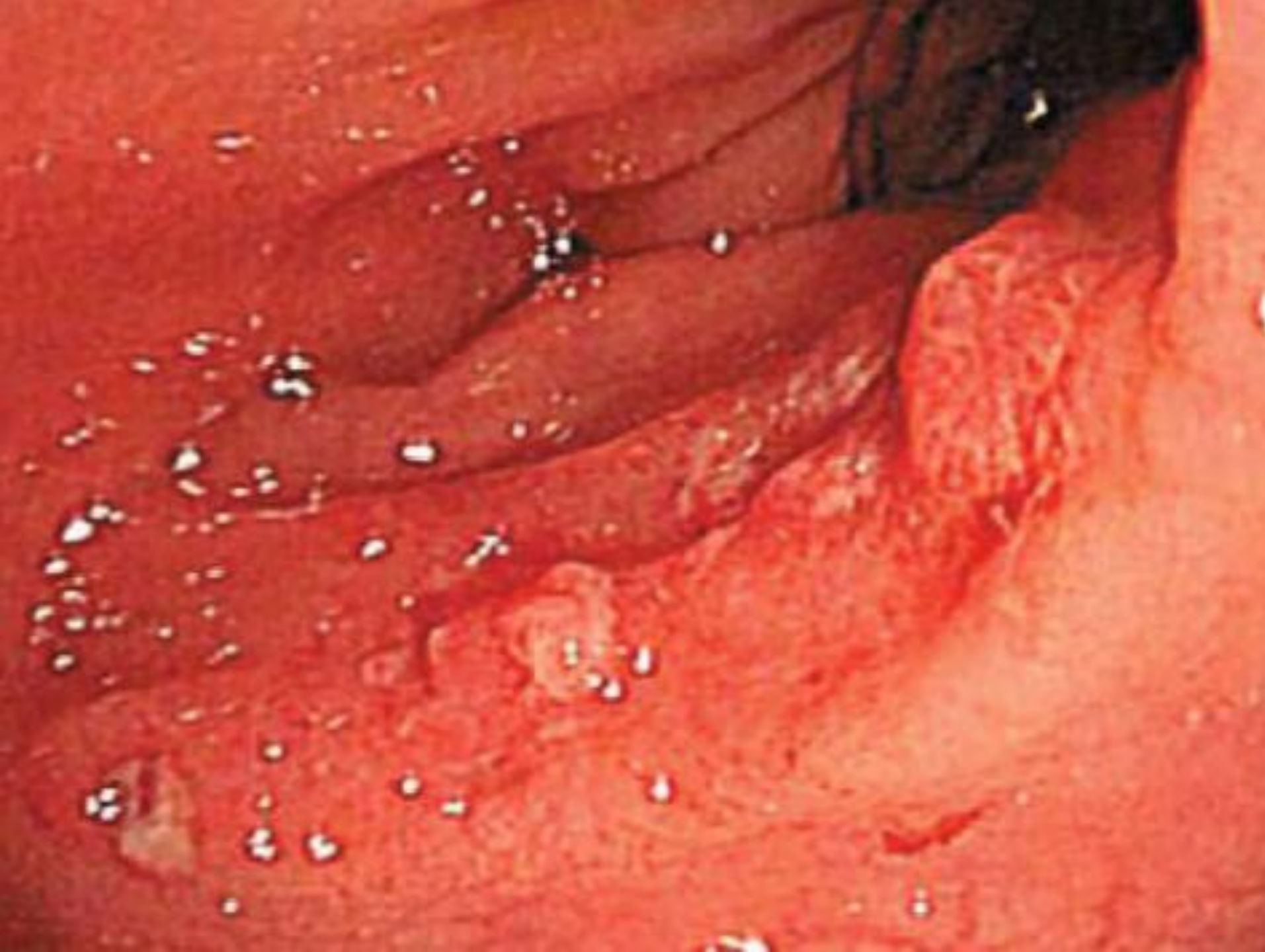


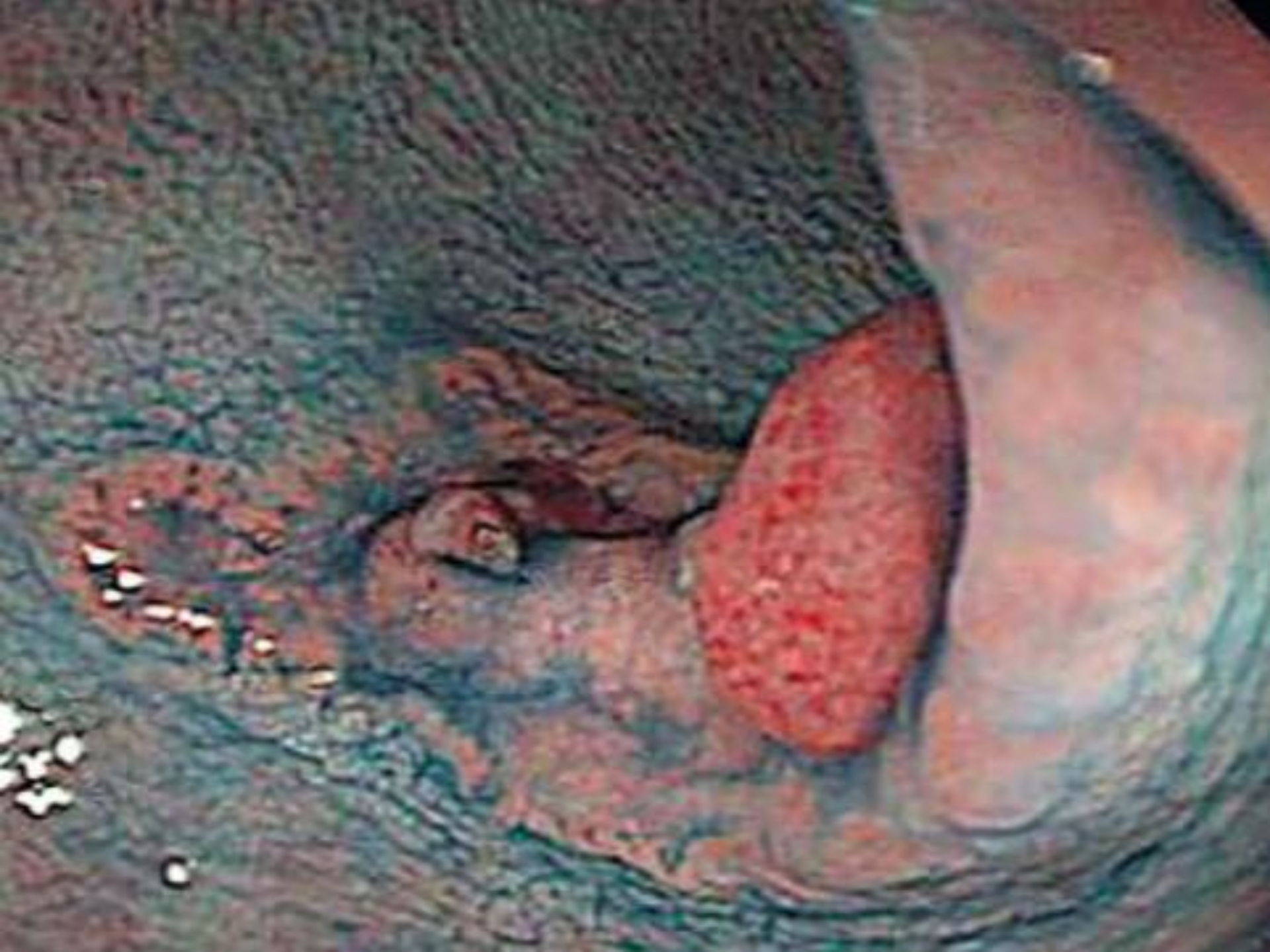




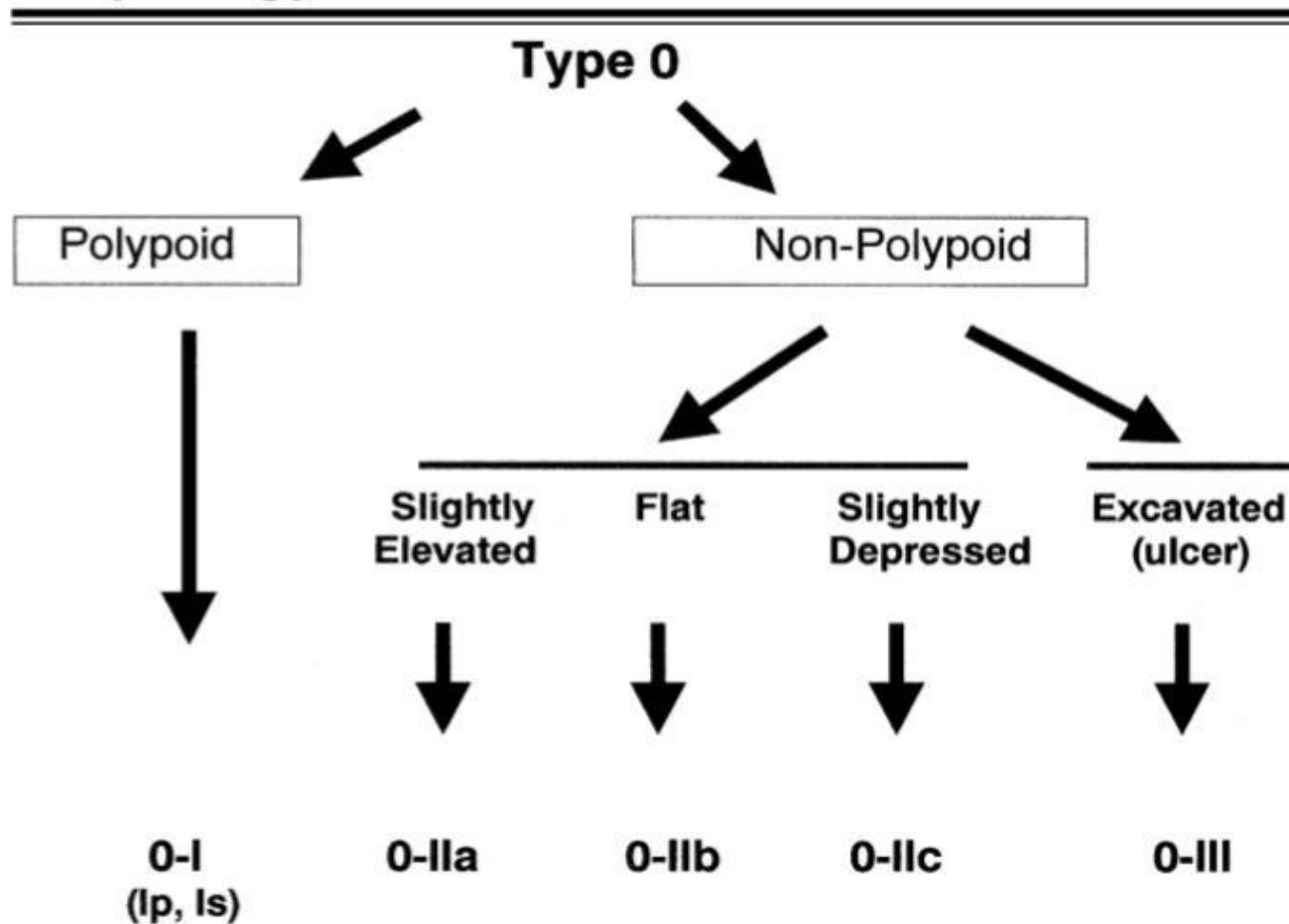


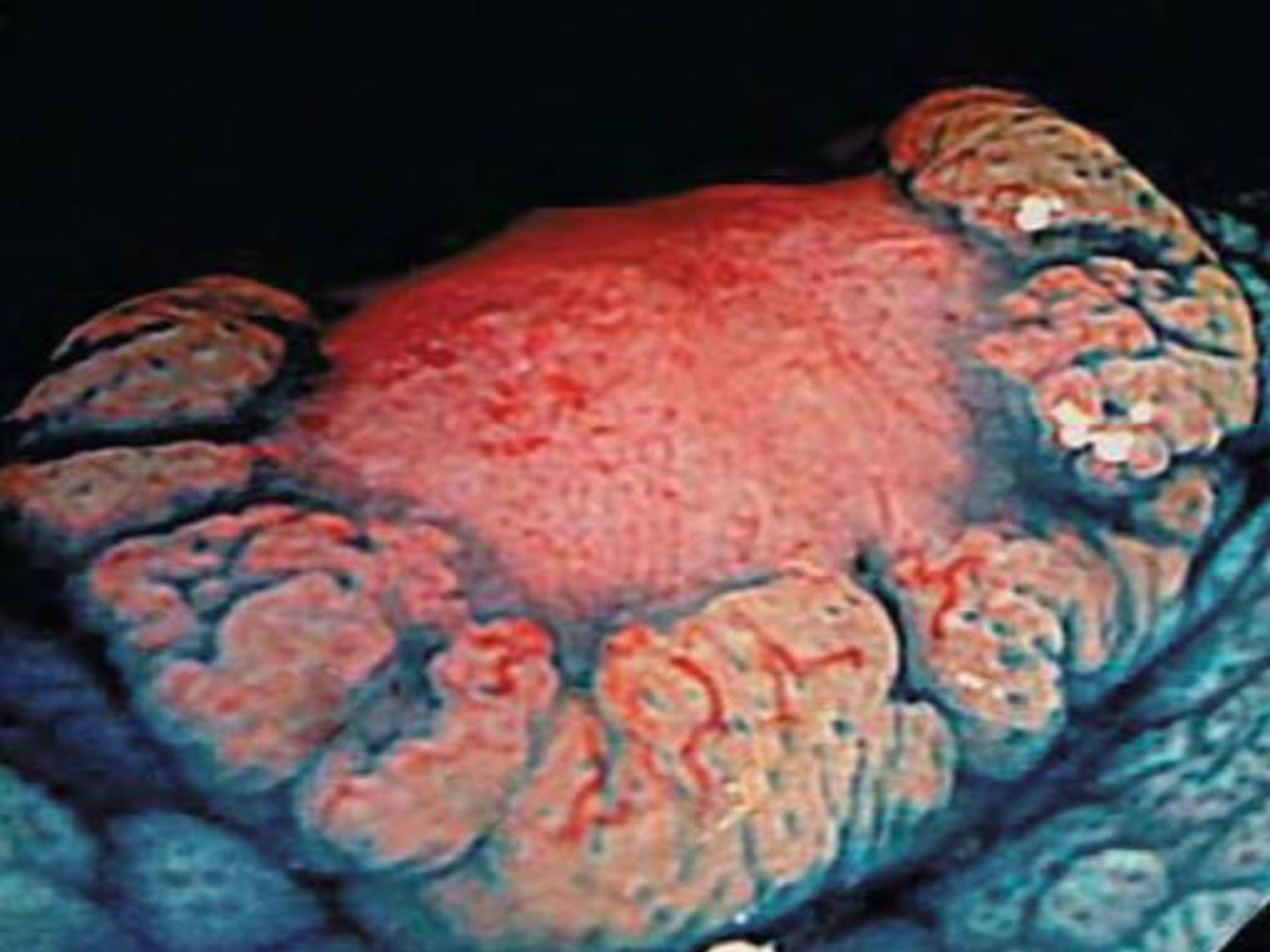




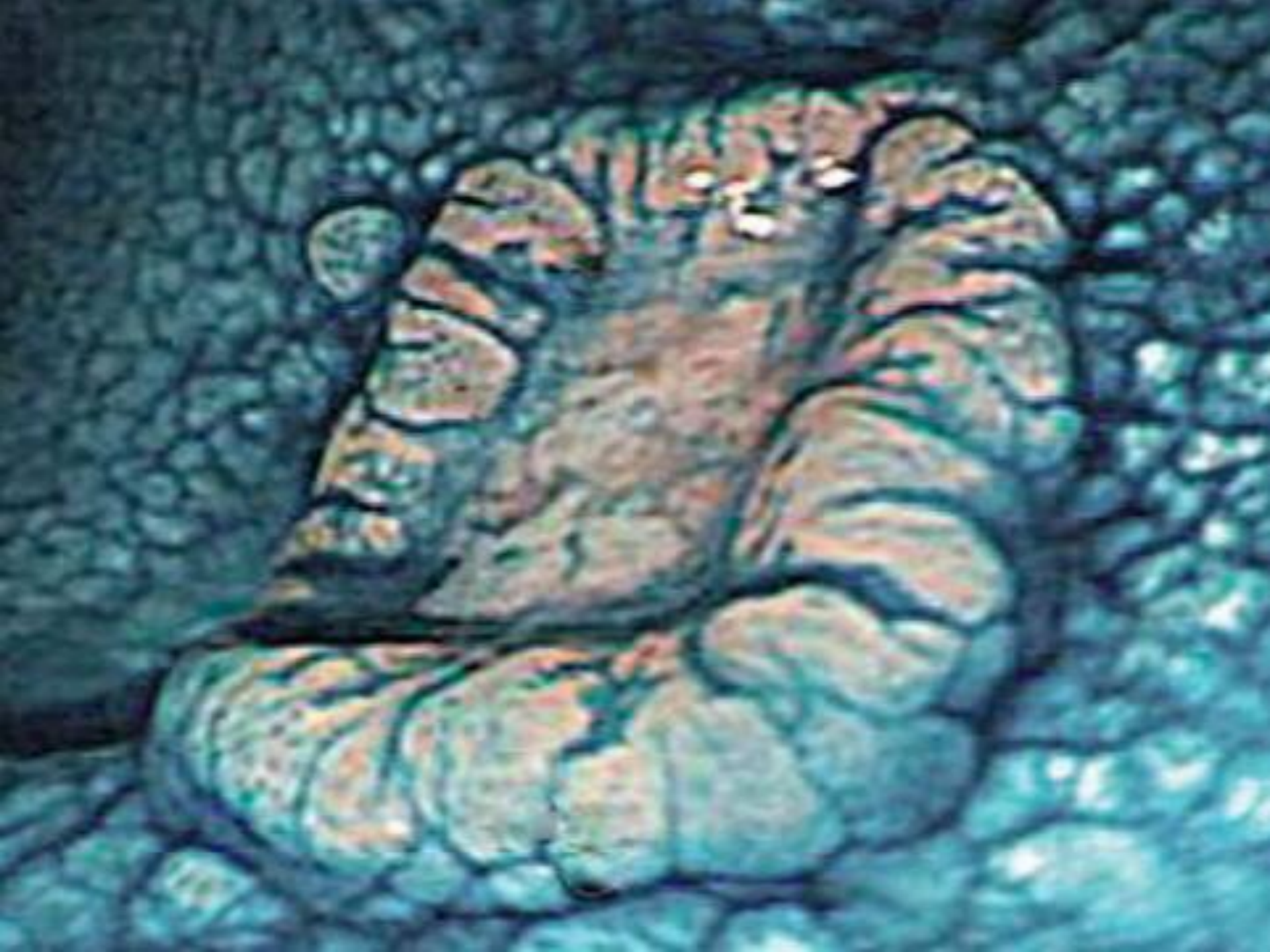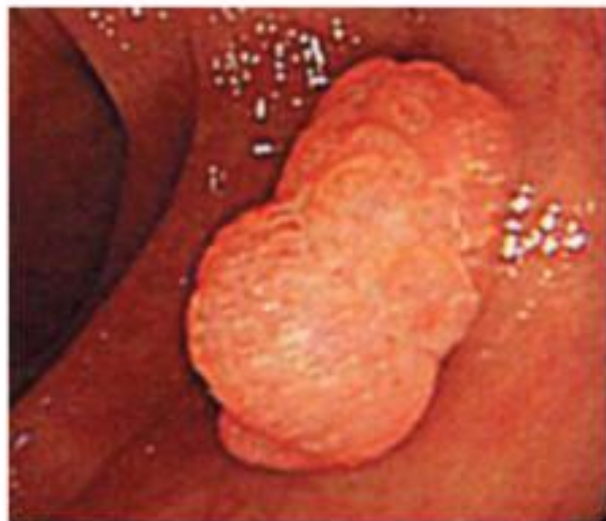*The Paris endoscopic classification of superficial neoplastic lesions*

**Table 2. Neoplastic lesions with “superficial” morphology**

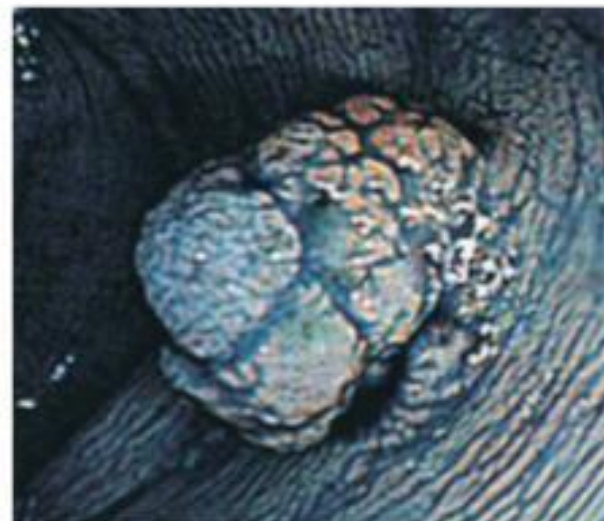






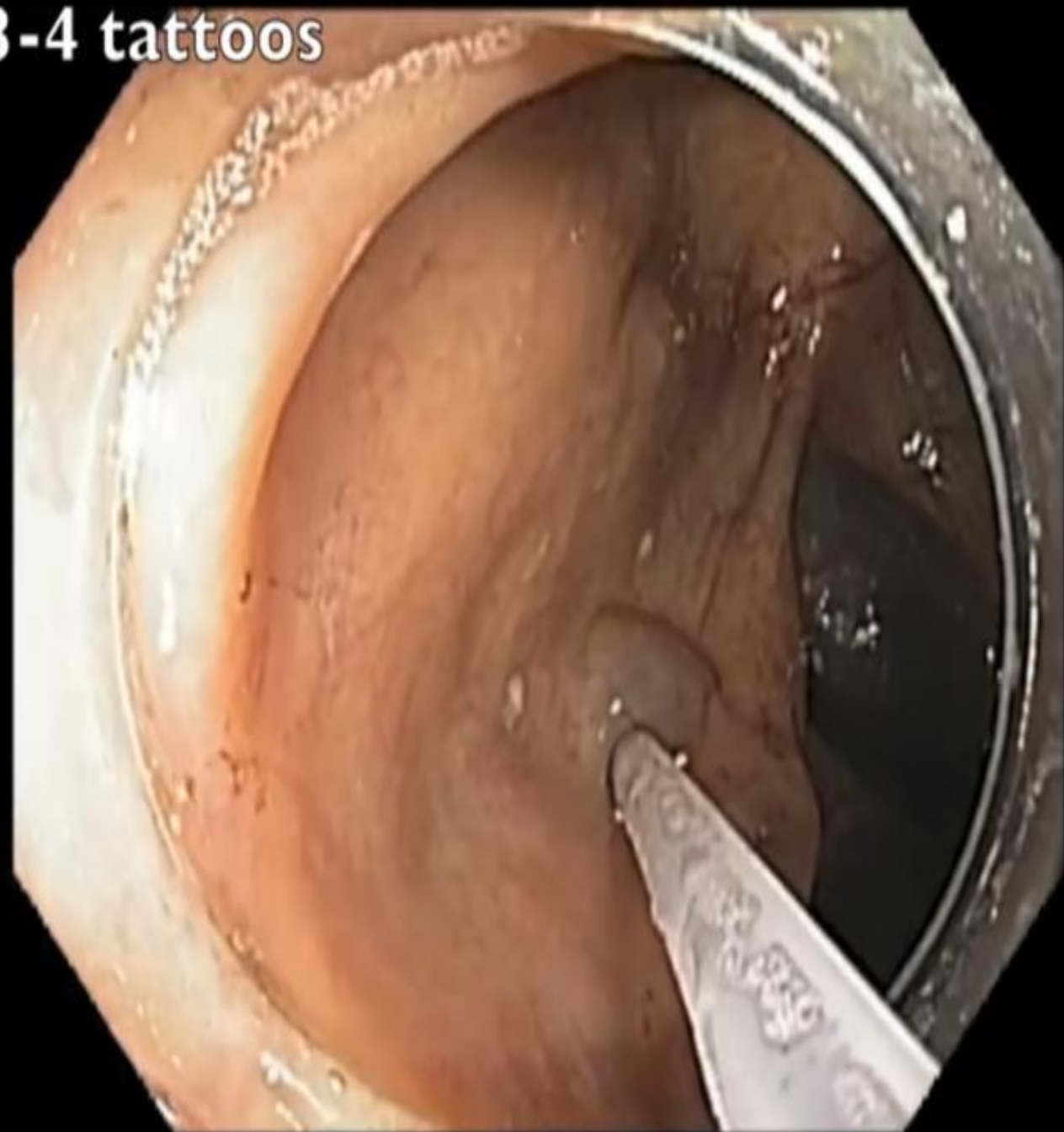


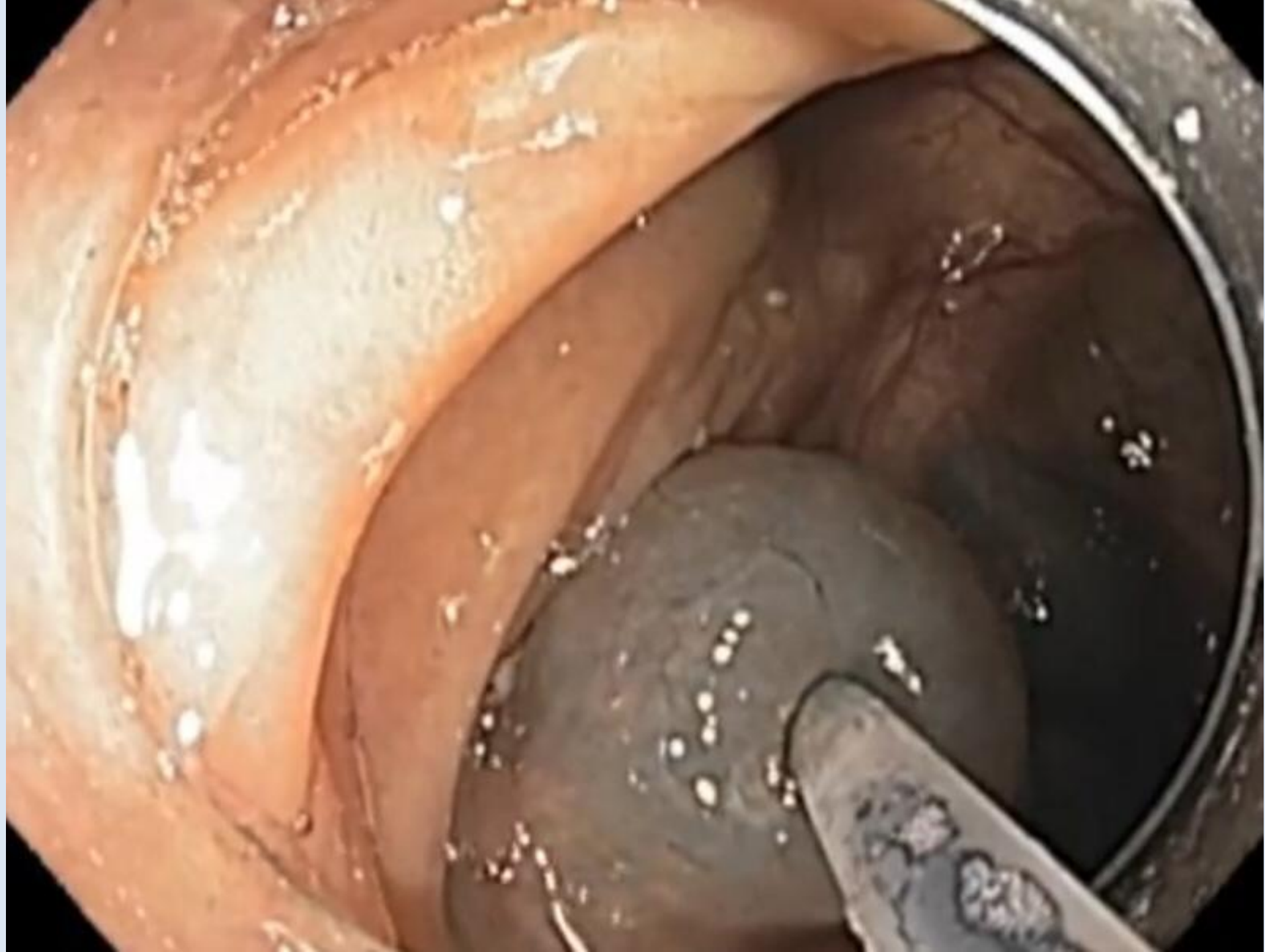
**Figure 7.** Large bowel type 0-I, unstained, intraepithelial neoplasia.

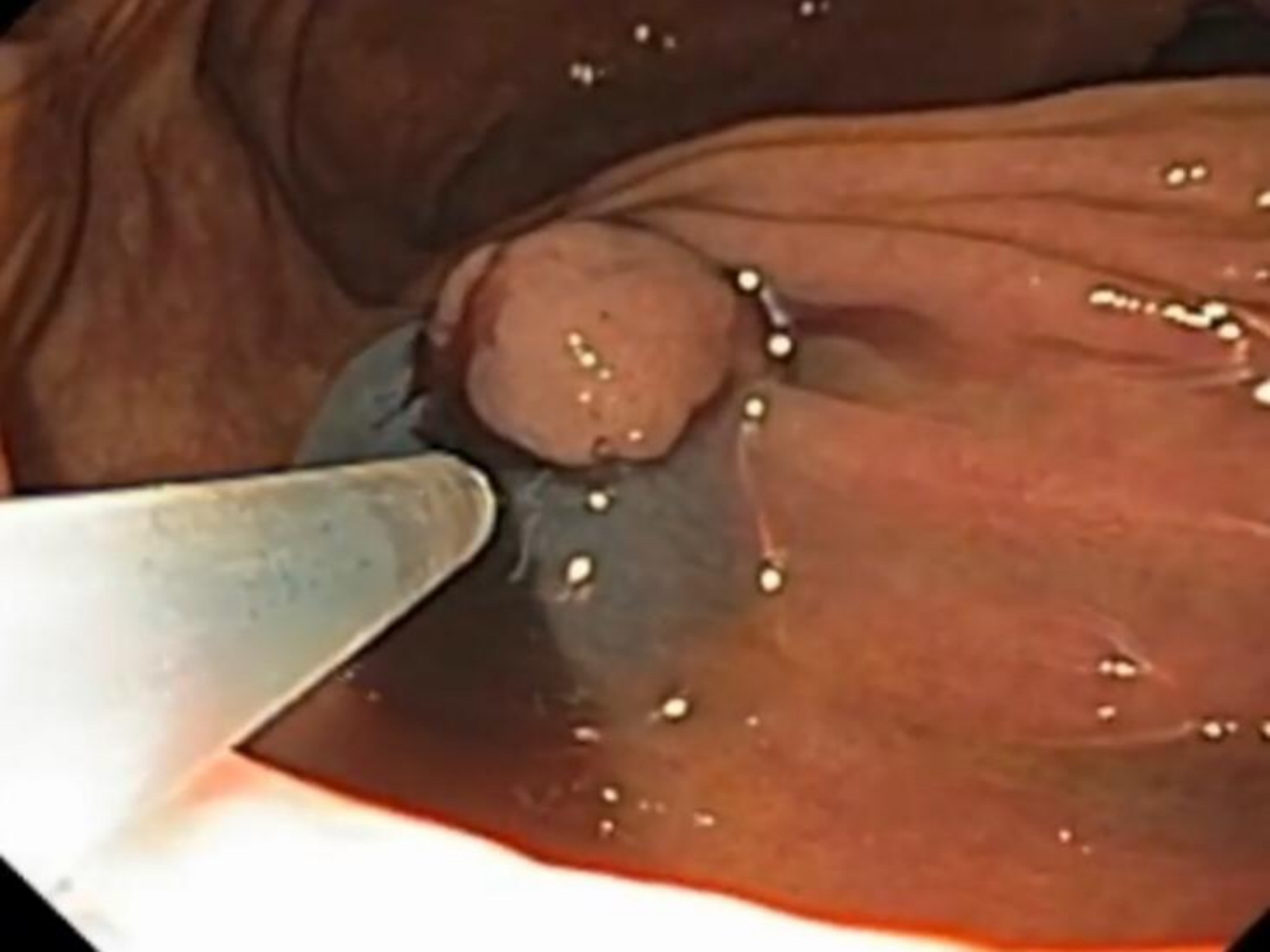


**Figure 8.** Same case as in Figure 7, chromoendoscopy with indigo carmine.

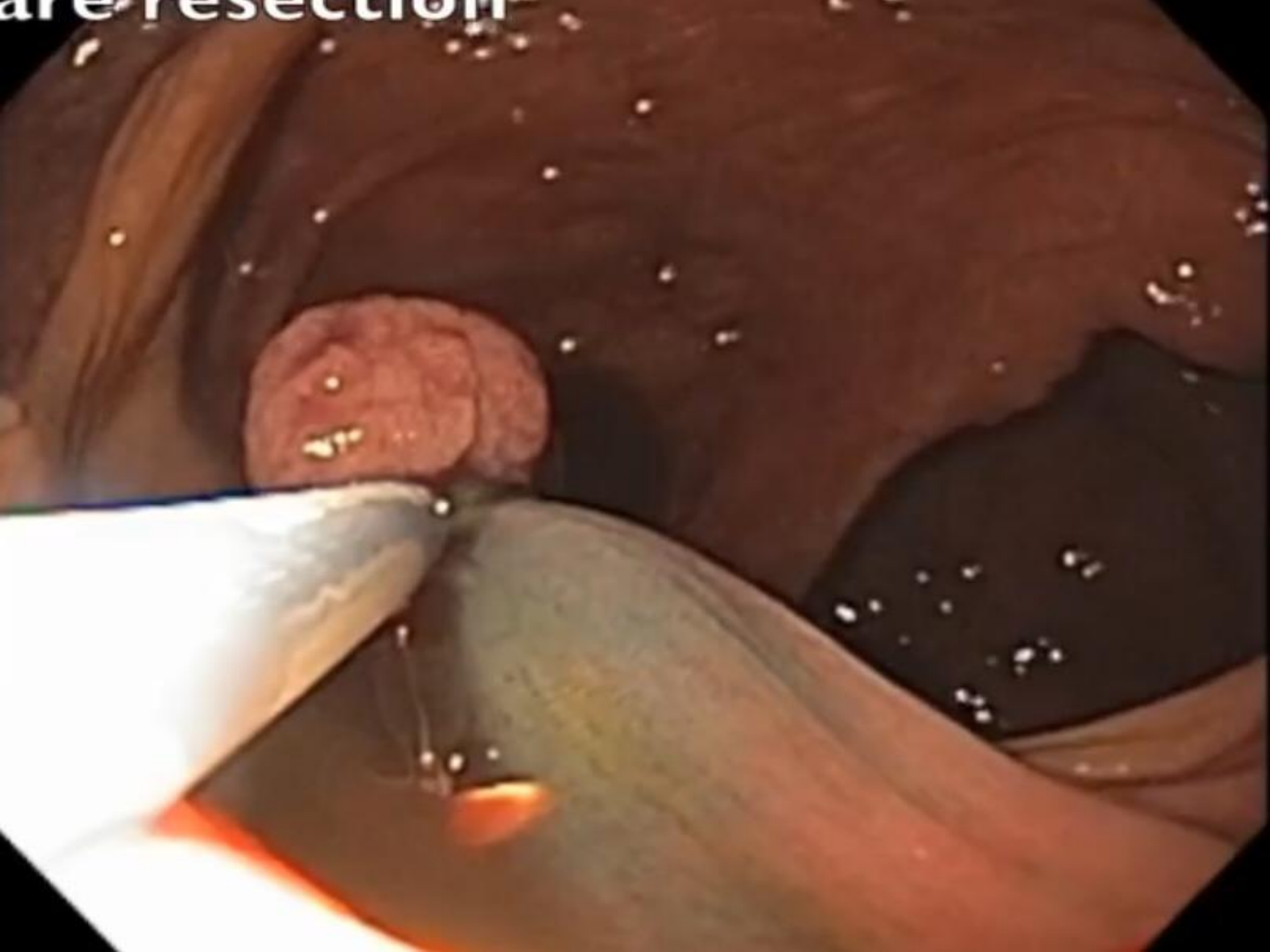
3-4 tattoos

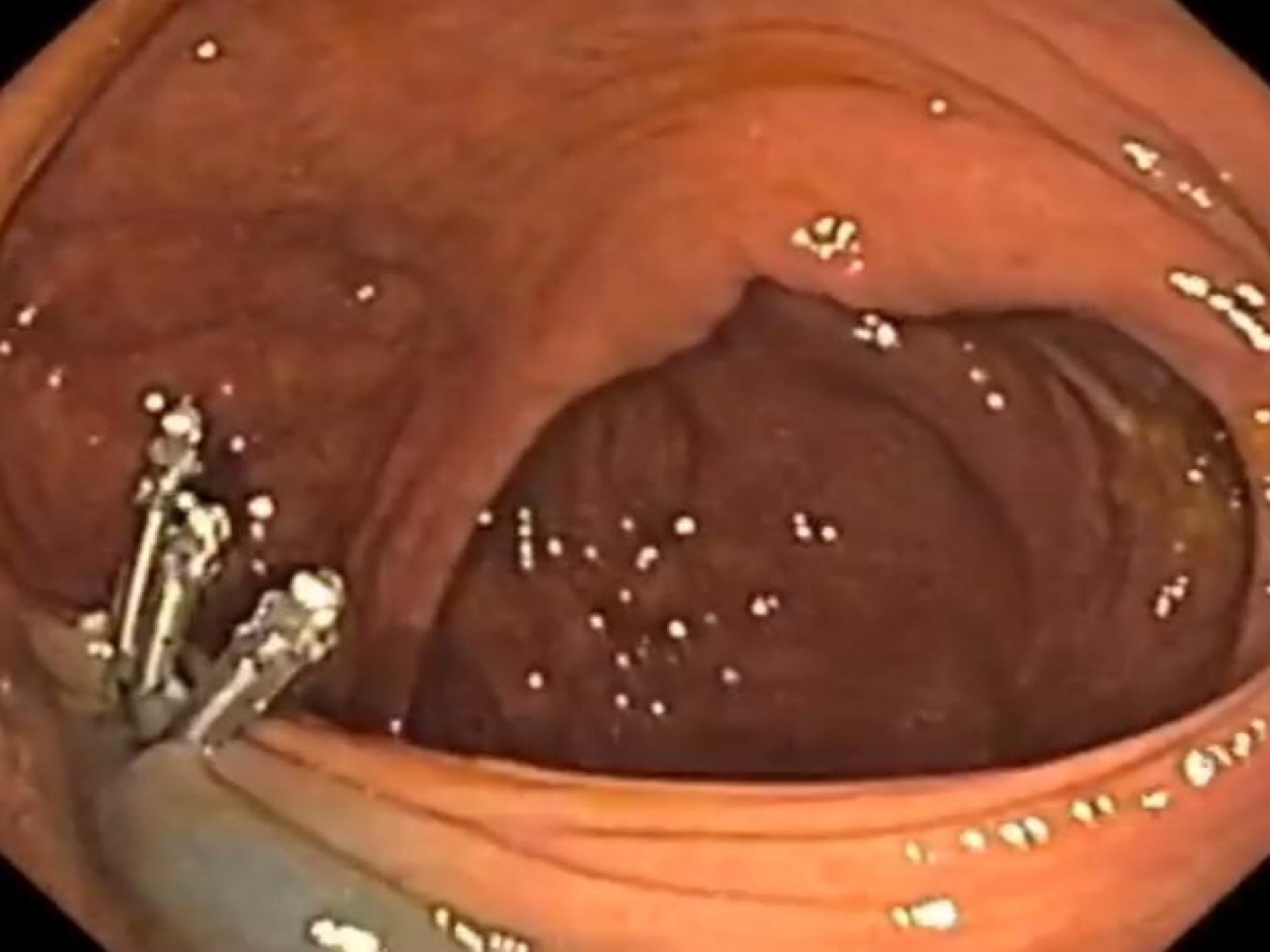


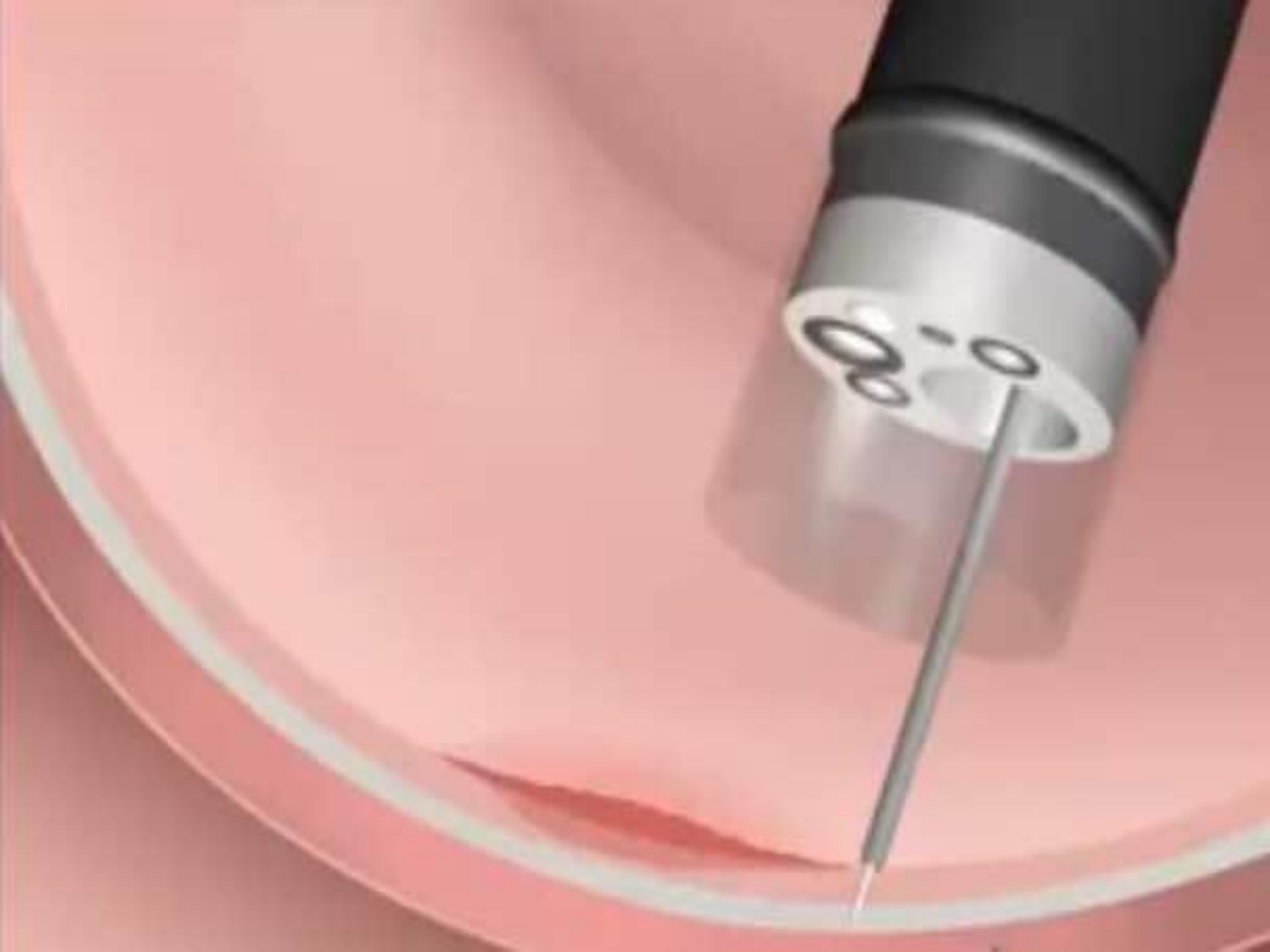
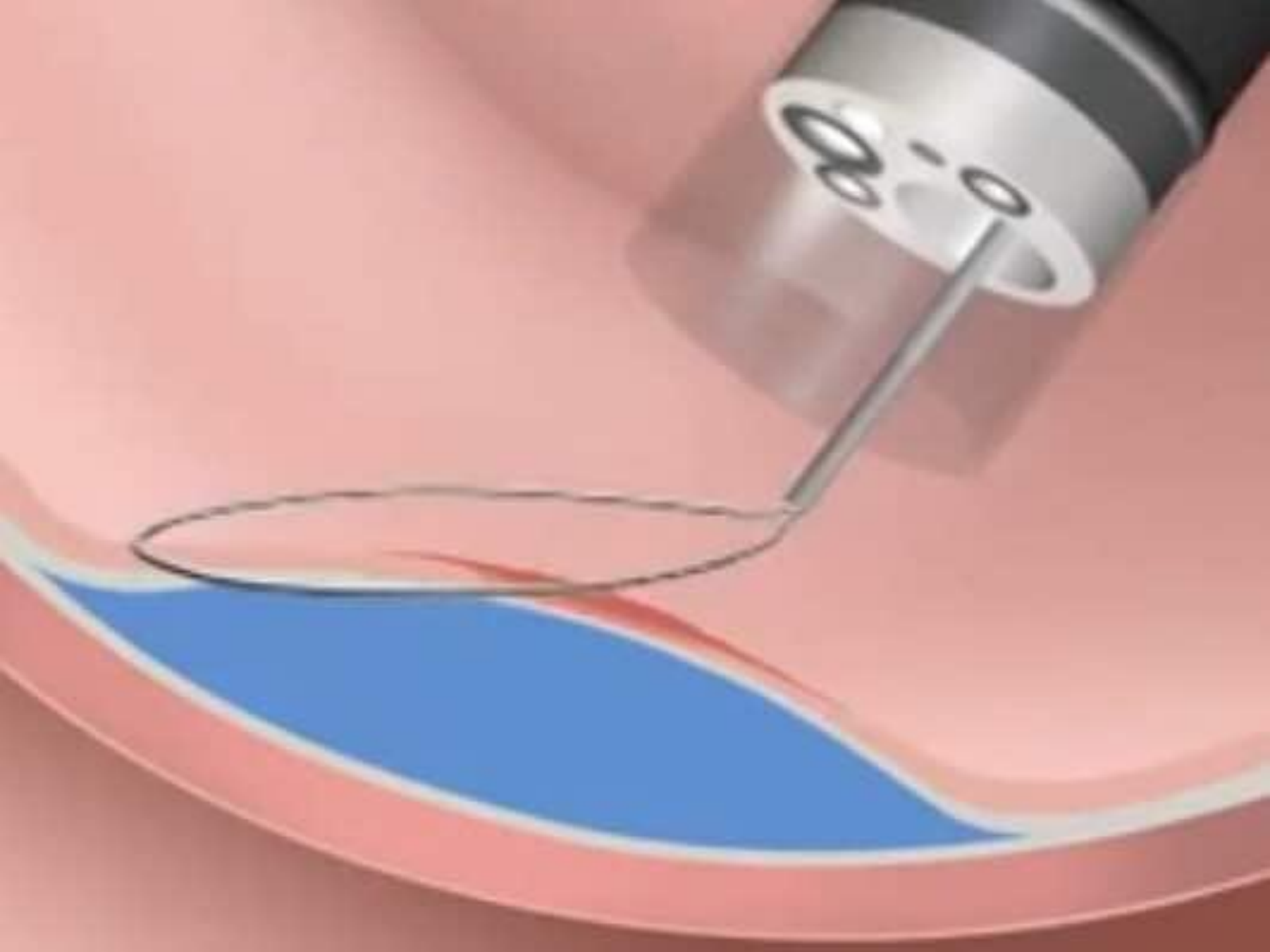


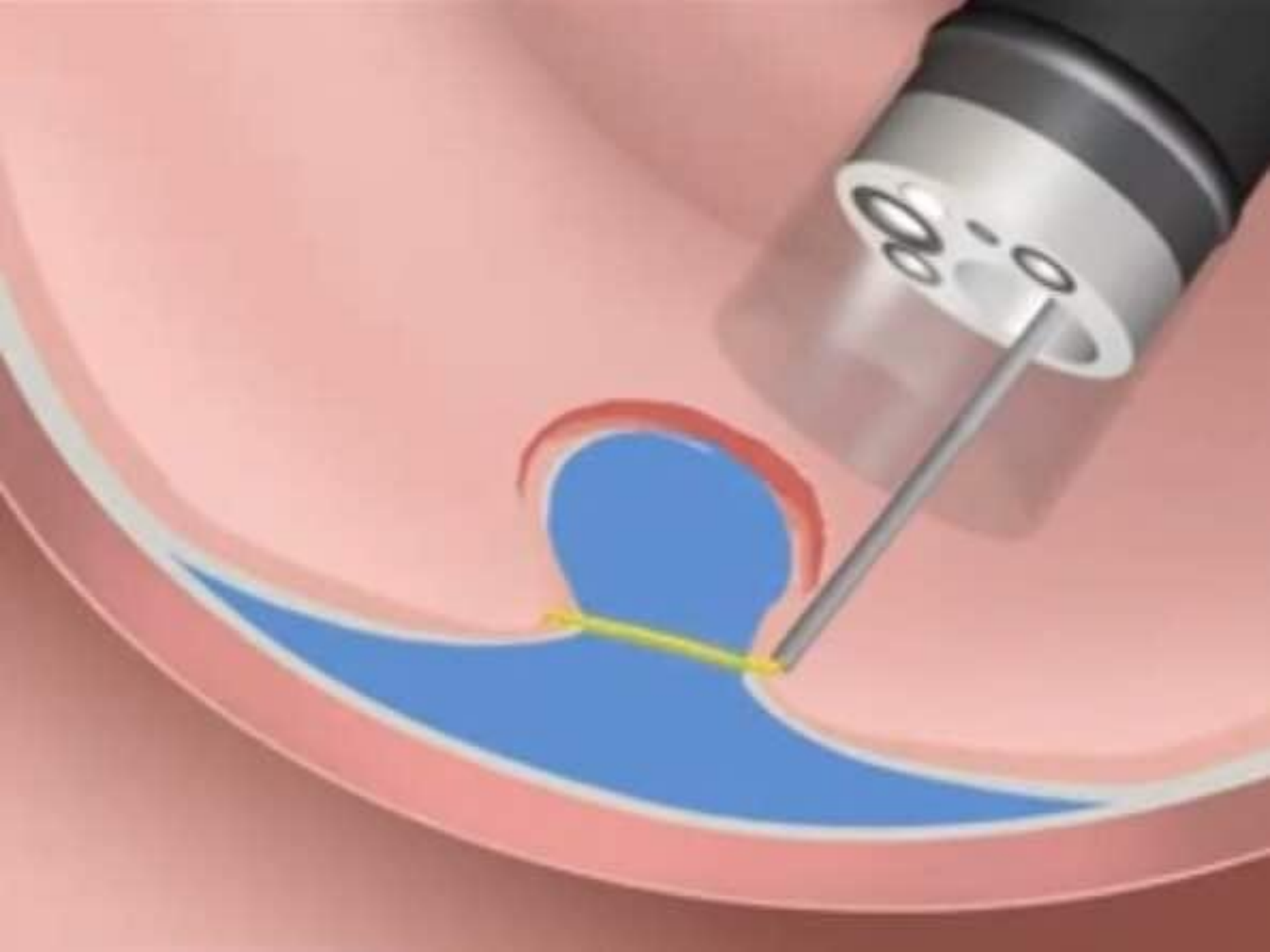
are resection

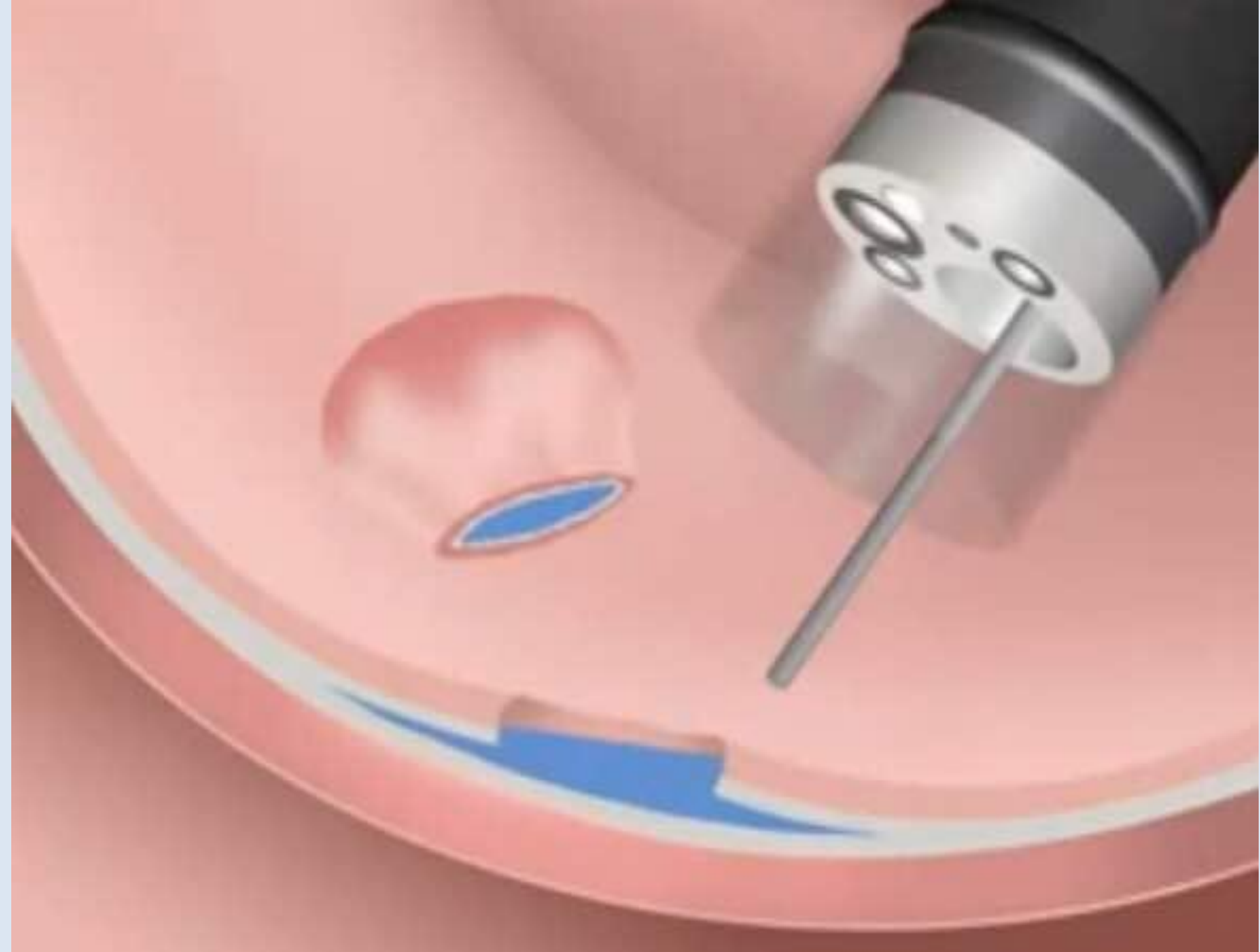













شكراً لأصغائكم

