



دور التقنيات التصويرية الحديثة في تشخيص أورام البنكرياس

Role of recent radiographic techniques in diagnosis of Pancreatic tumors

د. بشار المصري

Main radiologic techniques in Pancreas tumors

MSCT

MRI

EUS

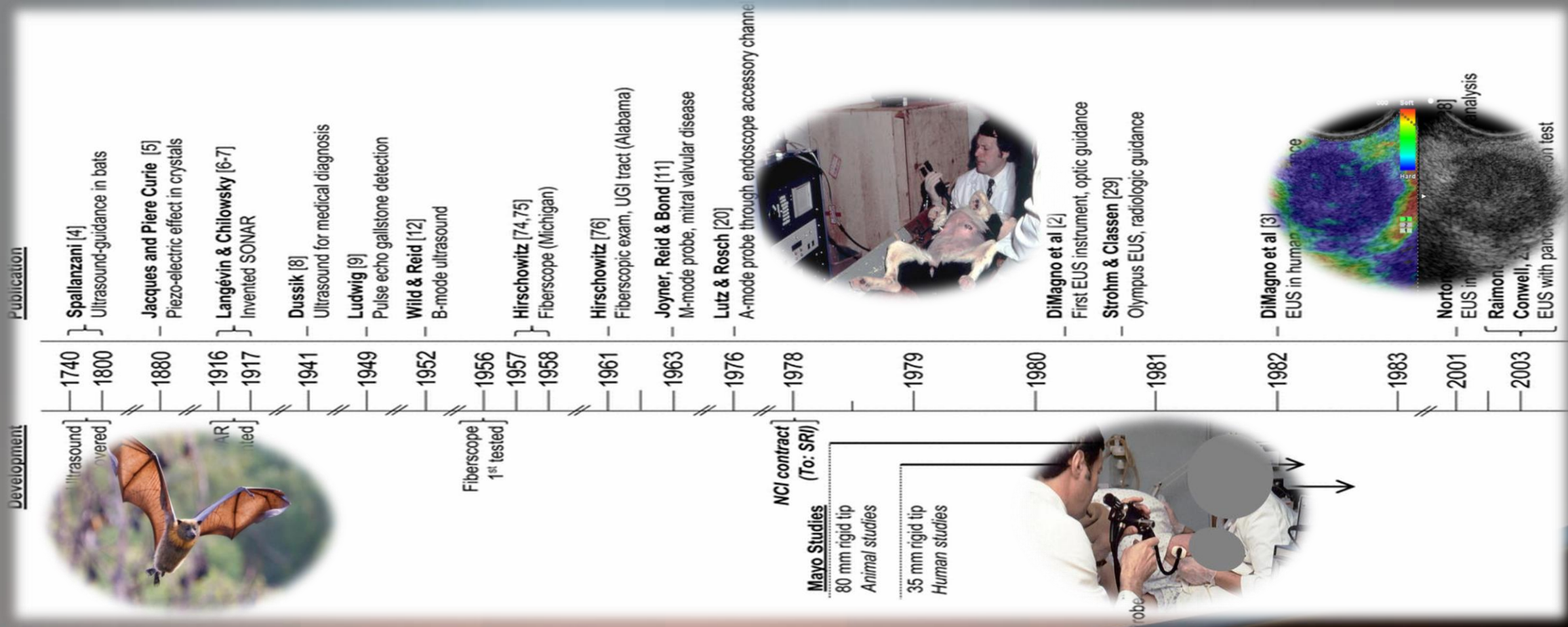
Main radiologic techniques in Pancreas tumors

MSCT

MRI

EUS

EUS .. Historical Overview



EUS in Pancreas tumors

Diagnosis

Staging

Other Functions

Treatment

EUS in Pancreas tumors

Diagnosis

Staging

Other Functions

Treatment

EUS in Pancreas tumors

Diagnosis

- *highly sensitive* for the detection of pancreatic tumors with rates higher than 90%
- for *lesions less than 2-3 cm* in size, it reaches a sensitivity rate of 99% vs 55% for CT and 93% for MDCT

EUS in Pancreas tumors

American Journal of Gastroenterology
© 2005 by Am. Coll. of Gastroenterology
Published by Blackwell Publishing

ISSN 0002-9270
doi: 10.1111/j.1572-0241.2005.00315.x

Negative Predictive Value of Endoscopic Ultrasound in a Large Series of Patients with a Clinical Suspicion of Pancreatic Cancer

Jason B. Klapman, M.D.,¹ Kenneth J. Chang, M.D.,² John G. Lee, M.D.,² and Phuong Nguyen, M.D.²

¹Division of Gastrointestinal Tumors, Section of Endoscopic Oncology, H. Lee Moffitt Center & Research

CONCLUSION: EUS is highly specific in the diagnosis of pancreatic cancer with a NPV of 100% and obviates the need for further diagnostic testing. In patients with a clinical suspicion of pancreatic cancer, EUS should be considered as the initial diagnostic modality.

(Am J Gastroenterol 2005;100:2658-2661)

patients included: weight loss/abdominal pain; and/or pancreatic enlargement/fulness on computed tomography (CT); and/or bile duct/pancreatic duct narrowing on endoscopic retrograde cholangiopancreatography; and/or an elevated CA 19-9. Follow-up information was obtained in 135/155 (87%) patients from patient phone calls and/or physician visits and/or CT scan. The mean follow-up period was 25 months (range 8-48 months).

RESULTS: No patients developed pancreatic cancer during the follow-up period. Following the EUS examination, no work-up was required in 119/135 (88%) of patients. CT scan was performed in 16 patients at 6 months postprocedure, none of which showed a pancreatic mass. The NPV of EUS in excluding pancreatic cancer in those patients with follow-up was 100%.

CONCLUSION: EUS is highly specific in the diagnosis of pancreatic cancer with a NPV of 100% and obviates the need for further diagnostic testing. In patients with a clinical suspicion of pancreatic cancer, EUS should be considered as the initial diagnostic modality.

(Am J Gastroenterol 2005;100:2658-2661)

EUS in Pancreas tumors

Diagnosis

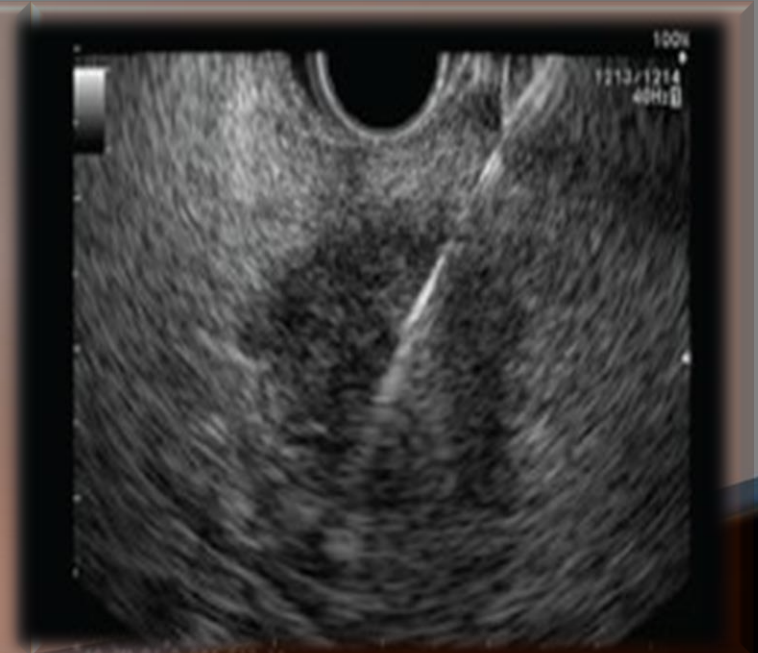Restrictions:

- *Chronic pancreatitis with a severe inhomogeneous echotexture*
- *Diffuse infiltration by tumor*
- *Prominent ventral/dorsal division*
- *Recent acute pancreatitis (less than 4 wk)*

EUS in Pancreas tumors

Diagnosis

- *EUS-FNA is one of the **most accurate** methods for diagnosis of inflammatory, cystic and neoplastic diseases of the pancreas*
- *EUS-FNA has a sensitivity and specificity of 95%, PPV of 100% and NPV of 85.2%*

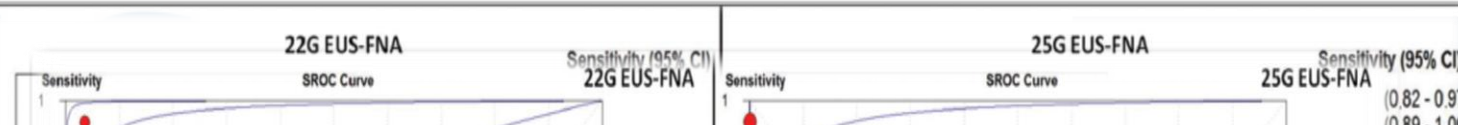


EUS in Pancreas tumors

Diagnosis


- *EUS-FNA with 25G vs. 22G or 19G needle ?*
- *EUS-FNA vs. EUS-FNB ?*

EUS in Pancreas tumors



ARTICLE

Our aim in this study was to compare the efficiency of 25G *versus* 22G needles in diagnosing solid pancreatic lesions by EUS-FNA. We performed a systematic review and meta-analysis. Studies were identified in five databases using an extensive search strategy. Only randomized trials comparing 22G and 25G needles were included. The results were analyzed by fixed and random effects. A total of 504 studies were found in the search, among which 4 randomized studies were selected for inclusion in the analysis. A total of 462 patients were evaluated (233: 25G needle/229: 22G needle). The diagnostic sensitivity was 93% for the 25G needle and 91% for the 22G needle. The specificity of the 25G needle was 87%, and that of the 22G needle was 83%. The positive likelihood ratio was 4.57 for the 25G needle and 4.26 for the 22G needle. The area under the sROC curve for the 25G needle was 0.9705, and it was 0.9795 for the 22G needle, with no statistically significant difference between them ($p=0.497$). Based on randomized studies, **this meta-analysis did not demonstrate a significant difference between the 22G and 25G needles used during EUS-FNA in the diagnosis of solid pancreatic lesions.**



Guedes HG, Moura DT, Duarte RB, Cordero MA, Santos ME, Cheng S, et al. A comparison of the efficiency of 22G *versus* 25G needles in EUS-FNA for solid pancreatic mass assessment: A systematic review and meta-analysis. Clinics. 2018;73:e261

EUS in Pancreas tumors

doi:10.1111/j.1440-1746.2008.05636.x

Conclusions: The 25-gauge FNA needle was significantly superior in terms of technical success rate and overall diagnostic accuracy, especially for the head and uncinate lesions, compared to the 22-gauge and Trucut needles and could be considered 'the best choice needle for cytological diagnosis' of solid pancreatic lesions. If histological diagnosis is required, the 22-gauge FNA needle and Trucut needle may be advantageous for use in head/uncinate and body/tail lesions, respectively.

*Division of Gastroenterology and Hepatology, Department of Internal Medicine, and Departments of [†]Pathology, [‡]Surgery, Kinki University School of Medicine, Osaka-Sayama, Japan; [§]Department of Gastroenterology, Sir Ganga Ram Hospital New Delhi, India; and [¶]Department of Gastroenterology, Aichi Cancer Center Hospital, Aichi, Japan

EUS in Pancreas tumors

Diagnosis

EUS-FNA Complications:

- *Bleeding 1-4%*
- *Acute pancreatitis 1-2%*
- *Perforation 0.03%*
- *Seeding (rare)*

EUS in Pancreas tumors

Diagnosis

Staging

Other Functions

Treatment

EUS in Pancreas tumors

Staging

- *EUS is better than MSCT in **T staging***
- *Most studies show no difference in N staging*
- *Vascular invasion evaluation (Sen 73%, Spe 90%)*
- *Overall **unresectability** evaluation (Sen 87%, Spe 80%)*

EUS in Pancreas tumors

Diagnosis

Staging

Other Functions

Treatment

EUS in Pancreas tumors

Other Functions

Contrast enhanced EUS

- *US contrast agent contains inert **gas bubbles***
- *When injected during exam, it differentiate pancreatic mass into hyper-, iso-, or hypo- enhancing mass*
- *applicable for patients with liver and renal dysfunctions*

EUS in Pancreas tumors

Other Functions

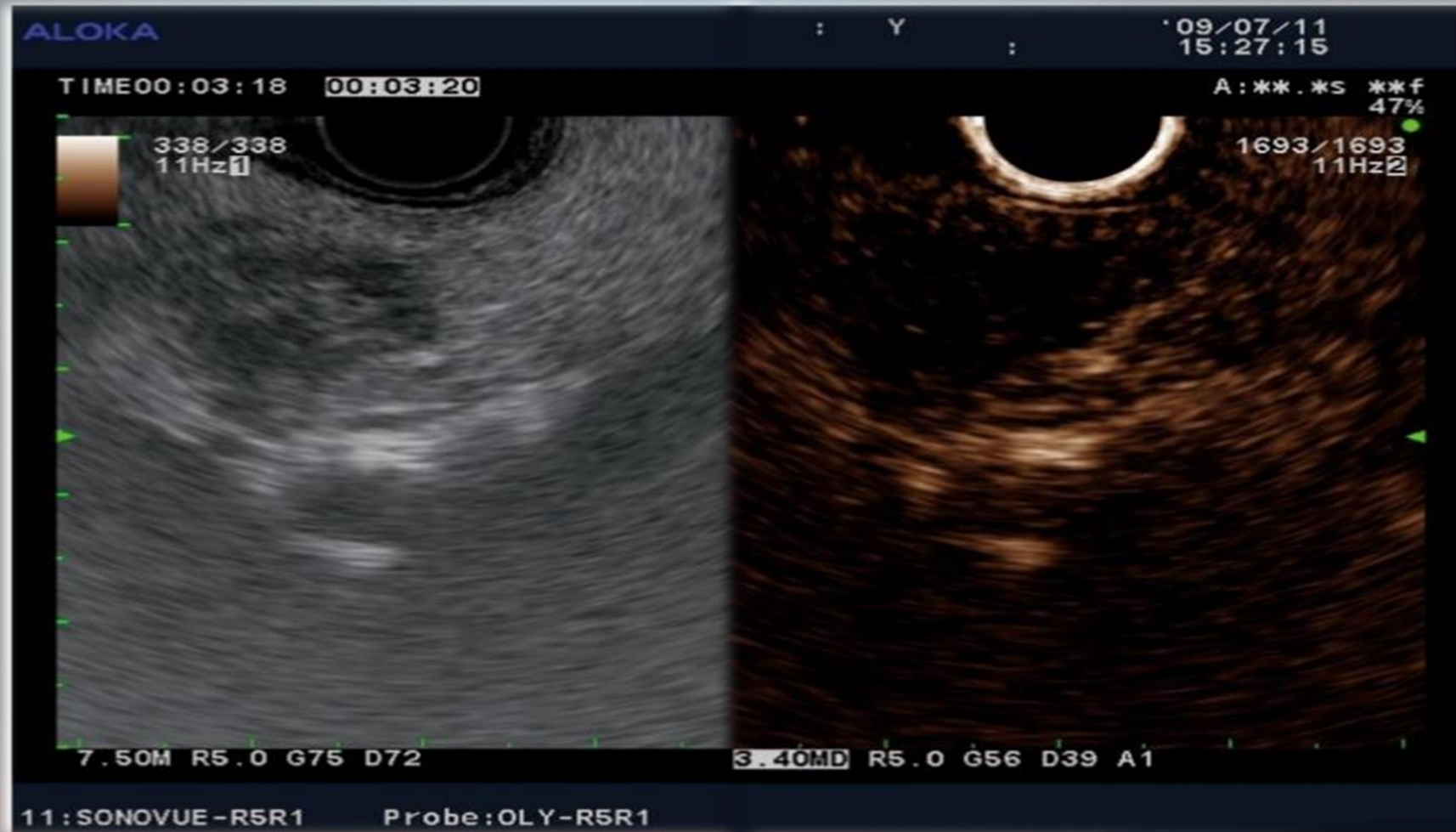
Contrast enhanced EUS

Hypo-enhancing mass → adenocarcinoma (Sen 82% & Spe 88%)

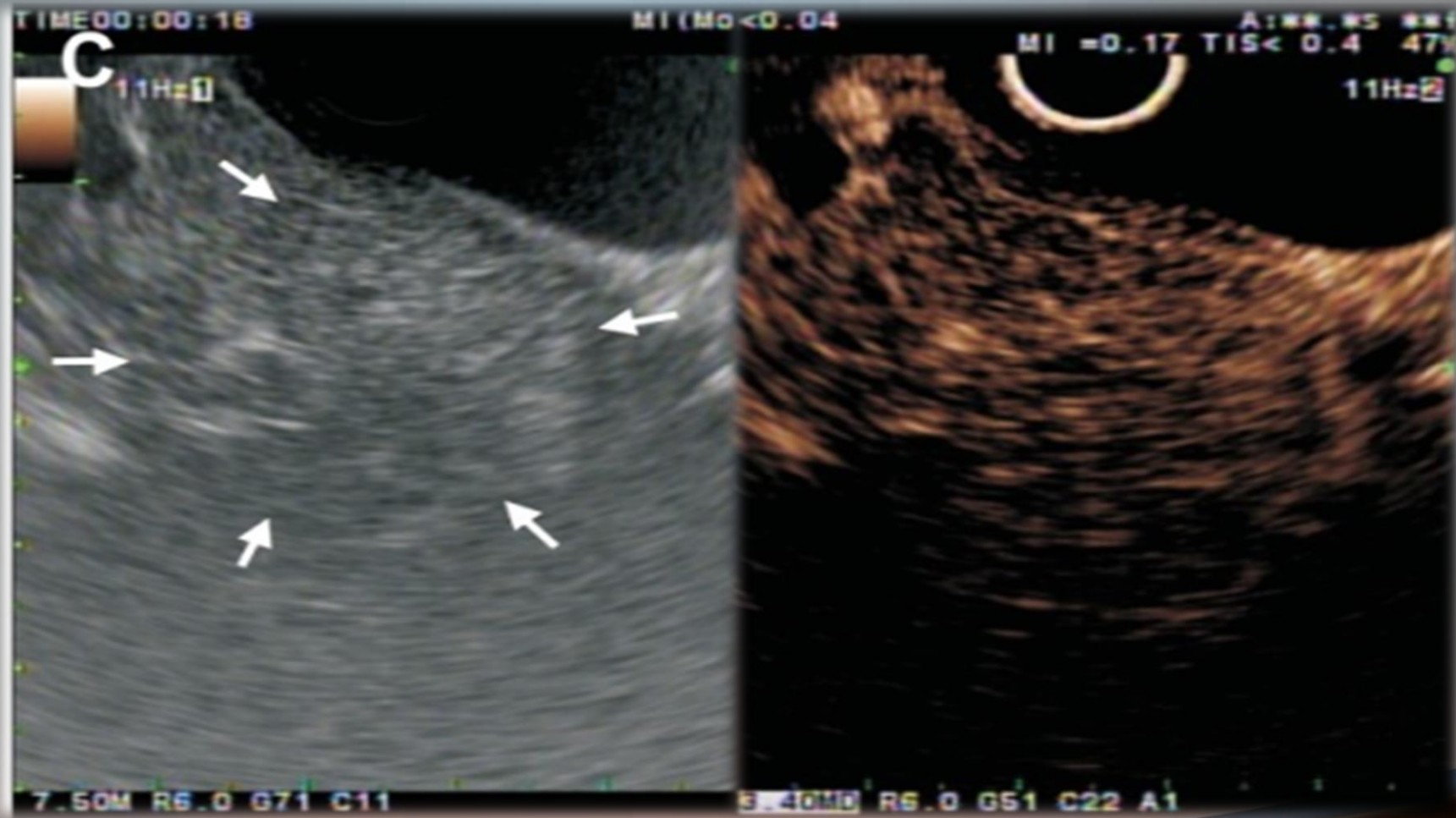
Hyper-enhancing mass → Neuroendocrine tumor (Sen 81% & Spe 91%)

Iso-enhancing mass → chronic or autoimmune mass forming pancreatitis

EUS in Pancreas tumors



EUS in Pancreas tumors



EUS in Pancreas tumors

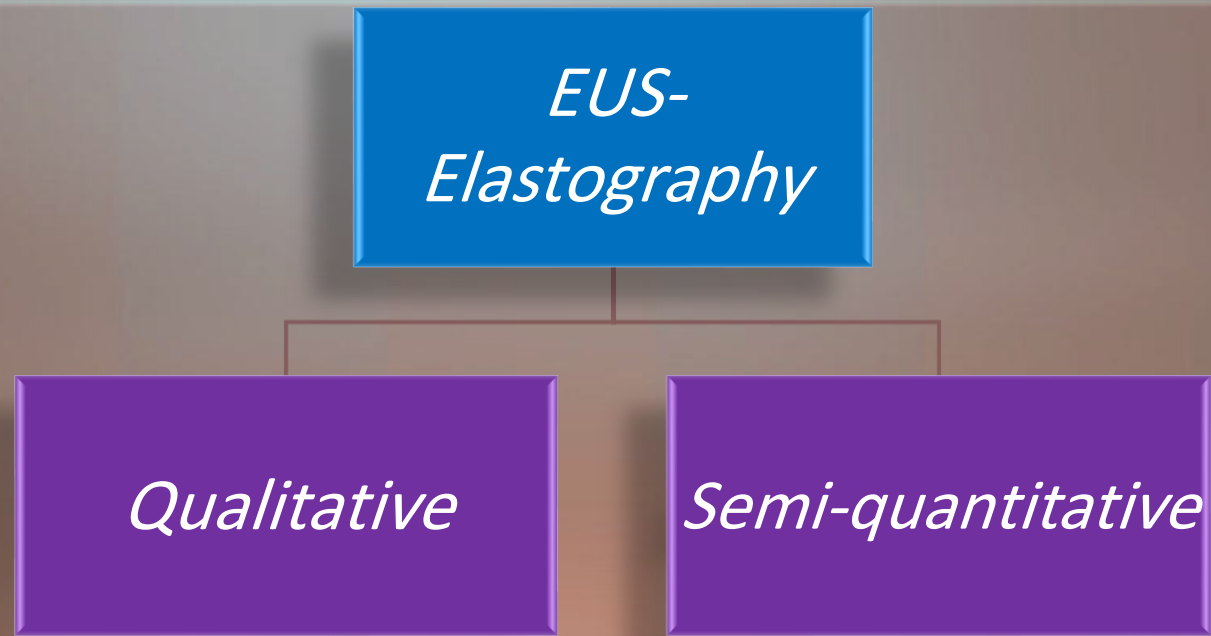
Other Functions

EUS-Elastography






- A ***virtual palpation technique*** that assesses the hardness of tissue by measuring its elasticity
- Compression of tissue by probe → strain (displacement of tissue) → colors correlate with hardness

EUS in Pancreas tumors

Other Functions

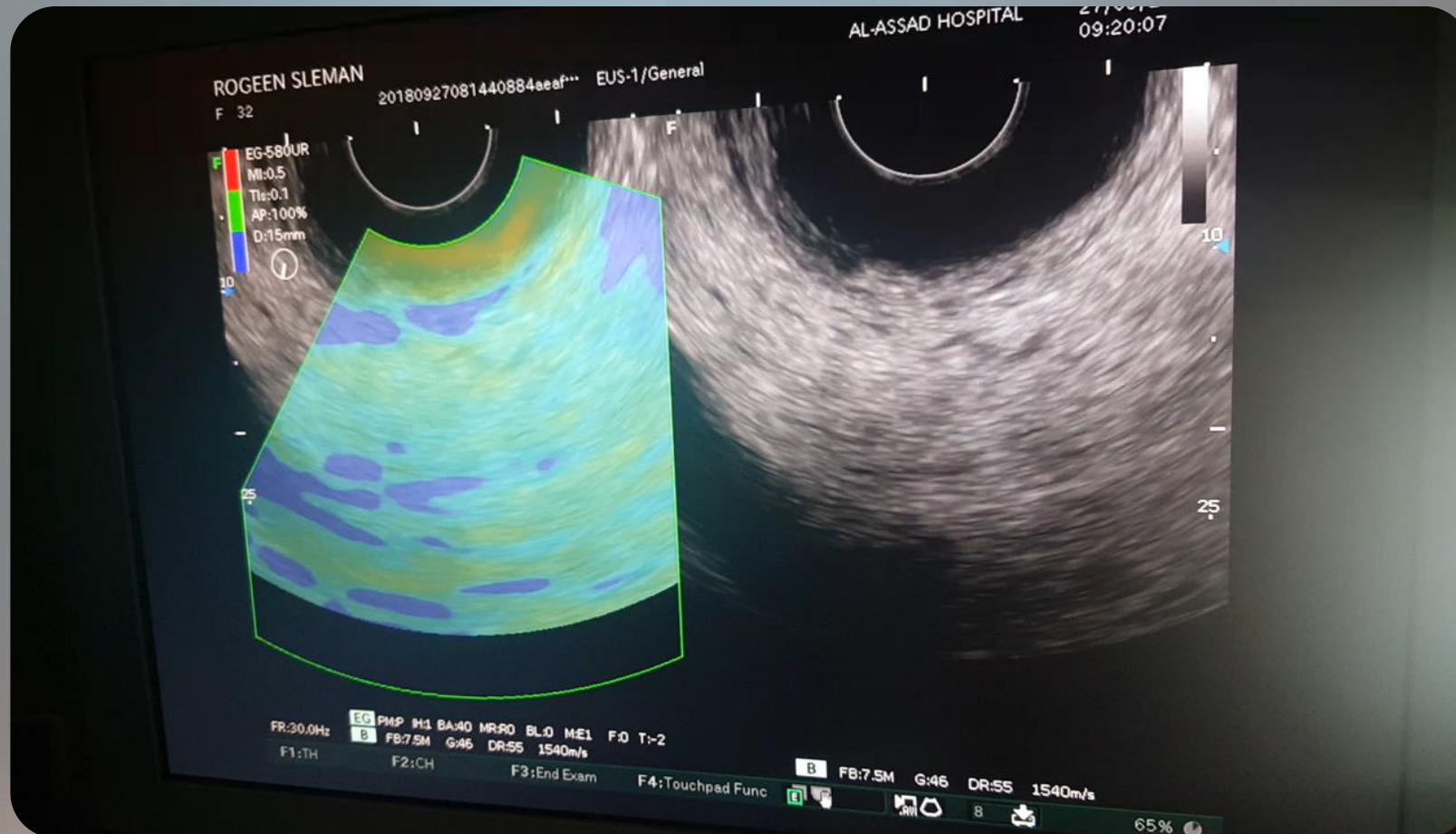


EUS in Pancreas tumors

<i>Score</i>	<i>Color type</i>		<i>Hardness</i>	<i>Tissue</i>
<i>1</i>	<i>Green</i>	Score 1 	<i>Homogeneously soft</i>	<i>Normal pancreas</i>
<i>2</i>	<i>Green, yellow and red</i>	Score 2 	<i>Heterogeneously soft</i>	<i>Fibrosis</i>
<i>3</i>	<i>Mostly blue with some heterogeneity</i>	Score 3 	<i>Hard</i>	<i>Early adenocarcinoma</i>
<i>4</i>	<i>Green hypoechoic central zone with blue surrounding</i>	Score 4 	<i>Hard</i>	<i>NET, Metastasis</i>
<i>5</i>	<i>Blue lesions with heterogeneity due to necrosis</i>	Score 5 	<i>Hard</i>	<i>Advanced Adenocarcinoma</i>

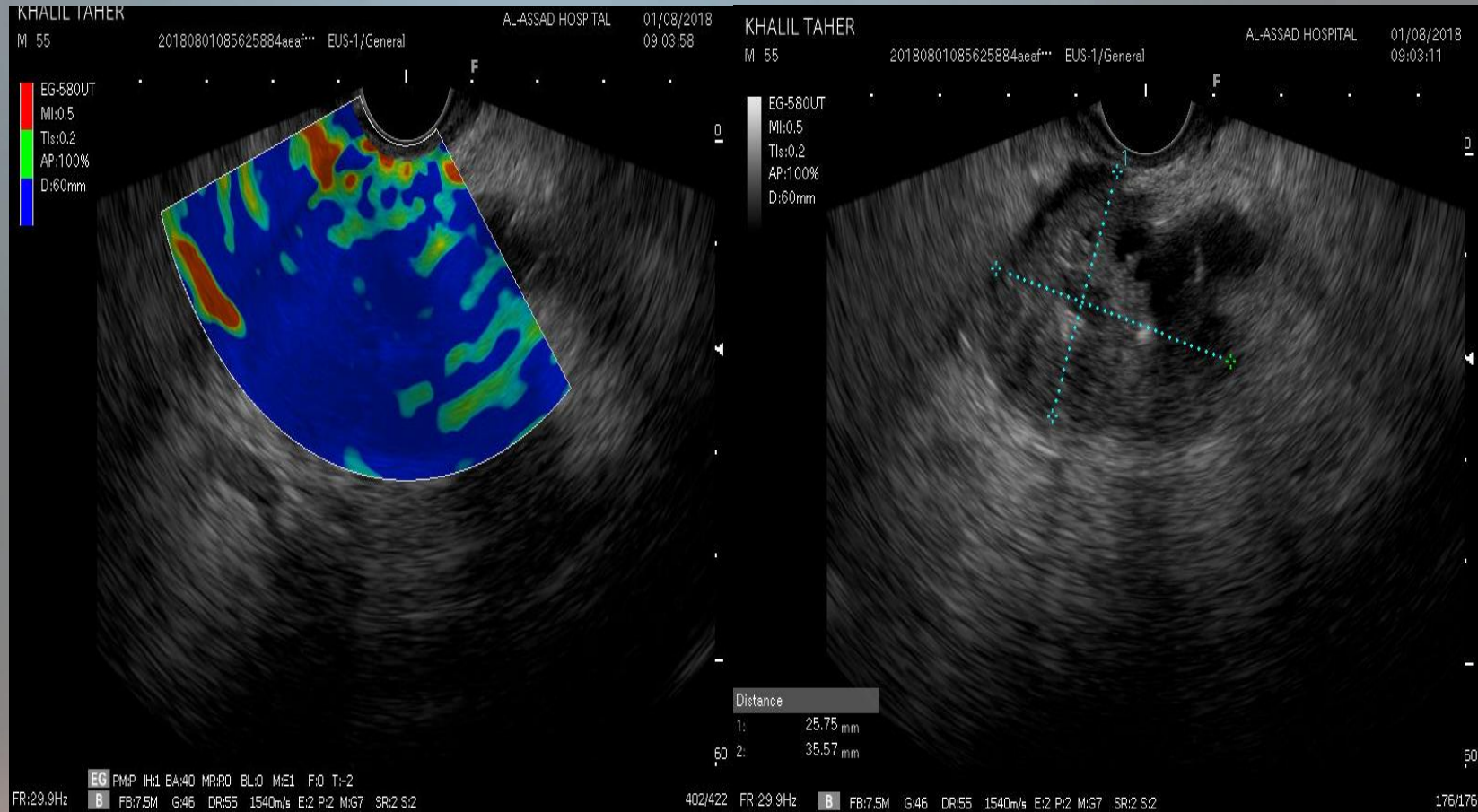
Five color score for EUS elastography in pancreas mass

EUS in Pancreas tumors



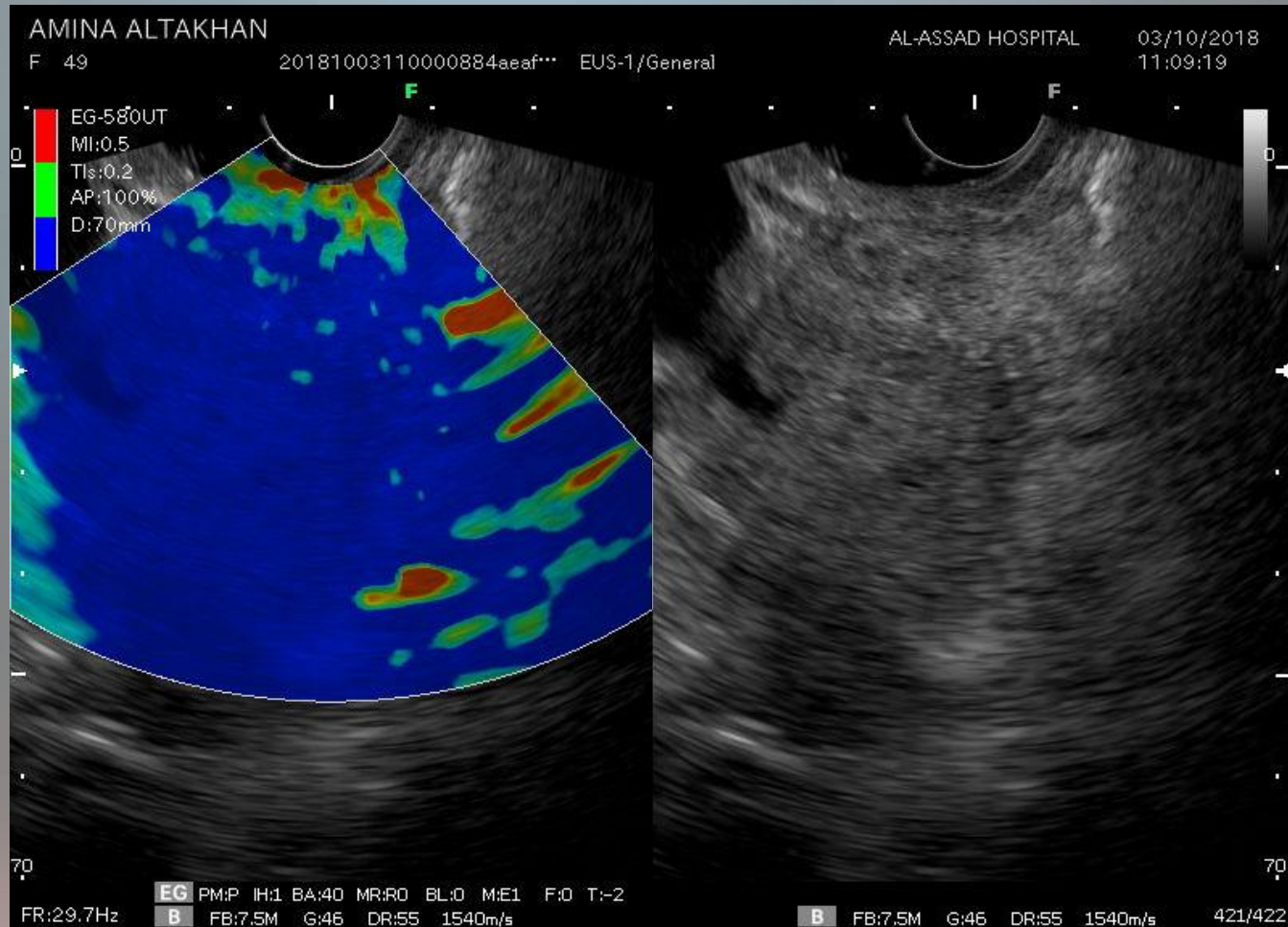
By kind permission of dr.Ayman Ali

EUS in Pancreas tumors



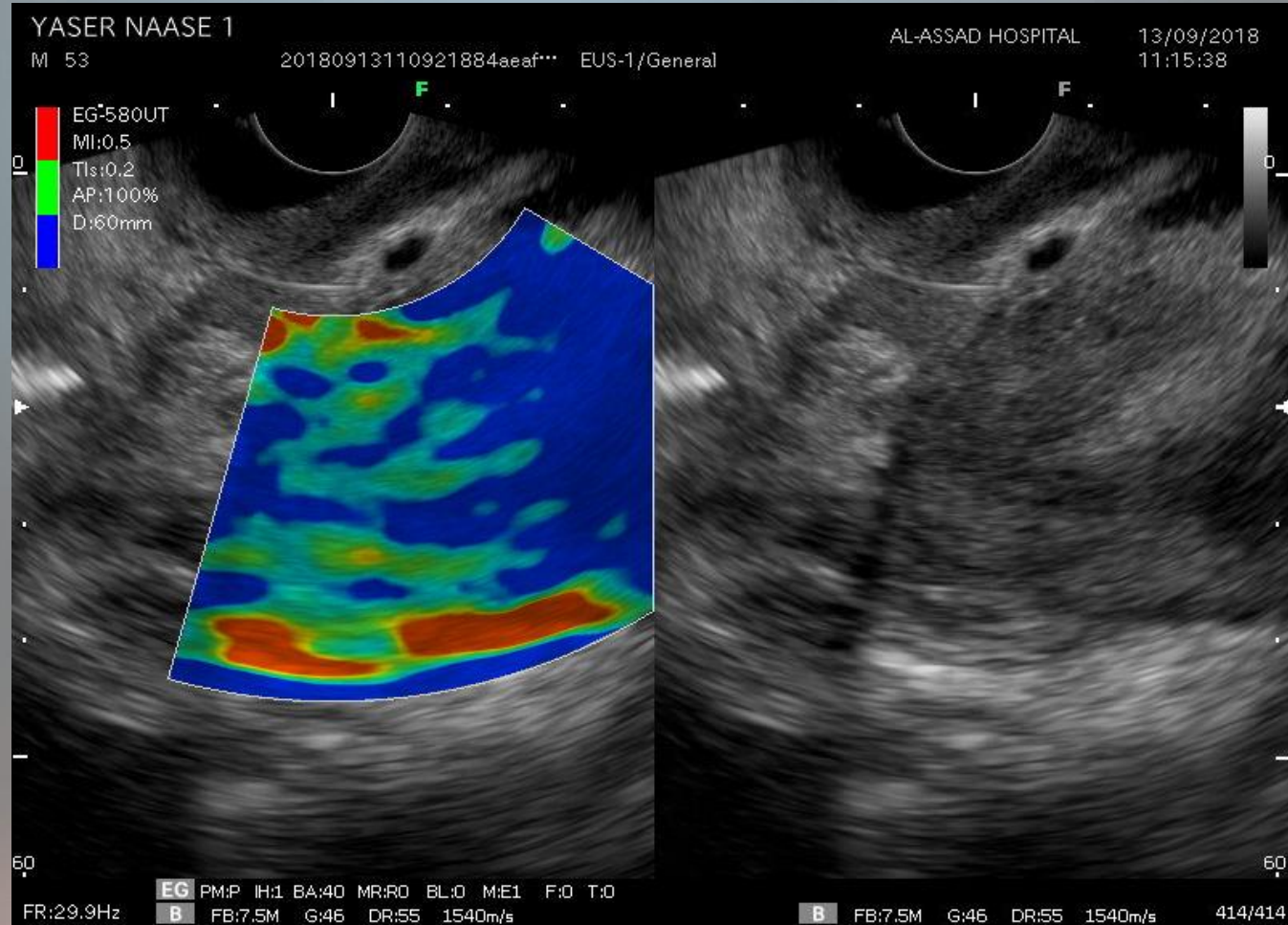By kind permission of dr.Ayman Ali

EUS in Pancreas tumors



By kind permission of dr.Ayman Ali

EUS in Pancreas tumors



By kind permission of dr.Ayman Ali

EUS in Pancreas tumors

Other Functions

*Semi-
quantitative
Elastography*

```
graph TD; A[Semi-quantitative Elastography] --> B[Strain histogram]; A --> C[Strain ratio];
```

Strain histogram

Strain ratio

EUS in Pancreas tumors

Online Submissions: wjg.wjgnet.com
wjg@wjgnet.com
doi:10.5748/wjg.15.1587



World J Gastroenterol 2009 April 7; 15(15): 1587-1592
World Journal of Gastroenterology 15(15): 1587-1592, 2009
© 2009 The WJG Press and Baishideng. All rights reserved.

BRIEF ARTICLE

Endoscopic ultrasound elastography for evaluation of lymph nodes and pancreatic masses: A multicenter study

Marc Giovannini,
Geneviève Monge,
Carl Szymanski,
Peter Vilmann, /

Marc Giovannini, T
Pesenti, Fabrice C
Paoli-Calmettes Inst
Geneviève Monge
Institute, Marseille
Paolo Arcidiaconi
and Gastrointestinal
Milan, 68052, Italy
Pierre Deprez, Re
University Hospital
Walter Schmidt, H
of Medicine I, Uni
Christoph Dietri
Caritas-Krankenhan
Pierre Eisendral
Devière, Divisio
B-1070 Anderlecht,
Peter Vilmann, /
Gastroenterology,
Hellerup, Denmark
Author contribu
Analyzed the data
and Caillol F pe
the patholo
anski C, I
included
Dept
ter

RESULTS: The sensitivity and specificity of EUS elastography to differentiate benign from malignant pancreatic lesions are 92.3% and 80.0%, respectively, compared to 92.3% and 68.9%, respectively, for the conventional B-mode images. The sensitivity and specificity of EUS elastography to differentiate benign from malignant lymph nodes was 91.8% and 82.5%, respectively, compared to 78.6% and 50.0%, respectively, for the B-mode images. The kappa coefficient was 0.785 for the pancreatic masses and 0.657 for the lymph nodes.

CONCLUSION: EUS elastography is superior compared to conventional B-mode imaging and appears to be able to distinguish benign from malignant pancreatic masses and lymph nodes with a high sensitivity, specificity and accuracy. It might be reserved as a second line examination to help characterise pancreatic masses after negative EUS-FNA and might increase the yield of EUS-FNA for lymph nodes.

EUS in Pancreas tumors

596 Original article

Accuracy of endoscopic ultrasound elastography used for differential diagnosis of focal pancreatic masses: a multicenter study

Authors

Institutions

submitted 2 August 2010
accepted after revision 21 December 2010

Bibliography

DOI <http://dx.doi.org/10.1055/s-0030-1256314>
Published online 24 March 2011
Endoscopy 2011; 43: 596–603 © Georg Thieme Verlag KG Stuttgart · New York
ISSN 0013-726X

Corresponding author

A. Siftala, MD, PhD
Research Center of Gastroenterology and Hepatology, University of Medicine and Pharmacy Craiova Romania
E-mail: sifalad@univ-craiova.ro

0.86 and 0.94. The average-hue histogram analysis of the data indicated a sensitivity of 93.4%, a specificity of 66.0%, a positive predictive value of 92.5%, a negative predictive value of 68.9%, and an overall accuracy of 85.4%, based on a cut-off value of 175. Area under the receiver operating characteristic curve (AUROC) was 0.854 ($P < 0.0001$) with a confidence interval of 0.804–0.894.

Conclusion: The value of quantitative analysis of EUS elastography recordings was proven by good reproducibility of the videos, as well as good parameters of the AUROC analysis. (ClinicalTrials.gov identifier: CT00909103).

EUS in Pancreas tumors

910 Original article

Indications and limitations of endoscopic ultrasound elastography for evaluation of focal pancreatic lesions

Authors

Institutions

submitted 25 June 2008
accepted after revision
22 September 2008

Bibliography

DOI 10.1055/s-2008-10777
Endoscopy 2008; 40:
910-917 © Georg Thieme
Verlag KG Stuttgart · New York
ISSN 0013-726X

Corresponding author

C. F. Dietrich, MD
Department of Internal
Medicine II
Caritas Hospital
Uhlandstr. 7
97980 Bad Mergentheim
Germany
Fax: +49-7931-582290
christoph.dietrich@ckbm.de

the lesion (i.e., malignant vs. benign). EUS-elastography predicted the nature of pancreatic lesions with poor diagnostic sensitivity (41%), specificity (53%), and accuracy (45%).

Conclusion: EUS-elastography of the pancreas has the potential to obtain some complementary information that would improve tissue characterization. Its clinical utility, however, remains questionable, and it seems unlikely that the information provided will obviate the necessity of obtaining tissue samples for confirmation of a final pathologic diagnosis.

EUS in Pancreas tumors

Other Functions

EUS-Elastography benefits

- *Differentiation between benign and malignant lesions*
- *Evaluation of lymph nodes*
- *May help in best FNA site determination*

EUS in Pancreas tumors

Other Functions

EUS-Elastography limitations

- *Control of tissue compression and **motion artifacts** is difficult*
- *Interposition of **cysts or dilated ducts** should be avoided*
- *NPV remains low (60%-70%)*
- ***Interobserver variability** is fair with unexperienced operators*

EUS in Pancreas tumors

Diagnosis

Staging

Other Functions

Treatment

EUS in Pancreas tumors

Treatment

- *celiac plexus neurolysis*
- *EUS-guided biliary drainage*
- *EUS-guided radiofrequency ablation*
- *EUS-FNI for intratumoral drug delivery*
- *EUS-guided radiation therapy*

EUS in Pancreas tumors

Treatment

- *celiac plexus neurolysis*
- ***EUS-guided biliary drainage***
- *EUS-guided radiofrequency ablation*
- *EUS-FNI for intratumoral drug delivery*
- *EUS-guided radiation therapy*

EUS in Pancreas tumors

Treatment

- *celiac plexus neurolysis*
- *EUS-guided biliary drainage*
- ***EUS-guided radiofrequency ablation***
- *EUS-FNI for intratumoral drug delivery*
- *EUS-guided radiation therapy*

EUS in Pancreas tumors

Treatment

- *celiac plexus neurolysis*
- *EUS-guided biliary drainage*
- *EUS-guided radiofrequency ablation*
- ***EUS-FNI for intratumoral drug delivery***
- *EUS-guided radiation therapy*

EUS in Pancreas tumors

Treatment

- *celiac plexus neurolysis*
- *EUS-guided biliary drainage*
- *EUS-guided radiofrequency ablation*
- *EUS-FNI for intratumoral drug delivery*
- *EUS-guided radiation therapy*

EUS in Pancreas tumors

Conclusion

- *EUS is highly sensitive in pancreas masses diagnosis*
- *EUS-FNA is an accurate and safe procedure*
- *CE-EUS and EUS-Elastography are useful ways in mass DDx*
- *EUS helps in treatment of pancreatic tumors*